

## Endodontic Management Of Radix Entomolaris – A Report Of Two Cases

**Bharadwaj B<sup>1\*</sup>, Arunajetasan Subbiya<sup>1</sup>, Alagarsamy Venkatesh<sup>1</sup>, Deepti J V<sup>1</sup> and Ajitha R<sup>2</sup>**

<sup>1</sup>Department of Conservative Dentistry and Endodontics, Sree Balaji Dental College and Hospital, Bharath Institute of Higher Education and Research (BIHER), Pallikaranai, Chennai, Tamil Nadu, India.

<sup>2</sup>Department of Pathology, Sree Balaji Medical College and Hospital, Bharath Institute of Higher Education and Research (BIHER), Chennai, Tamil Nadu, India

Email bharathwaj1212@gmail.com

---

### ABSTRACT

Usually first mandibular molars have one mesial and distal root but in some cases there are anatomical variations wherein the number of roots and root canals vary. Presence of an additional lingual root distally in mandibular molars is called radix entomolaris (RE). It is therefore very crucial to be familiar with variations in root canal anatomy and also its characteristic features as such knowledge helps in detection and negotiation of canals. Hence appropriate diagnosis is must before performing with root canal procedure in these teeth in order to ensure successful treatment outcome. This report describes the endodontic management of mandibular molar with radix entomolaris.

**Ke words :** Radix entomolaris, distolingual, anatomical variation, Endodontic management

---

### INTRODUCTION

The success of endodontic treatment basically depends upon the thorough knowledge of normal tooth anatomy and understanding the potential variations. Endodontic treatment aims at the eradication of bacteria from infected root canal and prevention of re-infection that is accomplished by thorough shaping and cleaning of the root canal followed by three dimensional filling with fluid tight seal. Hence, the failure of any endodontic treatment is either due to incomplete instrumentation, inadequate cleaning of root canal space, or flawed obturation in addition to the inability of the operator to be acquainted with the presence of extra roots, extra canals, isthmus etc.

Permanent mandibular molars are acknowledged to have anatomical variation. Mostly mandibular first molars have 2 roots with 3 canals with roots placed in mesial and distal side and the canals correspond to buccal and lingual aspect of mesial root and lingual aspect of distal root <sup>[1,2]</sup>. Major deviation in the mandibular first molar is the presence of third root.

This third root in mandibular first molar was first described by Carabelli as radix entomolaris (RE) <sup>[3]</sup>. It was characterized by the presence of extra root that is typically distributed lingually which is usually curved and smaller than disto-buccal root <sup>[4]</sup>. In cases where the additional root is found mesio-buccally to distal root, then molar is termed as radix paramolaris (RP) <sup>[5]</sup>. RE is found rarely in mandibular third molar, but not been reported less frequently in mandibular second molar <sup>[6]</sup>.

RE was reported that there was a significant difference in occurrence of RE in permanent mandibular molars when compared with race <sup>[6]</sup>. It is found to be less than 3% in African population, less than 4.2% in Caucasians, also less than 5% in Eurasian and Asian population, and about 5.97% in Indian population. It was found to be higher up to 40% in population with Mongolian traits like Eskimos, Native American population <sup>[7-9]</sup>.

Radiographic diagnosis plays a vital role for successful endodontic treatment of all canals as these radiographs if taken at different angulations can help the clinician to identify any abnormal or aberrant anatomy of a tooth. This again is a drawback when we use conventional radiography that gives two dimensional image of a three dimensional object <sup>[10]</sup>. Hence to overcome this, Cone beam computed tomography is employed as it a three dimensional imaging modality that can give images at different aspects which is referred to as multi-planar reconstruction <sup>[11]</sup>. This article discusses the case of RE provides an insight about the identification and modifications in management of the same.

### **Case Report 1**

A 28-year-old female patient reported to the hospital with severe throbbing constant pain in the mandibular right second molar for the past 2 weeks. The medical history of the patient was non-contributory. On clinical examination the tooth had a deep carious lesion and was severely tender on percussion. Preoperative parallel periapical radiograph revealed the presence of an extra root (Figure - 1A). Symptomatic irreversible pulpitis with apical periodontitis was established as a diagnosis based on patient's history and clinical examination. The buccal object rule (same-lingual opposite-buccal rule) confirmed the additional root as a mesiolingual root (radix entomolaris). Root canal treatment of the tooth was planned and patient consent was obtained. After administration of local anesthesia using 2%

lidocaine with 1:80,000 epinephrine and rubber dam isolation, access cavity preparation was performed. Four distinct root canal orifices were detected and negotiated up to #15 K file. The working length was determined by an apex locator and also confirmed by parallel periapical radiograph (Figure - 1B). After extirpation of pulp tissues, Gates Glidden drills were used to enlarge the root canal orifices with a brushing motion and then the canals were shaped with ProTaper Gold Nickel-titanium rotary instruments up to F2 apical size under copious irrigation with 2.5% sodium hypochlorite and lubrication with EDTA (RC-Prep). Once the canals were dried with paper points, master gutta percha points were fitted within the canals and a confirmation radiograph was taken (Figure - 1C). The root canal system was obturated with cold lateral compaction of gutta- percha and AH plus sealer (Figure - 1D). The access cavity was filled with IRM and the patient was recalled after a week for full coverage crown.

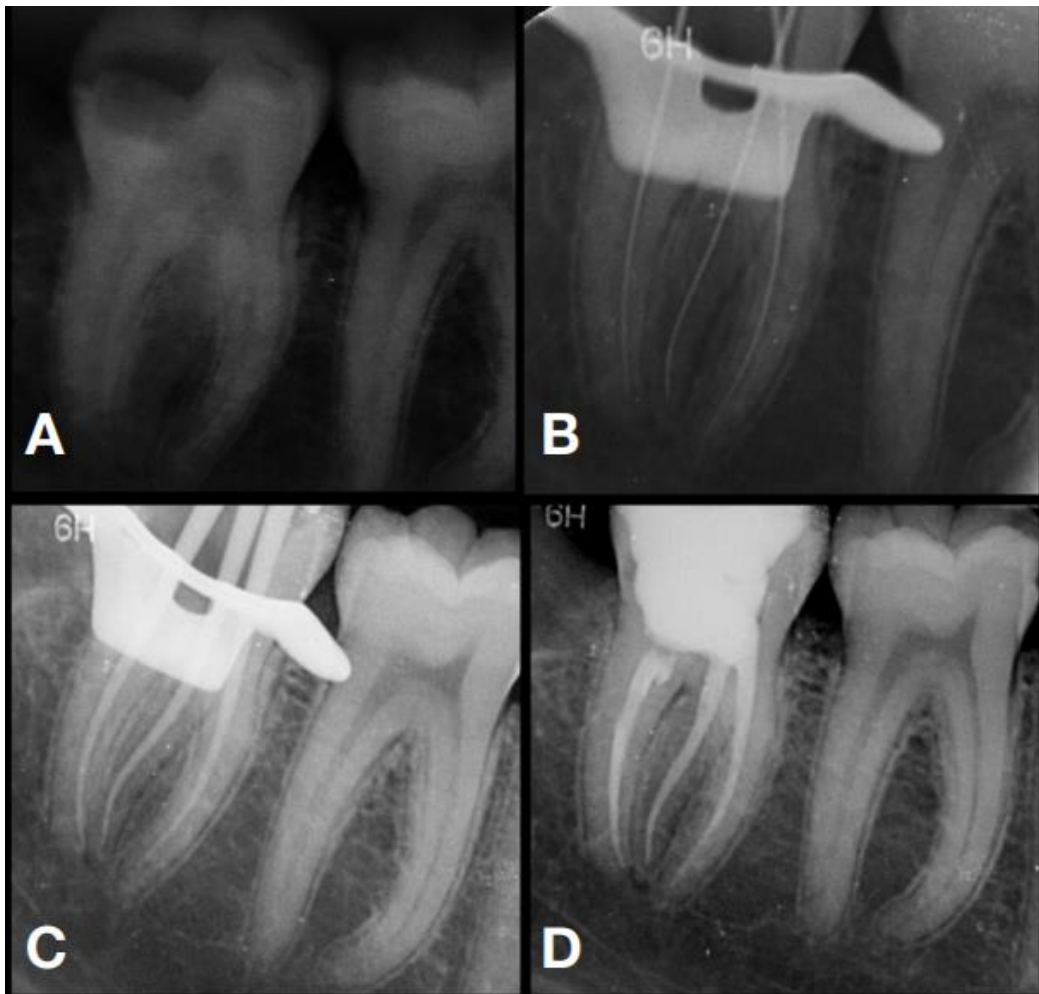


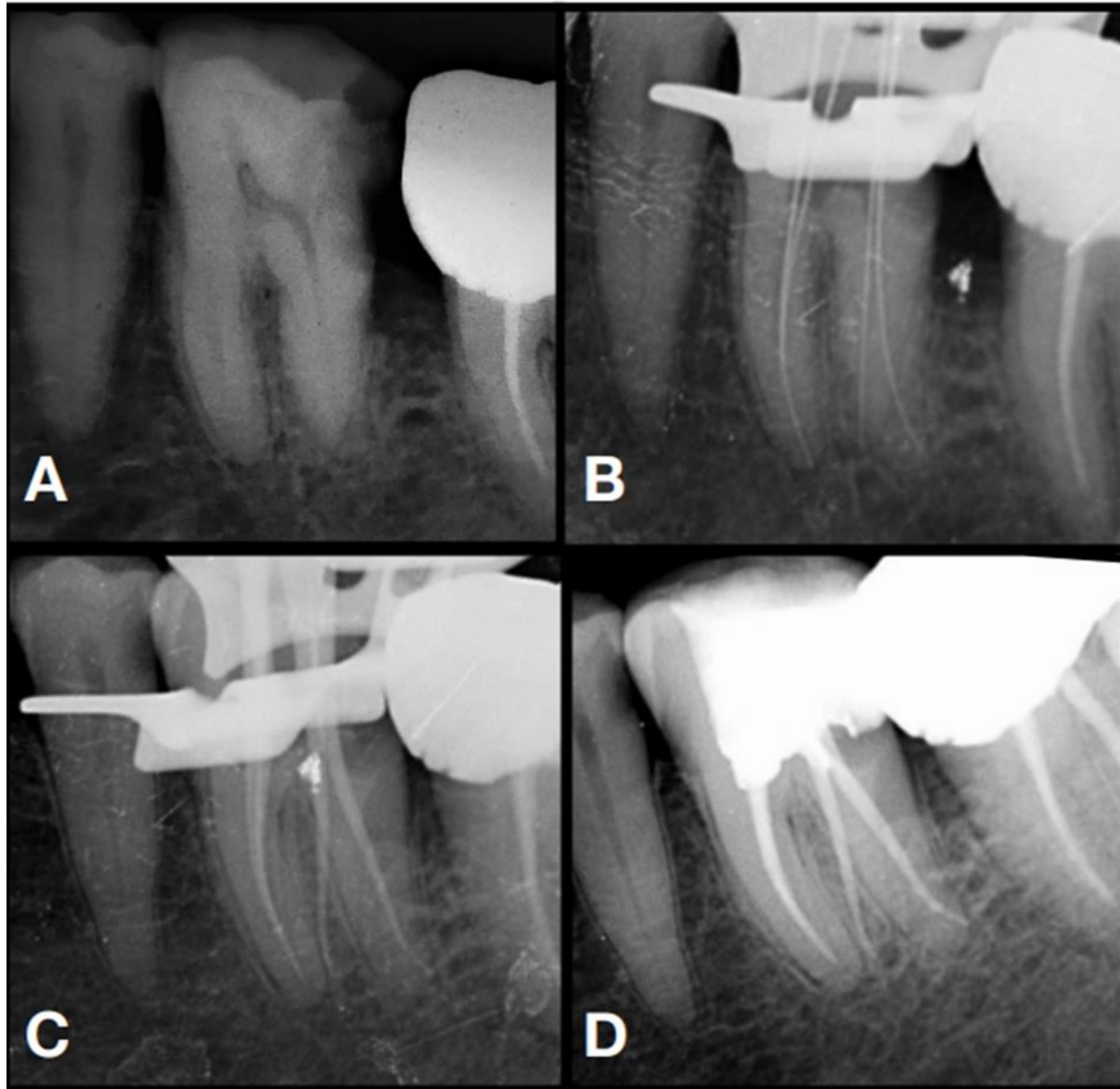
Figure 1.A - Preoperative radiograph , B - Working Length , C - Master cone, D- Obturation

## Case Report 2

A 69-year-old male patient reported to the hospital with a history of pain in the lower left back tooth for 1 month. On clinical examination, left mandibular first molar was found to be carious and there was pain on percussion. Preoperative radiographic showed radiolucency involving pulp but did not reveal the presence of the third root (Figure - 2A). The diagnosis was established as symptomatic irreversible pulpitis with apical periodontitis.

Root canal treatment of the tooth was planned and patient consent was obtained. Access cavity preparation was done after administration of local anesthesia and rubber dam isolation. The root canal orifices were negotiated using DG-16 explorer. Mesial canals were completely calcified till middle third of the root canal. Hence an #8 k file was used to negotiate with copious irrigation of 2.5% sodium hypochlorite and EDTA followed by #10 and #15 k files. Two distal canals were located and the second distolingual canal orifice was negotiated more lingually, away from the rest of the three orifices. Hence #15 k files were placed in canals up to the working length with apex locator as an aid and radiograph was taken (Figure - 2B). The radiograph indicated the presence of an additional root which is radix entomolaris. Cleaning and shaping of the root canal system were done with rotary ProTaper gold file system with apical preparation till F2. After root canal preparation, temporary restoration was placed and the patient was recalled after 3 days.

Patient was asymptomatic at the next appointment. Master cone radiograph was taken (Figure - 2C), canals were dried with absorbent paper points and obturation was done by cold lateral compaction with gutta-percha cones and AH Plus sealer (Figure - 2D).



A - Preoperative radiograph , B - Working Length , C - Master cone, D- Obturation

## DISCUSSION

RE and RP occurs may be seen most commonly in the first, second, and third mandibular molar and the bilateral occurrence varies from 50 to 67% <sup>[5]</sup>. Etiology of RE and RP are still unclear as it was suggested that it occurs due to external factors altering the tooth formation during odontogenesis or can be due to pronounced expression of particular gene in various races <sup>[12]</sup>.

Various classifications has been proposed for categorizing RE based on the location of its cervical part, curvature of root canal, and the length. Based on the location of its cervical part, RE is classified into 4 types <sup>[13]</sup> and each type has a sub classification to identify RE as separate or non-separate.

- a) Type A: Location of RE is lingual to distal root complex and has two cone-shaped macrostructure.
- b) Type B: Location of RE is lingual to distal root complex and has one cone-shaped macrostructure.
- c) Type C: Location of RE is lingual to mesial root complex.
- d) Type AC: Location of RE between mesial and distal root complexes.

De Moor et al <sup>[10]</sup> described the curvature of the root or root canal based on the work of Ribero et al <sup>[14]</sup> into 3 types as

- 1) Type I: Straight root or root canal.
- 2) Type II: Curved coronal third which becomes straighter in the middle and apical third.
- 3) Type III: Initial curve in the coronal third with a second buccally oriented curve that begins in middle or apical third.

Song et al <sup>[15]</sup> added two more newly defined variants

1. Small type: Length short than half of the length of disto-buccal root.
2. Conical type: Smaller than small type with no root canal within it.

It has been suggested that endodontic treatment of mandibular first molar had a significantly lower success rate than other teeth due to persistent infection resident in missed canal and also the incapability of the clinician to remove all the pulp remnants along with microorganisms in the root canal system <sup>[16]</sup>. This highlights the fact that awareness about the root canal anatomy and practical skill is essential to improve the healing rate.

Preoperative radiographs help us to determine the third root in 90% of the cases <sup>[17]</sup>. RE can be seen as double periodontal ligament images or unclear view of distal canal/root indicating the possibility of its presence <sup>[16]</sup>. Hence additional exposure from different horizontal projection that is 20 degrees from either mesial or distal reveals basic information regarding anatomy of the tooth <sup>[5, 18]</sup>. Case report 1 showed type C radix entomolaris and case report 1 showed type B radix entomolaris. However, further

investigations like cone beam computed tomography can be used to study the morphology of RE in 3 dimensional reconstruction.

After establishing the diagnosis, access cavity should be prepared in a way to maintain the “straight line” access. A modified classical triangular access cavity in the form of trapezoidal shape helps in locating and accessing root canal in cases of RE <sup>[19]</sup>. Law of orifice location can help in locating the extra orifice. Care must be taken to avoid gauging or excessive removal of dentin that weakens the tooth structure.

Using a pre curved file with smooth glide path to the apical segment is the desired option for RE<sup>[20]</sup>. Adequate coronal enlargement allows easy passage of files and also the root canal irrigants to pass to the apical region in larger volumes thereby facilitating the removal of debris and microorganisms in some of the inaccessible areas.

## **CONCLUSION**

RE cases require careful judicial application of both diagnostic and endodontic skills for management and it is crucial to ascertain its nature to provide a proper treatment to the patient. Radiographs with different angulation for conventional type and advance imaging technique CBCT facilitates the identification of RE before initializing the treatment.

## **REFERENCES:**

1. F. J. Vertucci, “Root canal anatomy of the human permanent teeth,” *Oral Surgery Oral Medicine and Oral Pathology*, vol. 58, no. 5, pp. 589–599, 1984.
2. Subbiya A, Kumar KS, Vivekanandhan P, Prakash V. Management of mandibular first molar with four canals in mesial root. *Journal of conservative dentistry* 2013 Sep;16(5):471.
3. G. Carabelli, *Systematisches Handbuch Der Zahnheilkunde*, Braumuller und Seidel, Vienna, Austria, 2 edition, 1844.
4. Segura-Egea JJ, Jimenez-Pinzon A, Rios-Santos JV. Endodontic therapy in a 3-rooted mandibular first molar: Importance of a thorough radiographic examination. *J Can Dent Assoc* 2002; 68(9): 541-4.
5. Calberson FL, De Moor RJ, Deroose CA. The Radix Entomolaris and Paramolaris: Clinical Approach in Endodontics. *J Endod* 2007; 33(1):58- 63.
6. Tu MG, Huang HL, Hsue SS, Hsu JT, Chen SY, Jou MJ, et al. Detection of permanent three-rooted mandibular first molar by cone-beam computed tomography imaging in Taiwanese individuals. *J Endod* 2009; 35: 503–7.

7. E. K. Tratman. Three-rooted lower molars in man and their racial distribution. *British Dental Journal* 1938; 64: 264–274.
8. M. E. Curzon, J. A. Curzon. Three-rooted mandibular molars in the Keewatin Eskimo. *Journal of the Canadian Dental Association* 1971; 37( 2): 71–72.
9. S. C. Yew, K. Chan. A retrospective study of endodontically treated mandibular first molars in a Chinese population. *Journal of Endodontics* 1993; 19(9): 471–473.
10. R. J. G. De Moor, C. A. J. G. Deroose, F. L. G. Calberson. The radix entomolaris in mandibular first molars: an endodontic challenge. *International Endodontic Journal* 2004;37(11): 789–799.
11. V. Gopikrishna, J. Reuben, D. Kandaswamy. Endodontic management of a maxillary first molar with two palatal root and a single fused buccal root diagnosed with spiral computed tomography—a case report. *Oral Surgery, Oral Medicine, Oral Pathology, Oral Radiology and Endodontology*. 2008; 105 (4): e74–e78.
12. Davini F, Cunha RS, Fontana CE, Silveira CF, Bueno CE. Radix entomolaris – A case report. *RSBO* 2012; 9(3):340-344.
13. Sarangi P, Uppin VM. Mandibular first molar with a radix entomolaris: An endodontic dilemma. *J Dent (Tehran)* 2014;11:118-22.
14. F. C. Ribeiro, A. Consolaro. Importancia clinica y antropologica de la raiz distolingual en los molares inferiores permanentes. *Endodoncia* 1997 ; 15 : 72–78.
15. Shiraguppi V., Deosarkar B, Das M., Gadge P. , Parakh S. Endodontic management of radix entomolaris – Two case reports. *Journal of Interdisciplinary Dental Sciences*, July-Dec 2020;9(2):01-05.
16. Chen YC, Lee YY, Pai SF, Yang SF. The morphologic characteristics of distolingual roots of mandibular first molars in Taiwanese population. *J Endod* 2009; 35: 643–5.
17. Walker RT, Quackenbush LE. Three-rooted lower first permanent molars in hong kong Chinese. *Br Dent J* 1985; 9: 298-99.
18. J. I. Ingle, G. S. Heithersay, and G. R. Hatwell, *Endodontic Diagnostic Procedures*, BC Decker, London, UK, 2002.
19. P. Krasner, H. J. Rankow. Anatomy of the pulp-chamber floor. *Journal of Endodontics* 2004; 30(1): 5–16.
20. Subbiya A, Sophreniaa W, Tamilselvi R, Mary NS. Radix: the third Root In Mandibular Molars--A Case Series. *Indian Journal of Public Health Research & Development*. 2019 Nov 1;10(11):3075-9.