

# Antifertility effect of *Dactylorhiza hatagirea* (D. Don) Soo. root extract using Cyclophosphamide induced male albino rats

G Raju <sup>1\*</sup>, Rajitha V<sup>2</sup>

<sup>1</sup>Assistant Professor, Department of Anatomy, Sree Gokulam Medical College & Research Foundation, Thiruvananthapuram, Kerala, India and Research Scholar, Vinayaka Mission's Research Foundation (Deemed to be University), Salem, Tamilnadu, India

<sup>2</sup>Assistant Professor, Department of Anatomy, Vinayaka Mission's Kirupananda Variyaar Medical College, Vinayaka Mission's Research Foundation (Deemed to be University), Salem, Tamilnadu, India.

\*Corresponding author. Email: rajugangadharakurup@gmail.com

---

## Abstract

*Dactylorhiza hatagirea* is a curative orchid variety, which is used to manage a sum total of disorganization with disease. The constituents have aphrodisiac nature along with further good being neuro stimulant, antibacterial, immunomodulator, than numerous healthful effects. The current research was carried out to look over the histopathological outcome of *D. hatagirea* on reproductive toxicity effect by CycloPhosphamide (CP) in male albino rats. In sub-chronic toxicity studies, the ethanolic extract of *D. hatagirea* were prepared and present exploratory animals exist cleave among six categories (G1 to G6). Present study, G1 was examined as control; G2 and G3 was specified CP by varying doses and G4 and G5 were given ethanolic extract and G6 was administered with ethanolic extract and CP. At the end of experiments, the testes were detached and stained for histological examinations. The results of the study revealed prominent histopathological alterations with the degeneration of numerous dispersed seminiferous tubules and appearance of uneven basement membrane

**Keywords:** Cyclophosphamide, *Dactylorhiza hatagirea*, Ethanolic extract, Testes

## Introduction

Sterility is a disturbing worldwide well-being subject that has not been investigated to truthfully appreciate its immensity and generality. Hence, there is a great need for further investigation into basic analysis and therapy of impotence[1]. Impotence and difficulty of discrete fertility were conveyed through ages and is also an available advanced difficulty nowadays, that influence 8-12% of couples globally. It may be difficult to diagnose the reason for infertility; but, in most cases it may be due to either dysregulation of sex hormonal axis or anatomical anomalies in both men and women. Change of impotence in smaller commercial countries are noticeably towering and compatible illnesses are organized for a considerable part of sterile. As per the WHO, comprehensive generality of main impotence in India ranges between 3.9% and 16.8%. Generality of main impotence possess too exist manifest differ over the ethnic group & castes inside the identical zone in India[2][3]. Impotence measure a male's ethnicity to consequence gestation in a fecund woman. Sterile is frequently expected to insufficiency in the semen, sperm abnormalities, sperm transport disorders, aspermia, improper spermatogenesis and decreased libido. Semen standard is used as a coordinate count of male fecundity. About 90% of male infertility difficulty are intellectual to sperm total. Chemotherapy with radiotherapy cause reduction of sperm counts. Anxiety would be described to exist a contributive element toward impotence[4].

Cyclophosphamide (CP or N,N-Bis (2-chloroethyl)-1,3,2-oxazaphosphinan-2-amine 2-oxide) is an anticancer antineoplastic would be designated as a male reproductive tract bioaccumulation. It is a nitrogenous relish antineoplastic out from those oxazophorines group concern till this category on cytotoxic/cytostatic medicines or Antineoplastics[5]. Cell-toxic medicine influence mostly diligently split up cells, that inside the testicles are Spermatogonia. 'Spermatogenic arrest' fails to usually cease cell division in Spermatogonia additionally ensuing hypophysectomy[6] or the way consequence of medicine-invade obstruction of

gonadotropin production. The implement before such 'Spermatogenic arrest' decrease gonads harm exist even now ambiguous.

*Dactylorhiza hatagirea* is think about as certain stimulant plant in traditional medicine and is working to increase production also as to rise robustness and energy. Literature review suggests so, the herb is existence provoke as an vegetative restore for sensual malfunction. Thus, the current research was undertaken to investigation the result of *D. hatagirea* in histological changes invade by cyclophosphamide treatment on testis of grown-up Wistar male rats.

## Materials and Methods

### 2.1 Chemicals

Entirely Chemicals for the current research take place obtain out of Sigma Aldrich (St. Louis, MO, USA), Merck Chemical Company (Darmstadt, Germany) and Sisco Research Laboratories (Mumbai, India).

### 2.2 Production of decoction

The bulbous roots of *Dactylorhiza hatagirea* were gather out of Thiruvananthapuram, Kerala, India. Authentication finished by Dr. K. Madhava Chetty, Plant Taxonomist, Sri Venkateswara University, Tirupati. A document copy (Voucher No. 1634) obsolete place within this herbarium, Department of Botany, Sri Venkateswara University to additional source. The collected herb substance remain clean with distilled water and air dried in shade at room temperature. The dried perspective were grind within dust utilize an battery-operated mixer. Dehydrated leaf dust (5g) was consecutively removed with petroleum ether, chloroform and methanol utilize Soxhlet equipment. The ethanolic revive of *D. hatagirea* bulbous roots were worn as in investigational research.

### 2.3. Animals

Healthy Male Wistar Albino rats consider regarding 150-200 g were used from Cape Bio Lab & Research Centre, Marthandam, Kanyakumari District, Tamil Nadu. The entire study was accept at this Institutional Animal Ethical Committee (IAEC) on Cape Bio lab and Research Centre with acceptance number CBLRC/IAEC/14/01 – 2020. The animals were retain in washed as well as dry polycarbonate enclosure with continue in a aerial enclosure with 12hours light - 12 hours dark cycle. The animals were cater for with standard pellet diet as well as water was specified that this diet is available at all times. During investigational motive the animals exist retain fasting overnight yet permit free approach to water.

### 2.4 Experimental design

The animals will be randomly separate in six groups of six animals each and will be use as follows:

**Group I:** Normal / vehicle control group; Animal accepted vehicle orally for 4 weeks.

**Group II:** Cyclophosphamide (CP) control I; Animal received 0.5ml of CP at a measure quantity of 6.5mg/kg bodyweight orally for 4 weeks followed by vehicle administration for 4 weeks [7][9].

**Group III:** Cyclophosphamide (CP) control II; Animal received 0.5ml of CP at a measure quantity of 6.5mg/kg bodyweight orally for 4weeks followed by vehicle administration for 8 weeks.

**Group IV:** Animal received 0.5ml of CP at a measure quantity of 6.5 mg/kg body weight orally for 4 weeks followed by management of ethanolic extract of roots of *D. hatagirea* at measure quantity of 100 mg/kg bodyweight for 4 weeks [10].

**Group V:** Animal received 0.5ml of CP at a measure quantity of 6.5 mg/kg body weight orally for 4 weeks followed by administration of ethanolic extract of roots of *D. hatagirea* at measure quantity of 200 mg/kg body weight for 4 weeks [11].

**Group VI:** Animal received 0.5ml of CP at a measure quantity of 6.5 mg/kg body weight orally for 4 weeks followed by administration of ethanolic extract of roots of *D. hatagirea* at measure quantity of 200 mg/kg body weight for 8 weeks.

This vehicle/revive was manage after 2 hours before CP administration. Animals from Groups I, II, IV and V were sacrificed after 4 weeks (day 29) of the experiment, while animals of Group III and VI were sacrificed after 8 weeks (day 57) of the experiment.

## 2.5 Histopathological analysis

Testis was instantly secure in alcoholic Bouin's fluid for 24 hours. Before absolute withdrawal of picric acid, the material was dry up in ethanol series (30%, 50%, 70%, 90% and 100%), empty in xylene and cleared for conservation of paraffin wax blocks. The material was next slit at 4-5µm width by spinning scraper and colour normally with haematoxylin and eosin (H-E) for histo-pathological investigation. Colour-wash histo-pathological segments were assess below Olympus research microscope. Photomicrography was taken one and the other near to high magnification together with low magnification.

## Results and Discussion

Examination of sections of testicles of rats use CP as 4 weeks appear histopathological change. In these samples, numerous separate testicle arise deteriorate with recognize and uneven basal lamina. The spermatogenic cells exist slighter dense with more or less organize vacuoles divide the cells out of every one further. Animals treated with 0.5ml of CP by a measure amount of 6.5 mg/kg poundage orally to 4weeks showed uneven basal lamina, reduced immense spermatogenic cells divide between vacuoles, Pyknotic core, protoplasm vacuolization in Spermatogonia, deteriorate tubule with decline inter tubular collagenous fibres. Protoplasm unit of spermatogonium exist a usual characteristic within each inspected samples (A and B) and these inter tubular veins remain congested (C). Animal received 0.5ml of at a measure quantity of 6.5 mg/kg poundage orally meant for 4weeks showed Congested Inter tubular veins, Cytoplasmic vacuolization in Spermatogonia, degenerated tubule. Entirely the over raise replace enhance further manifest toward testicles about animals handle for 4 weeks. Sample that insist out of such animals divulge noticeable deterioration inside testis, certain about it hold really this spermatogonia, while more exist totally deteriorate (C and D).Animal received 0.5ml of CP at a measure quantity of 6.5 mg/kg poundage orally meant for 4 weeks followed by administration of ethanolic extract of roots of *D. hatagirea* at measure level of 100 mg/kg poundage especially for 4 weeks showed deteriorate testis showed, Cytoplasmic vacuolization (arrow), fewer immense spermatogenic cells part besides vesicles as well as deregulate Leydig cells. Animal received 0.5ml of CP by a measure quantity of 6.5 mg/kg poundage orally meant for 4 weeks followed by administration of ethanolic extract of roots of *D. hatagirea* at measure quantity of 200 mg/kg poundage to 4 weeks showed Congested inter tubular arteriole (arrow) and inter tubular hemorrhage. Animals treated with ethanolic extract in distribution and CP for 4 weeks discuss a smaller noticeable diseased change as contrasted to CP served category. Animals co-administered along CP with ethanolic extract to 8 weeks show proceed level of advance inside testicular substance. Within this samples, testicular tubules arrangement, state of having cells and spermatic commodity and direction were noticeably better. Animal received 0.5ml of CP at a measure quantity of 6.5 mg/kg poundage orally to 4weeks followed by administration of ethanolic extract of roots of *D. hatagirea* at dose level of 200 mg/kg poundage everyday to 8 weeks manifest. As well, most about interstitial cells exist into usual reform with magnitude (F).

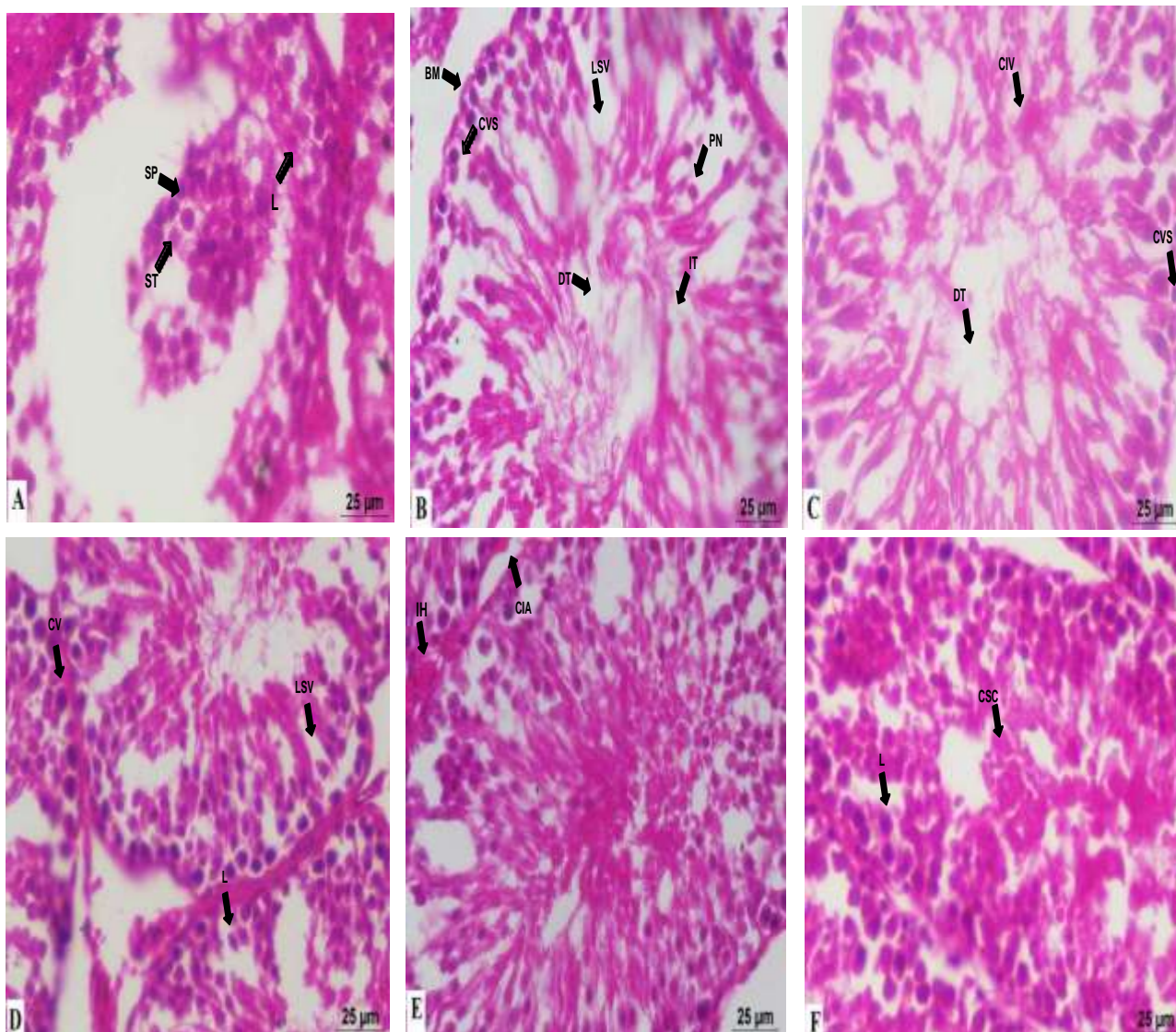


Figure 1. Figure showing histopathological alterations A: The section of control group testis showed Seminiferous tubules, Spermatogonia and Interstitial Leydig cells. Seminiferous tubules (ST), Spermatogonia (SP) and Interstitial Leydig cells(L), B: Uneven Basement Membrane (BM), Less compact Spermatogenic cells separated by Vacuoles (LSV), Pyknotic Nucleus (PN), Cytoplasmic Vacuolization in Spermatogonia (CVS), Degenerated Tubule (DT) and Degenerated Inter tubular Connective tissue (IT), C: Congested Inter tubular Veins(CIV), Cytoplasmic Vacuolization in Spermatogonia (CVS) and Degenerated tubule (DT), D: Cytoplasmic vacuolization (CV), less compact spermatogenic cells separated with vacuoles (LSV) and degenerated Leydig cells(L), E: Congested Inter tubular Arteriole (CIA) and Inter tubular Hemorrhage(IH), F: Seminiferous tubules with Compact Spermatogenic Cells (CSC) and nearly normal Leydig cells (L).

### Conclusion

The outcome manifest that using animals beyond CP bring about deterioration of tubules with deprivation of the male gamete. Treating rat beside CP with ethanolic extract bring about advance in affecting diseased change as well as improved effective amount of semen. Effective outcome about the present research specify so as ethanolic extract secured rat among CP persuade generative harmful. Supplementary work frame on biological and intra-cellular indicating trace appreciate effective process of herb take out of *Dactylorhiza hatagirea* to exist development of spermatozoa.

### References

1. Kumar N, Singh A K. Trends of male factor infertility, an important cause of infertility: A review of literature. *Journal of Human Reproductive Sciences*.2015;8:191-196.
2. Talwar P P, Go OP, Murali IN. Prevalence of infertility in different population groups in India and its determinants. *Statistics and Demography*, New Delhi: National Institute of Health and Family Welfare and Indian Council of Medical Research;1986.
3. Kumar D.Prevalence of female infertility and its socio-economic factors in tribal communities of Central India. *Rural Remote Health*.2007;7:456.
4. Abbas Ali Mahdi,etal. *Withania somnifera* improves semen quality in stress-related male infertility. *Evidence based Complementary and Alternative Medicine*. Hindawi publishing corporation. 2011; 9 Pages. Article ID 576962.doi:10.1093/ecam/nep/38.
5. Bach J.F, Strom T. *The mode of action of immunosuppressive agents*.Amsterdam. Elsevier.1986;379p.
6. Clermont Y, Harvey C. Effects of hormones on spermatogenesis in the rat. *CIBA Foundation on Endocrinology*.1967;16:173-196.
7. Sakr,etal. Effect of Ginkgo biloba extract on Cyclophosphamide – induced reproductive toxicity and oxidative stress in male albino mice. *World J Pharm Sci* 2015;3(1):16-25.
8. Pant S, Rinchen T. *Dactylorhiza hatagirea* : a high value medicinal orchid. *J Med Plants Res*.2012;6:3522-3524.
9. Paget G.E, Barnes J.M. *Toxicity Testis In: Evaluation of Drug Activities Pharmacometrics*. Edited by Laurence D.R. and Bacharach A.L. Academic Press,London and New York,1964;Vol.1,P.135.
10. Thakur M, et al. Improvement of penile erection, sperm count and seminal fructose levels in vivo and nitric oxide release in vitro by ayurvedic herbs. *Andrologia*.2011.
11. M Thakur, V.K.Dixit. Aphrodisiac activity of *Dactylorhiza hatagirea*(D.Don)Soo in male albino rats. *Evidence Based Complementary and Alternative Medicine*.2007;4(1): 29-31.