

## Awareness About Oral Manifestation Of Endocrine Disturbances Among General Physicians

<sup>1</sup>Srithika M , <sup>2</sup>Abilasha R , <sup>3</sup>Lakshmi T.A

<sup>1</sup>Saveetha Dental college and hospitals, Saveetha institute of medical and technical sciences Saveetha university, Chennai-600077 Email id: [srithikamurugan@gmail.com](mailto:srithikamurugan@gmail.com)

<sup>2</sup>Reader, Department of oral pathology, Saveetha Dental college and hospitals, Saveetha institute of medical and technical sciences Saveetha University, Chennai-600077. Email id : [abilasha@saveetha.com](mailto:abilasha@saveetha.com)

<sup>3</sup>Senior lecturer, Department of oral pathology, Saveetha Dental college and hospitals, Saveetha institute of medical and technical sciences Saveetha University, Chennai-600077. Email id : [lakshmita.sdc@saveetha.com](mailto:lakshmita.sdc@saveetha.com)

---

### ABSTRACT

**INTRODUCTION:** Hormonal secretion is maintained by the endocrine system. Central nervous system is closely erupted as the hypothalamus and pituitary glands control its functions. Homeostasis is maintained and controls physiology of the human body. Adaptation to environmental changes is maintained by the neuroendocrine system. Oral manifestation of endocrine disorder is very important for every dentist to avoid the resulting complications.

**AIM:** The aim of the study is to know the oral manifestation of endocrine disorder among general physicians.

**MATERIALS AND METHODS:** In view of this, a survey was conducted across general physicians in south tamilnadu. For which 106 responses were received and recorded. Statistical analysis was done and the results were obtained in the form of pie charts, bar graphs and association was performed using the chi-square test. The statistical software used was SPSS version 2.

**RESULT:** Over 106 responses majority of them belong to the age group of above 40 and about 35.8% of them are females. Their responses were recorded and validation was done, p value of 0.342, was (p value >0.05 is significant) statistically not significant.

**DISCUSSION:** Oral manifestations in patients with hyperparathyroidism are brown Tumor, loss of bone density, soft tissue calcification, and dental abnormalities, such as development defects, alterations in dental eruption.

**CONCLUSION** :From our study we can conclude that general physicians have awareness about oral manifestation of endocrine disturbances. Stress reduction, awareness of drug side effects or interactions, and vigilance for appearance of signs or symptoms of hormone toxicity are among the responsibilities of the oral health care provider.

**KEYWORDS:** oral manifestation, endocrine disorders ,homeostasis ,innovative technique, complications

---

## INTRODUCTION

Endocrine system is made of several endocrine glands located in different parts of the human body. Endocrine glands are called ductless glands, Except diabetes mellitus and thyroid disorders are uncommon. They are rare causes of oral disease but occasionally lead to diagnosis. Patients having Addison's disease, diabetes mellitus, thyrotoxicosis need special care for surgery. (1,2)

Thyroid gland is a bilobed structure lying on either side of the trachea. Thyroid dysfunction is the 2nd most common glandular disorder of the endocrine system. Oral health care professionals should be clear with oral and systemic manifestation of thyroid disease. Patients with thyroid disease history should be evaluated carefully and should be treated in a way that limits stress and infection.

Hyperpituitarism: when macrodontia and macroglossia is shown by a patient with increase in height with enlargement of facial structures, then it suggests that the patient is having hypopituitarism. A malfunction in the pituitary gland like hyperpituitarism is most likely caused by a tumor. The most common type of tumor is called an adenoma and is noncancerous.

Hypothyroidism: cretinism is known as childhood hypothyroidism and it is known by thick lips, large protruding tongue, malocclusion and delayed eruption of teeth. long term effects of severe hypothyroidism on craniofacial growth and dental development have also included imp action of the mandibular second molars .

The oral health care professional should be familiar with the oral and systemic manifestations of thyroid disease so he or she can identify any complication and assess the level to which the condition is controlled. If a suspicion of thyroid disease arises for an undiagnosed patient, all elective dental treatment should be put on hold until a complete medical evaluation is performed. Patients with a history of thyroid diseases should be carefully evaluated to determine the level of medical management, and they should be treated in a way that limits stress and infection. Consultation with the patient's primary care physician or an endocrinologist is warranted if any sign or symptom of thyroid disease is noted on examination. If an emergent dental procedure is needed in the initial weeks of thyroid treatment, close work-up with the endocrinologist is needed. Our team has extensive knowledge and

research experience that has translate into high quality publications (3),(4),(5),(6),(7),(8),(9),(10),(11),(12),(13),(14),(15),(16),(17),(18),(19),(20),(21),(22) The aim of the study is to assess the oral manifestation of endocrine disorders among general physicians.

## **MATERIALS AND METHODS**

A survey was conducted through google forms -a cross sectional study (questionnaire based) for general physicians in Chennai of south tamilnadu. The conventional samples are from south tamilnadu where google forms are created and shared among general physicians and their responses are recorded. Study setting is questionnaire based survey and sample form is general physicians in south tamilnadu. Sample size was 106. Subjects, those who are interested voluntarily in willing to do survey are included, Subjects, those who were not willing to do survey.

Statistical analysis was done and the results were obtained in the form of pie charts, bar graphs and association was performed using the chi-square test. The statistical software used was SPSS version 2. P value <0.05 was considered significant.

## **RESULT**

In this study 106 general physicians had responded to the questionnaire and the data then collected, analysed and tabulated. When diabetes mellitus classic oral manifestation was asked 66.04% said yes 33.96% said no Figure 1. Macroglossia and Micrognathia is an oral manifestation of increased growth hormone,66.04% responded yes they know and 33.96 responded that they don't know Figure 2. Diabetes mellitus shows the most classic manifestation like periodontitis, periodontal abscess, 71.70% responded yes they know and 28.30% responded they are not aware Figure 3, 33.96% of both male and female responded yes they know Addison's disease causes typical hyperpigmentation of oral mucosa and 10.38% of females and 21.70% of male responded that they are not aware Figure 4, 34.91% of females and 36.79% of male responded yes they know diabetes mellitus shows the most classic oral manifestations like periodontitis, periodontal abscess, whereas 9.43% of females and 18.87% of male responded that they are not aware Figure 5, 33.96% of females and 32.08% of male responded yes they know macroglossia and macrognathia is an oral manifestation of increased growth hormone, whereas 10.38% of females and 23.58% of male responded that they are not aware (Figure 6).

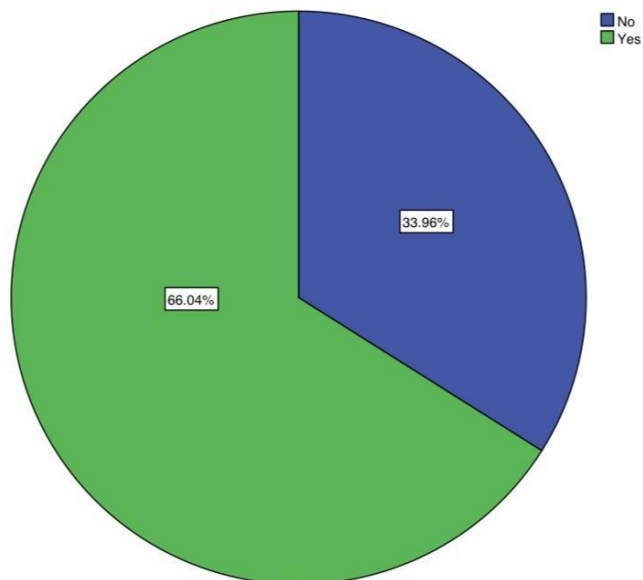


Figure 1 : This pie chart shows whether hypopituitarism also causes cardiovascular and respiratory complications. 66.04%(green) responded yes and 33.96% responded no(blue). Majority of participants agreed that hypopituitarism also causes cardiovascular and respiratory complications

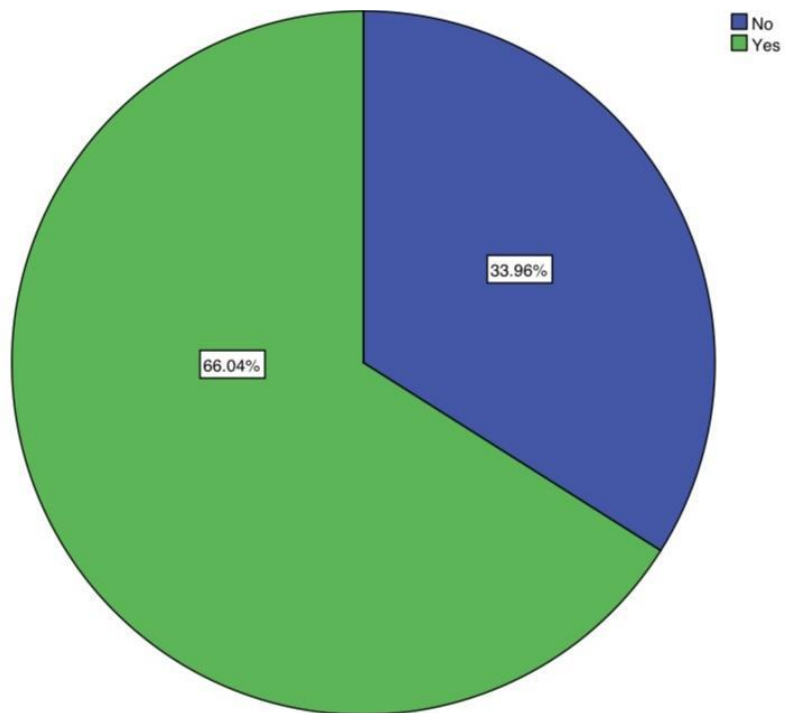


Figure 2: This pie chart reveals if they know that macroglossia and macrognathia as an oral manifestation of increased growth hormone. 66.04% (green) responded yes they know and 33.96 responded that they don't know (blue). Majority of the participants agreed that macroglossia and macrognathia as an oral manifestation of increased growth hormone.

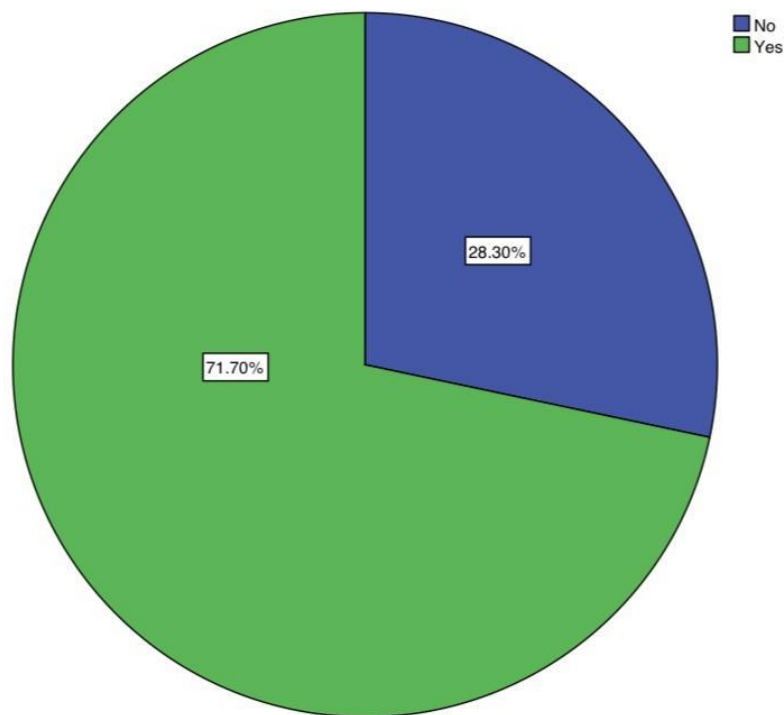


Figure 3: This pie chart shows if they know diabetes mellitus shows the most classic manifestation like periodontitis, periodontal abscess. 71.70% (green) responded yes and 28.30% responded no (blue). Majority of the participants responded they know diabetes mellitus shows the most classic manifestation like periodontitis, periodontal abscess

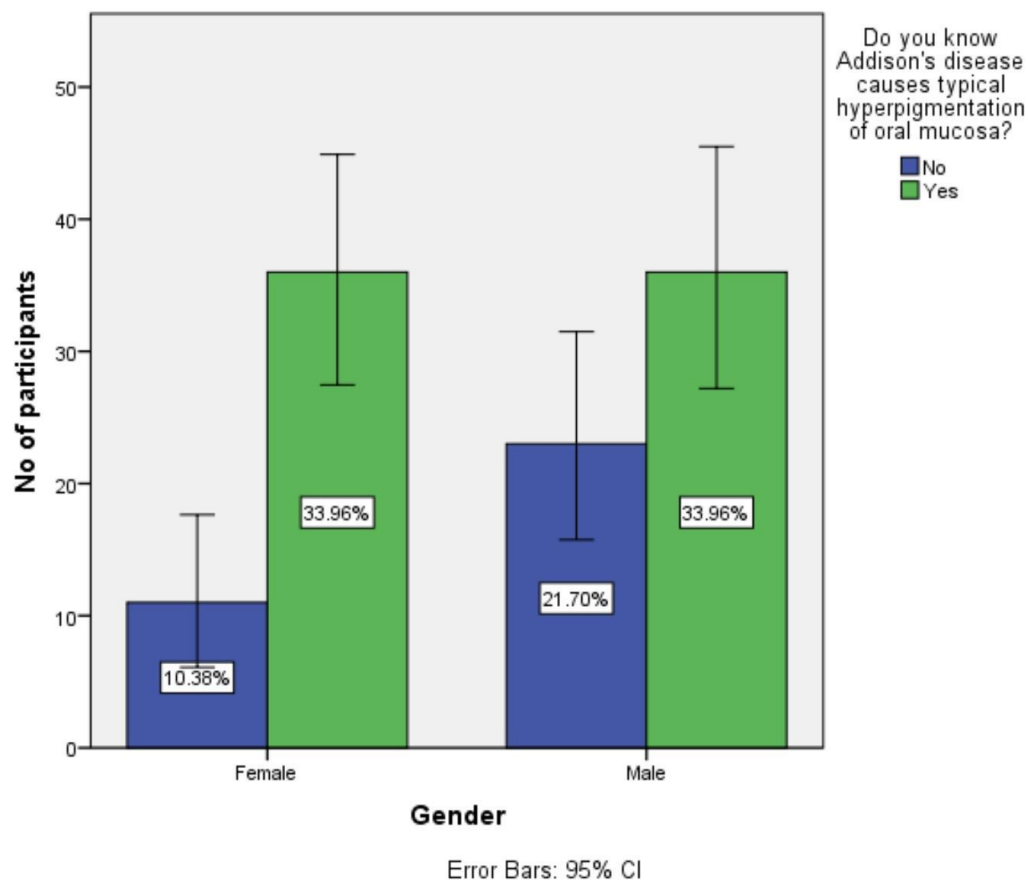


Figure 4: In this bar graph X axis represents gender and Y axis represents percentage of response. 33.96% of both male and female(green) responded that they know Addison's disease causes typical hyperpigmentation of oral mucosa and 10.38% of females and 21.70% of male responded that they are not aware(blue).Both males and females agree that Addison's disease causes typical hyperpigmentation of oral mucosa. p-value is 0.367,( p value >0.05 is significant). Hence, it's statistically not significant.

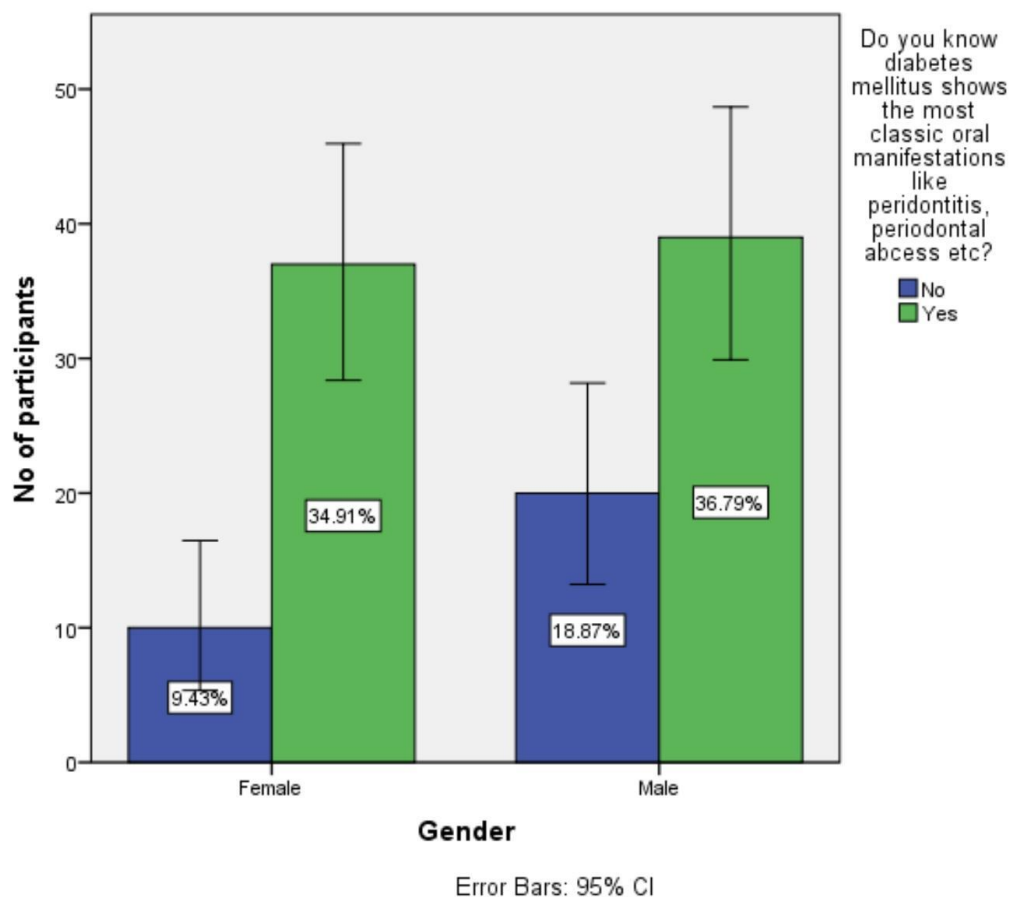


Figure 5: In this bar graph X axis represents gender and Y axis represents percentage of response. 34.91% of females and 36.79% of male(green) responded they know diabetes mellitus shows the most classic oral manifestations like periodontitis, periodontal abscess, whereas 9.43% of females and 18.87% of male responded that they are not aware(blue). p value is 0.509, ( $p > 0.05$ ) hence, it's statistically not significant.



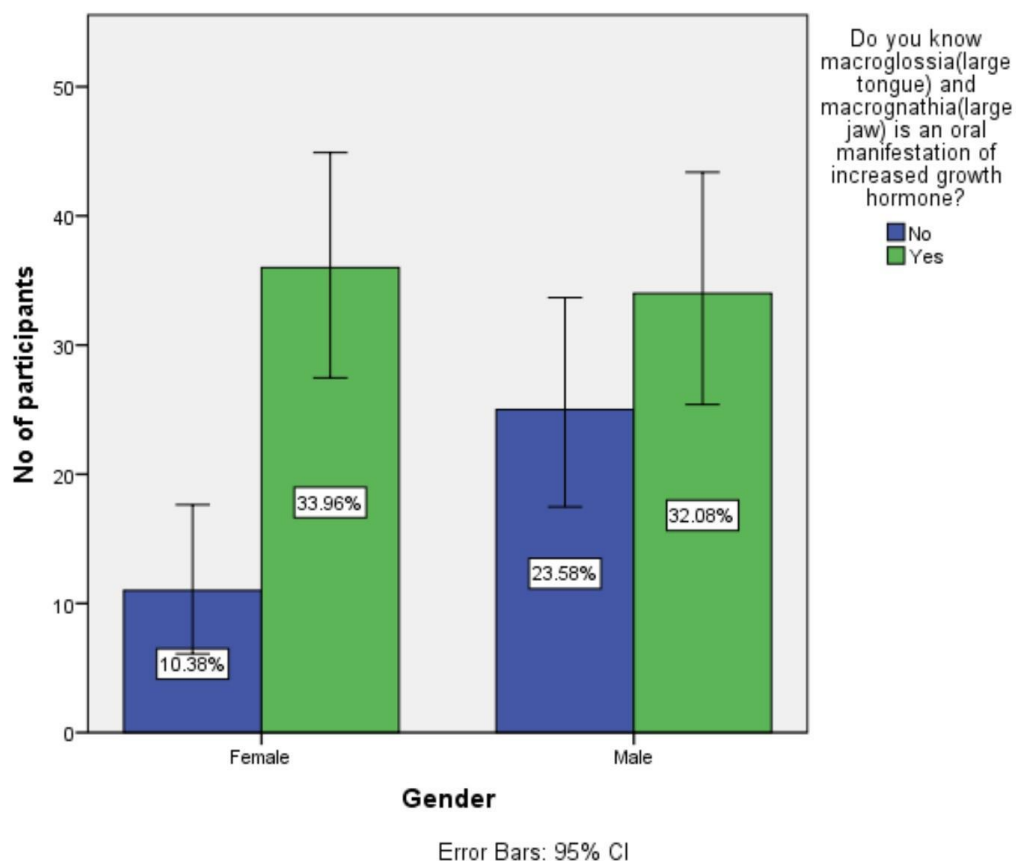


Figure 6: In this bar graph X axis represents gender and Y axis represents percentage of response. 33.96% of females and 32.08% of male (green) responded they know macroglossia and macrognathia is an oral manifestation of increased growth hormone, whereas 10.38% of females and 23.58% of male (blue) responded that they are not aware. P value is 0.489, (p value > 0.05 is significant). Hence, it's statistically not significant.

## DISCUSSION

Two mechanisms involved of diabetic complications. Manifestation of hypothyroidism, cretinism is known for childhood hypothyroidism. Thick lips, large protruding tongue malocclusion and delayed tooth eruption. Thickening of lip is because of accumulation of subcutaneous mucopolysaccharide ie glycosaminoglycans (23) Hypothyroidism craniofacial growth and dental development of mandibular second molars dissociation of ramus growth and failure of resorption. Decrease in thyroid hormone

production and thyroid gland function. Chronic thyroiditis (Hashimoto's disease), radioactive iodine, surgery and pharmacological agents causes such disease.(24) Slower metabolic rate, Weight gain, lethargy, intolerance to cold, dry and cool skin, are the symptoms for insufficient levels of thyroid hormone. There is a normal blood pressure, but heart rate is slow. Previous article oral manifestation of endocrine dysfunction will discuss the effects of over and under-secretion of each endocrine gland separately, showing its influence on the development and maintenance of the health of the teeth and supporting structures. Diabetes mellitus is the most common endocrinological disease, with an incidence of 3%. Periodontitis risk is three times greater in diabetic patients than in the general population and it may worsen the diabetes evolution. Periodontitis in diabetic patients needs a rapid diagnosis and treatment. We also present the oral aspects of thyroid, parathyroid, suprarenalian, growth hormone and female hormones pathology. The incidence of these troubles is less important, but oral manifestations may reveal an endocrine dysfunction (2)

Hyperthyroidism-condition caused due to unregulated production of thyroid hormones tremor, emotional instability, intolerance to heat, increased cardiac output. Burning mouth condition that causes mouth dryness in many people with thyroid disease.(25)Role of endocrinologist: Doctors who treat children and adults with thyroid disorder could be good referral sources for patients. Treating patients with thyroid disorder is an opportunity to excel. Communication of dentists with endocrinologists is a critical component of safe and optimal treatment of thyroid patients. There may be bidirectional communication. They must be apprised of oral manifestation of the disease, and dentists must be updated on thyroid control medications to help them to maintain the oral health of patients. The dental professional protects the thyroid gland using a thyroid collar taking patient x-rays exposure is a known risk factor. Length and current state of therapy causes metabolic control of patients. The understanding of thyroid dysfunction is of significant importance to the dentist for two reasons. Serious thyroid disorder may be first suspected by a dentist. Dentists play an important role as a part of the health care team in detecting thyroid abnormalities. To avoid possible dental complications resulting from treating patients with thyroid disorders.(25,26)

In one way the thyroid gland can be protected by dental professionals is to use a thyroid collar while taking patient x-rays. Thyroid is sensitive to radiation and excess radiation exposure is a known risk factor for various thyroid conditions.(27) Dental management of hypothyroidism:Susceptibility to infection-patients hypothyroidism delay wound healing associated with increased risk for infection of

unhealed tissue to the organism. Valvular pathology present, need for antibiotic prophylaxis must be assessed. Drug actions and interaction sensitive to central nervous system.(28)

In other studies, awareness on the preventive measures were taken in various parts of India. The current situation requires knowledge about the endocrine disturbances and preventive measures. Our study indicates a significant impact of oral manifestation preventive measures on limited sample sizes. Government aided programs or NGO's aided programs can be organised in rural shades of Tamilnadu for creating more awareness on oral manifestation of endocrine disturbances. Further studies with larger sample size are needed to clarify the full impact on oral manifestation.

## CONCLUSION

Dental treatment modification may be necessary stress reduction awareness of drugs and appearance of signs or symptoms of hormone toxicity. Among the responsibilities of oral health care providers. Diabetes mellitus leads to multiple complications. Doctors and dentists make an early diagnosis for patients related to orofacial infection.

## ACKNOWLEDGEMENT

Saveetha Dental College and Hospitals, Saveetha Institute of Medical and Technical Sciences and Saveetha University

**CONFLICT OF INTEREST:** The author declares that there was no conflict of interest in the present study.

**SOURCE OF FUNDING:** The present study was supported by the following agencies

- Saveetha Institute of Medical and Technical Sciences
- Saveetha Dental College and Hospitals
- Saveetha University
- Lions club Tirupur.

## REFERENCE:

1. Al-Yasiry A, Al-Jammali ZM. Oral Manifestation for Patients with Thyroid Dysfunction and it's Management in Dental Clinic -A Review [Internet]. International Journal of Drug Research And Dental Science. 2020. Available from: <http://dx.doi.org/10.36437/ijdrd.2020.2.1.n>

2. Chandna S, Bathla M. Oral manifestations of thyroid disorders and its management. *Indian J Endocrinol Metab.* 2011 Jul;15(Suppl 2):S113–6.
3. Princeton B, Santhakumar P, Prathap L. Awareness on Preventive Measures taken by Health Care Professionals Attending COVID-19 Patients among Dental Students. *Eur J Dent.* 2020 Dec;14(S 01):S105–9.
4. Mathew MG, Samuel SR, Soni AJ, Roopa KB. Evaluation of adhesion of *Streptococcus mutans*, plaque accumulation on zirconia and stainless steel crowns, and surrounding gingival inflammation in primary molars: randomized controlled trial. *Clin Oral Investig.* 2020 Sep;24(9):3275–80.
5. Sridharan G, Ramani P, Patankar S, Vijayaraghavan R. Evaluation of salivary metabolomics in oral leukoplakia and oral squamous cell carcinoma. *J Oral Pathol Med.* 2019 Apr;48(4):299–306.
6. R H, Hannah R, Ramani P, Ramanathan A, Jancy MR, Gheena S, et al. CYP2 C9 polymorphism among patients with oral squamous cell carcinoma and its role in altering the metabolism of benzo[a]pyrene [Internet]. Vol. 130, *Oral Surgery, Oral Medicine, Oral Pathology and Oral Radiology.* 2020. p. 306–12. Available from: <http://dx.doi.org/10.1016/j.oooo.2020.06.021>
7. Antony JVM, Ramani P, Ramasubramanian A, Sukumaran G. Particle size penetration rate and effects of smoke and smokeless tobacco products - An invitro analysis. *Heliyon.* 2021 Mar 1;7(3):e06455.
8. Sarode SC, Gondivkar S, Sarode GS, Gadbail A, Yuwanati M. Hybrid oral potentially malignant disorder: A neglected fact in oral submucous fibrosis. *Oral Oncol.* 2021 Jun 16;105390.
9. Hannah R, Ramani P, WM Tilakaratne, Sukumaran G, Ramasubramanian A, Krishnan RP. Author response for “Critical appraisal of different triggering pathways for the pathobiology of pemphigus vulgaris—A review” [Internet]. Wiley; 2021. Available from: <https://publons.com/publon/47643844>
10. Chandrasekar R, Chandrasekhar S, Sundari KKS, Ravi P. Development and validation of a formula for objective assessment of cervical vertebral bone age. *Prog Orthod.* 2020 Oct 12;21(1):38.
11. Subramanyam D, Gurunathan D, Gaayathri R, Vishnu Priya V. Comparative evaluation of salivary malondialdehyde levels as a marker of lipid peroxidation in early childhood caries. *Eur J Dent.* 2018

Jan;12(1):67–70.

12. Jeevanandan G, Thomas E. Volumetric analysis of hand, reciprocating and rotary instrumentation techniques in primary molars using spiral computed tomography: An in vitro comparative study. *Eur J Dent*. 2018 Jan;12(1):21–6.
13. Ponnulakshmi R, Shyamaladevi B, Vijayalakshmi P, Selvaraj J. In silico and in vivo analysis to identify the antidiabetic activity of beta sitosterol in adipose tissue of high fat diet and sucrose induced type-2 diabetic experimental rats. *Toxicol Mech Methods*. 2019 May;29(4):276–90.
14. Sundaram R, Nandhakumar E, Haseena Banu H. Hesperidin, a citrus flavonoid ameliorates hyperglycemia by regulating key enzymes of carbohydrate metabolism in streptozotocin-induced diabetic rats. *Toxicol Mech Methods*. 2019 Nov;29(9):644–53.
15. Alsawalha M, Rao CV, Al-Subaie AM, Haque SKM, Veeraraghavan VP, Surapaneni KM. Novel mathematical modelling of Saudi Arabian natural diatomite clay. *Mater Res Express*. 2019 Sep 4;6(10):105531.
16. Yu J, Li M, Zhan D, Shi C, Fang L, Ban C, et al. Inhibitory effects of triterpenoid betulin on inflammatory mediators inducible nitric oxide synthase, cyclooxygenase-2, tumor necrosis factor- $\alpha$ , interleukin-6, and proliferating cell nuclear antigen in 1, 2-dimethylhydrazine-induced rat colon carcinogenesis. *Pharmacogn Mag*. 2020;16(72):836.
17. Shree KH, Hema Shree K, Ramani P, Herald Sherlin, Sukumaran G, Jeyaraj G, et al. Saliva as a Diagnostic Tool in Oral Squamous Cell Carcinoma – a Systematic Review with Meta Analysis [Internet]. Vol. 25, Pathology & Oncology Research. 2019. p. 447–53. Available from: <http://dx.doi.org/10.1007/s12253-019-00588-2>
18. Zafar A, Sherlin HJ, Jayaraj G, Ramani P, Don KR, Santhanam A. Diagnostic utility of touch imprint cytology for intraoperative assessment of surgical margins and sentinel lymph nodes in oral squamous cell carcinoma patients using four different cytological stains. *Diagn Cytopathol*. 2020 Feb;48(2):101–10.
19. Karunagaran M, Murali P, Palaniappan V, Sivapathasundharam B. Expression and distribution pattern of podoplanin in oral submucous fibrosis with varying degrees of dysplasia – an

- immunohistochemical study [Internet]. Vol. 42, Journal of Histotechnology. 2019. p. 80–6. Available from: <http://dx.doi.org/10.1080/01478885.2019.1594543>
20. Sarode SC, Gondivkar S, Gadbail A, Sarode GS, Yuwanati M. Oral submucous fibrosis and heterogeneity in outcome measures: a critical viewpoint. *Future Oncol*. 2021 Jun;17(17):2123–6.
  21. Raj Preeth D, Saravanan S, Shairam M, Selvakumar N, Selestina Raja I, Dhanasekaran A, et al. Bioactive Zinc(II) complex incorporated PCL/gelatin electrospun nanofiber enhanced bone tissue regeneration. *Eur J Pharm Sci*. 2021 May 1;160:105768.
  22. Prithiviraj N, Yang GE, Thangavelu L, Yan J. Anticancer Compounds From Starfish Regenerating Tissues and Their Antioxidant Properties on Human Oral Epidermoid Carcinoma KB Cells. In: PANCREAS. LIPPINCOTT WILLIAMS & WILKINS TWO COMMERCE SQ, 2001 MARKET ST, PHILADELPHIA ...; 2020. p. 155–6.
  23. Silvertone folio, Colorado [Internet]. 1905. Available from: <http://dx.doi.org/10.3133/gf120>
  24. Malamed SF. Medical Emergencies in the Dental Office - E-Book. Elsevier Health Sciences; 2014. 576 p.
  25. Park JN, Schneider KE, Fowler D, Sherman SG, Mojtabai R, Nestadt PS. Polysubstance Overdose Deaths in the Fentanyl Era: A Latent Class Analysis. *J Addict Med* [Internet]. 2021 Mar 4; Available from: <http://dx.doi.org/10.1097/ADM.0000000000000823>
  26. Huber T, Goldman O, Epstein AE, Stella G, Sakmar TP. Principles and Practice for SARS-CoV-2 Decontamination of N95 Masks with UV-C. *Biophys J* [Internet]. 2021 Mar 3; Available from: <http://dx.doi.org/10.1016/j.bpj.2021.02.039>
  27. Yagiela LM, Pfarr MA, Meert KL, Odetola FO. Post-hospitalization follow-up recommendations after pediatric critical illness due to respiratory failure. *Pediatr Pulmonol* [Internet]. 2021 Feb 28; Available from: <http://dx.doi.org/10.1002/ppul.25343>
  28. Mariotti A, Antognoli M, Galletti C, Mauri R, Salvetti MV, Brunazzi E. A Study on the Effect of Flow Unsteadiness on the Yield of a Chemical Reaction in a T Micro-Reactor. *Micromachines* (Basel) [Internet]. 2021 Feb 27;12(3). Available from: <http://dx.doi.org/10.3390/mi12030242>