

## Knowledge About Tongue And Its Histology Among Dental Students - A Cross Sectional Survey

### Ramya Anbu

Saveetha Dental College and Hospitals,  
Saveetha Institute of Medical and Technical Science,  
Saveetha University,  
Chennai-600077,  
Tamil Nadu, India  
E-mail: [152001017.sdc@saveetha.com](mailto:152001017.sdc@saveetha.com)

### Dr.R.Priyadharshini

Senior lecturer,  
Department of Pathology,  
Saveetha Dental College and Hospitals,  
Saveetha Institute of Medical and Technical Science,  
Saveetha University,  
Chennai-600077,  
Tamil nadu, India.  
Email ID: [priyadharshini.sdc@saveetha.com](mailto:priyadharshini.sdc@saveetha.com)

### Dr.Suganya.P

Senior lecturer,  
Department of Oral Pathology,  
Saveetha Dental College and Hospitals,  
Saveetha Institute of Medical and Technical Science,  
Saveetha University,  
Chennai-600077,  
Tamil Nadu, India  
Email ID: [suganyap.sdc@saveetha.com](mailto:suganyap.sdc@saveetha.com)

---

#### **ABSTRACT :**

**Background:** Tongue is an extremely sensitive organ that is composed of muscles and covered by specialized mucosa. The function of the tongue includes mastication, deglutition and speech.

**Aim:** To assess knowledge about the tongue and its histology among first year dental students.

**Materials and methods:** This cross sectional study was conducted among 100 students in a private institution in chennai. Participants were chosen randomly after obtaining permission from administration. A questionnaire was asked and data was analysed by SPSS version 23.

**Results:** There were 100 responses collected from first year students. The study showed that 79.2% were aware of tongue development among dental students and 20.8 % were not aware. The association between gender and development of tongue yields p value of 0.56 which is not statistically significant.

**Conclusion:** Within the limitations of the study ,the result suggests that the majority of the dental students were aware of the tongue and its histology. Future studies to be conducted in large samples to make the context evidence.

**Key words:** Mastication, Deglutition, Speech, Muscles, Gestation , innovative

## INTRODUCTION

Tongue is an extremely sensitive organ that performs a complex muscle background. Primary function of tongue is stomatognathic system, such as mastication, deglutition and speech , which requires the active involvement of tongue. Embryologically, the development of the tongue is a very complicated process that starts around the fourth and fifth week of gestation period and its development has a marked influence on the oral cavity.

Tongue contains intrinsic muscles and extrinsic muscles. Intrinsic muscles are superior longitudinal, inferior longitudinal, transverse and vertical. Superior longitudinal arises from fibrous tissues deep to the mucus membrane on the dorsum of the tongue and the midline lingual septum. Inferior longitudinal originates from fibrous tissue beneath the mucus membrane stretching tip of the tongue longitudinally to the root of tongue and hyoid bone(1). Transverse lies as a sheet on either side of the midline in a plane that is deep to the superior longitudinal muscles but superficial to genioglossus. Verticality is found at the border of the anterior part of the tongue. Extrinsic muscles are genioglossus, hypoglossus, styloglossus, palatoglossal. Genioglossus- protrudes the tongue, hypoglossus- depresses the tongue, styloglossus- retract the tongue, palatoglossal- elevates the tongue(2).

The bulk of the tongue is made of striated muscle. The mucosal membrane consists of a connective layer ( corium ), lined by stratified squamous epithelium(3). On the oral part of the dorsum, it is thin, forms papillae and is adherent to the muscle. Taste buds are most numerous on the side of the circumvallate papillae which helps in bitterness. Taste buds are numerous over the foliate papillae and over the posterior one third of the tongue and sparsely distributed on the fungiform papillae , the soft papillae,(4) the epiglottis and pharynx. There are no taste buds on the mid dorsal region of the oral tongue.

Nerves to the tongue are vago accessory complex, internal laryngeal nerve and branch of vagus nerve, glossopharyngeal nerve, chorda tympani and hypoglossal nerve. Vago Accessory supplies to palatoglossus . Both general sensation and taste was sensed by the glossopharyngeal nerve and the general sensation by lingual and taste by chorda tympani. Seven muscles of the tongue are supplied by hypoglossal nerves(5). Thus, tongue is one of the important topics to be

known by all dental students. Our team has extensive knowledge and research experience that has translate into high quality publications(6),(7),(8),(9),(10),(11),(12),(13),(14),(15),(16),(17),(18),(19),(20),(21),(22),(23),(24),(25). This study is to evaluate the knowledge about tongue and its histology among dental undergraduates in a private dental college.

## **MATERIALS AND METHOD**

This is a questionnaire based cross sectional study. The survey was conducted among 100 dental students at a private dental college and a simple random sampling was done for choosing the participants. Questions were prepared regarding histology of tongue and distributed among dental students through online based survey forms (i.e.,google forms). The responses were collected and tabulated in MS excel sheet and data entered in SPSS software 23 and chi-square test is used. The p-value is 0.56 and the results were represented in a bar graph and pie charts.

### **THE QUESTIONNAIRE IS AS FOLLOWS:**

- 1.Which of the following week do you think the tongue develops?
- 2.Do you know which of the following papillae do not contain taste buds ?
- 3.Which of the following do you think supplies the posterior one-third of tongue?
- 4.Which of the following do you think supplies general sensation to the anterior two-third of tongue?
- 5.Which of the following do you think supplies blood to the tongue?
- 6.Do you know which of the following are mushroom shaped papillae?
- 7.Do you know which of the following is keratinised papillae?
- 8.Which of the following muscle helps the tongue to move forward ?
- 9.Do you know from which of the following the anterior two thirds of the tongue derived from ?
- 10.Which of the following do you think is the intrinsic muscle of the tongue?

## **RESULTS**

In our study, a total of 100 respondents were included. Among them 64 of them were male while 36 of them were female students. In the present study, 79.21% of students were aware about the development of the tongue.While 20.29% of students were unaware about the development of tongue (**figure 1**). In this study, the majority 85.15% of students were aware of filiform papillae (**figure 2**). Also, 61.39% of the students were aware of the nerve supply of one third of tongue (figure 3). And Majority 57.43% of the population were aware of the general sensation to the anterior two third of the tongue while 42.57% of the population were unaware (figure 4). In the present study, 72.28% were aware of the blood supply of the tongue, while 27.72% of the population were unaware of the blood supply of the tongue (figure 5). In this study, the majority 85.15% of the population were aware of mushroom shaped papillae and 14.85% were not aware of mushroom shaped papillae (figure 6). And 86.14% of the population were aware of the keratinised papillae and remaining 13.86% were not aware (figure 7). In our study, the majority 87.13% of the population were aware of the muscles that

help to move the tongue forward while 12.87% of the population were unaware of the muscles that help to move the tongue forward (figure 8). In the study, the majority 87.00% of the population were aware of derivation of the anterior two third of tongue while 13.00% of the population were unaware of the derivation of the anterior two third of tongue (figure 9). The majority 83.00% of the population were aware of intrinsic muscles of the tongue whereas 17.00% of the population were unaware of intrinsic muscles of the tongues (figure 10). The bar graph represents the association between gender and respondents who were aware of the development of the tongue and pearson chi square test shows p value is 0.931,(p value > 0.05). Hence, statistically not significant (figure 11). In our study, the bar graph represents the association between gender and respondents who were aware of filiform papillae and the significant value is 0.937 ,it is not significant. Pearson chi square test shows p value is 0.937, (p value > 0.05). Hence, statistically not significant (figure 12). The bar graph represents the association between gender and respondents who were aware of the nerve supply of one third of tongue (figure 13) and the significant value is 0.957, it is not significant. Pearson chi square test shows p value is 0.957, (p value > 0.05). Hence, it is statistically not significant (figure 13).

**Which of the following week do you think the tongue begins to develop around**

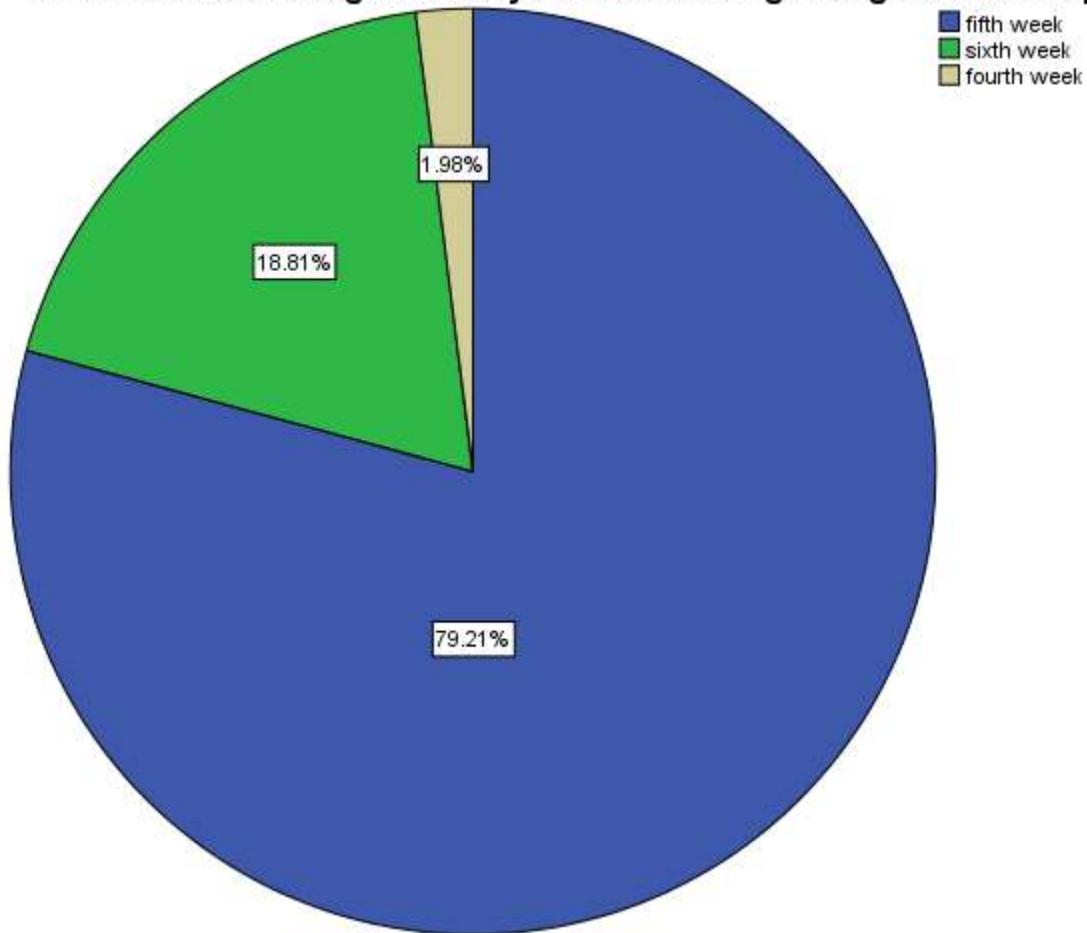


Figure 1: Pie chart shows the responses on tongue development. Blue represents the fifth week ,green represents the sixth week and moss color represents the fourth week. Majority 79.2% of

the population (fifth week) were aware whereas 1.98% (fourth week) and 18.81 % (sixth week) of the population were not aware of tongue development.

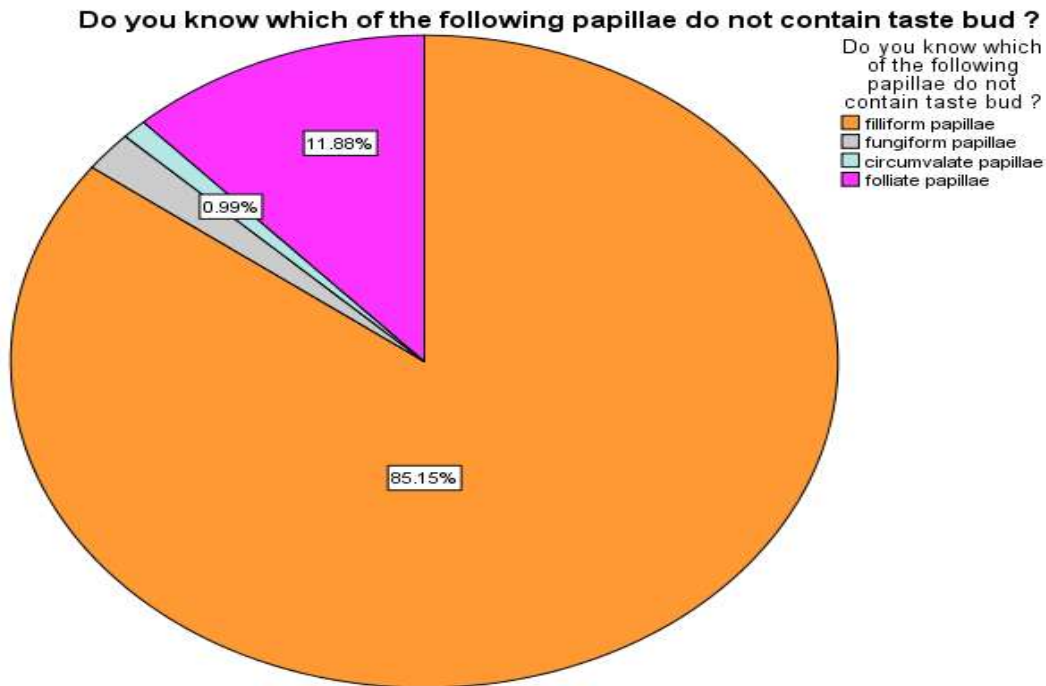


Figure 2 : Pie chart shows the response for papillae which do not contain taste buds. Orange indicates filiform papillae, sky blue indicates circumvallate papillae, pink represents foliate papillae and grey represents fungiform papillae. Majority 85.1% of the population (filiform papillae) were aware whereas 0.99% (circumvallate papillae), 1.98% (fungiform papillae) and 11.88% (foliate papillae) of the population weren't aware that filiform papillae do not contain taste buds .

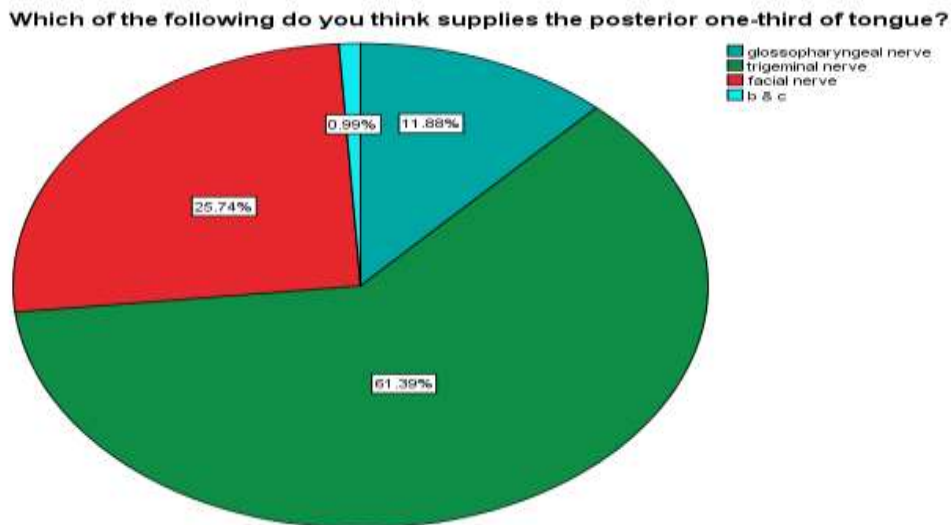


Figure 3 Pie chart shows the responses about nerves that supply to the posterior one - third of the tongue Cadet blue indicates glossopharyngeal nerve, azure blue indicates both trigeminal and facial nerve , dark green indicates only trigeminal nerve and red represents facial nerve. Majority 61.39%of the population (trigeminal nerve) were aware whereas 11.88% (glossopharyngeal nerve), 25.74% (facial nerve) and 0.99 % (both B and C) of the population were not aware about the nerve supply of posterior one-third of the tongue.

**Which of the following do you think supplies general sensation to the anterior two - third of tongue**

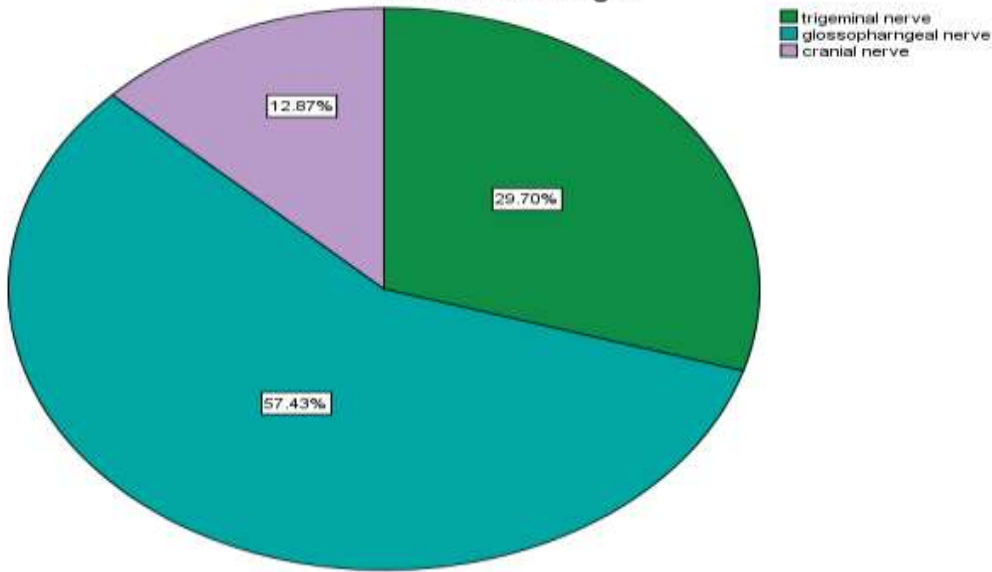


Figure 4 : Pie chart shows the responses about the general sensation of the anterior two thirds of the tongue. Cadet blue indicates glossopharyngeal nerve, dark green indicates trigeminal nerve and violet indicates facial nerve. Majority 57.4% of the population (glossopharyngeal nerve) were aware that, at the anterior two thirds of the tongue general sensation is sensed whereas 12.87% (cranial nerve), 29.70% (trigeminal nerve) of the population weren't aware about the nerve supply of anterior two-third of tongue.

**Which of the do you think supplies blood to the tongue primarily receives blood supply from**

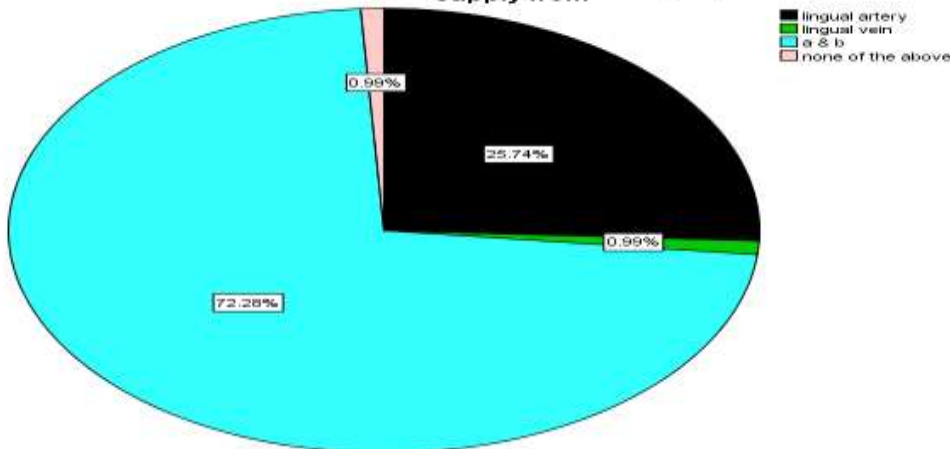


Figure 5 : pie chart shows the responses for blood supply to the tongue from. Black indicates lingual artery , light green indicates lingual vein I. Aqua blue indicates both lingual vein and lingual artery and baby pink indicates none of the above.Majority 72.2% of the population (both a and b )were aware whereas 0.99% ( lingual vein) , 25.74% ( lingual artery) and 0.99% ( none of these) of the population were not aware about the blood supply of tongue.

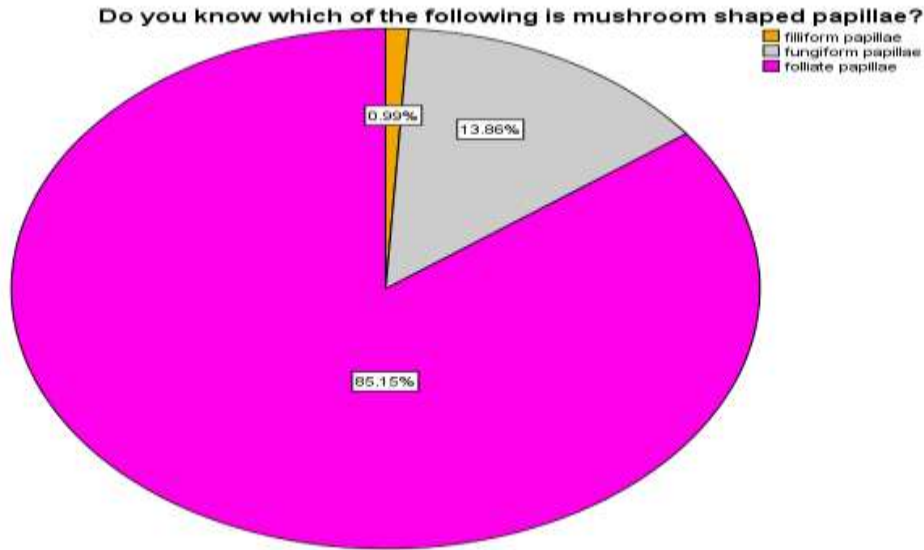


Figure 6 : Pie chart shows the responses for mushroom shaped papillae. Grey represents fungiform papillae, pink represents foliate papillae and orange represents filiform papillae. Only 13.6% (fungiform papillae) were aware whereas 85.15% (foliate papillae), 13.66% (fungiform papillae), 0.99% (filiform papillae) of the population were not aware about mushroom shaped papillae.

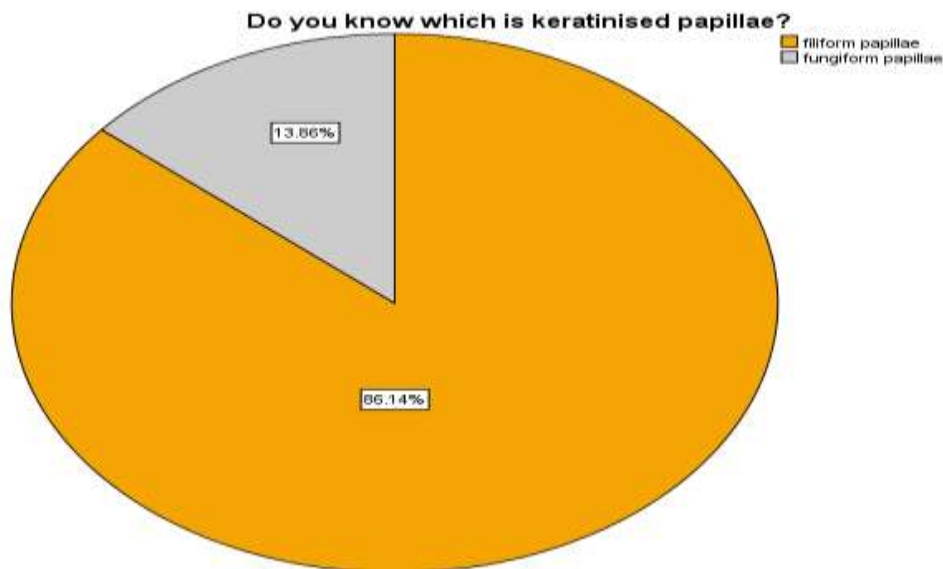


Figure 7: pie chart shows responses of keratinized papillae . Orange represents filiform papillae, grey represents fungiform papillae.Majority 86.1% of the population were aware that filiform papillae is the keratinized papillae whereas 13.8%(fungiform papillae) of the population were not aware about keratinized papillae.

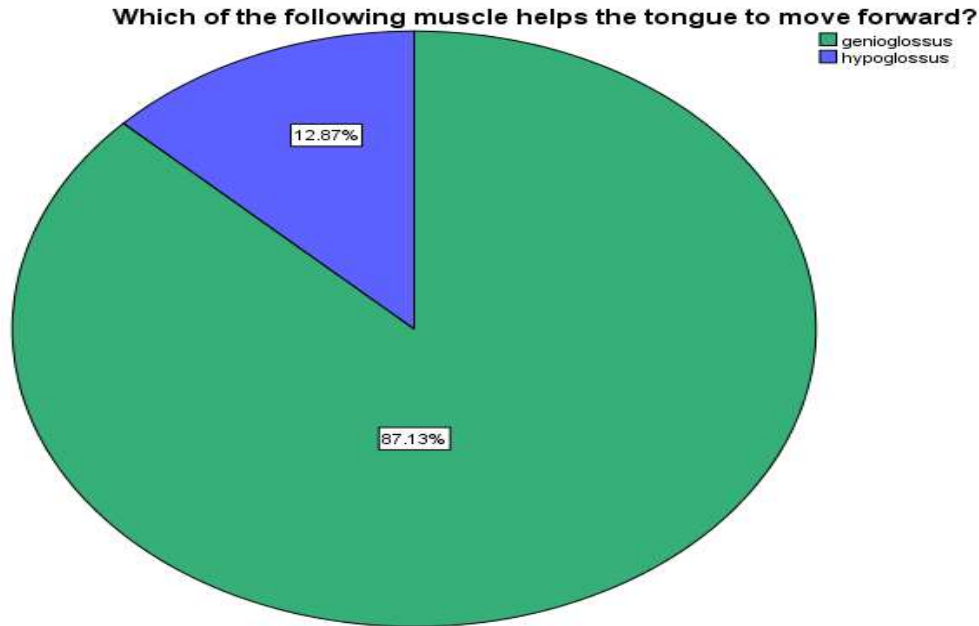


Figure 8: Pie chart shows the responses for movement of tongue muscle. Pine green indicates genioglossus muscle and royal blue represents hyoglossus muscle. Majority 87.13% of the population (genioglossus) were aware of muscle helps in tongue movement whereas 12.9% (hypoglossus) of the population weren't aware about the muscle helps in movement of tongue .



**Do you know from which of the following the anterior two-third of tongue derived from?**

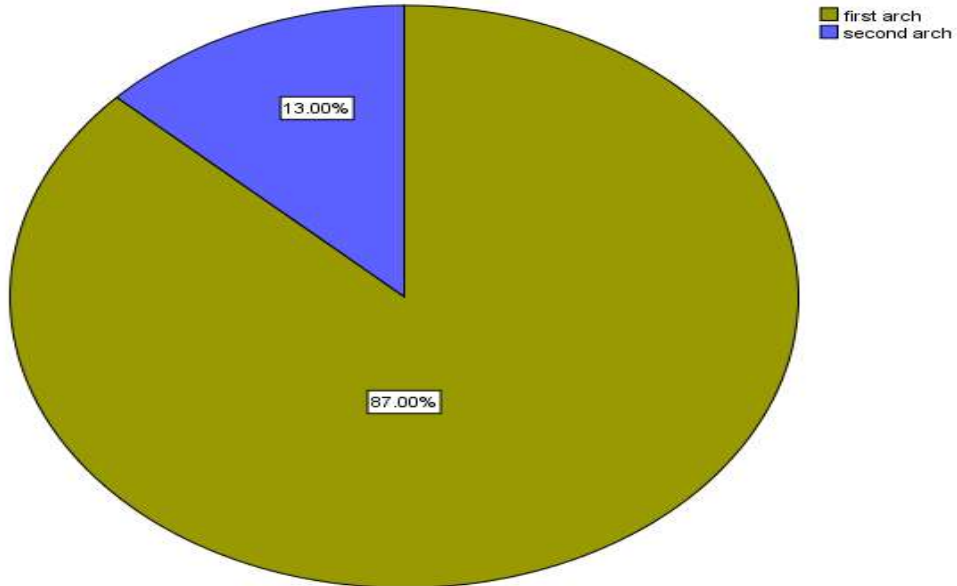


Figure 9: Pie chart shows responses for development of tongue. Olive green indicates first arch and Persian blue represents second arch. Majority 87% of the population (first arch) were aware whereas 13% (second arch) of the population weren't aware about development of tongue.

**Which of the following do you think is the intrinsic muscle of tongue**

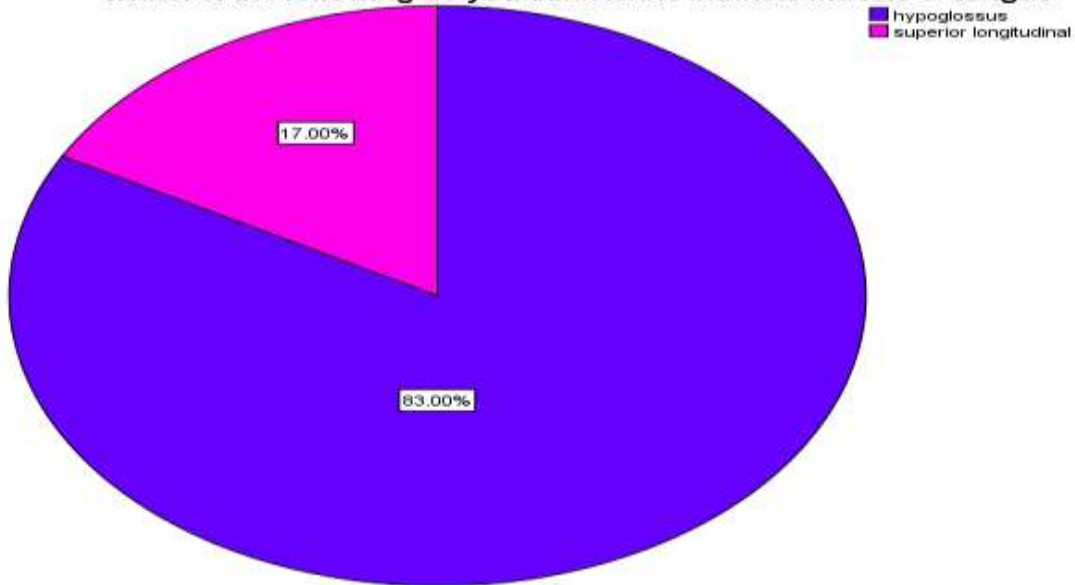


Figure 10 : Pie chart shows the responses on the intrinsic muscle of the tongue. purple represents superior longitudinal,royal blue represents hyoglossus. Majority 83 % (hypoglossus) of the population were not aware that whereas 17%(superior longitudinal) of the population were aware about the intrinsic muscle of the tongue .

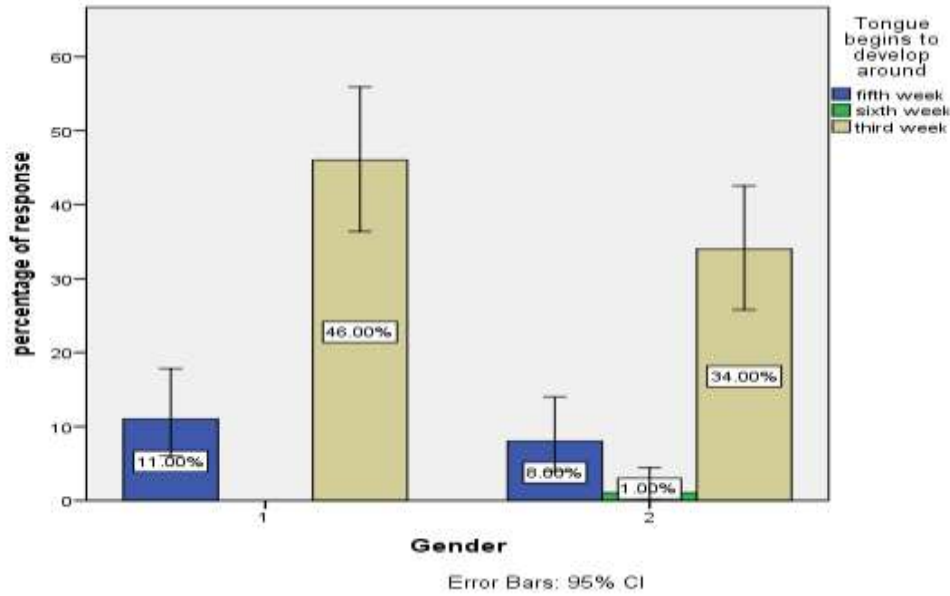


Figure 11: Bar graph depicts the association between gender participated in the study and knowledge about development of tongue. X-axis represents gender population and Y-axis represents percentage of response . Blue denotes fifth week , green denotes the sixth week and grey denotes fourth week. Majority 46% of males were more aware of tongue development than (34%) females. Pearson chi square test shows p value is 0.931,(p value > 0.05). Hence, statistically not significant.

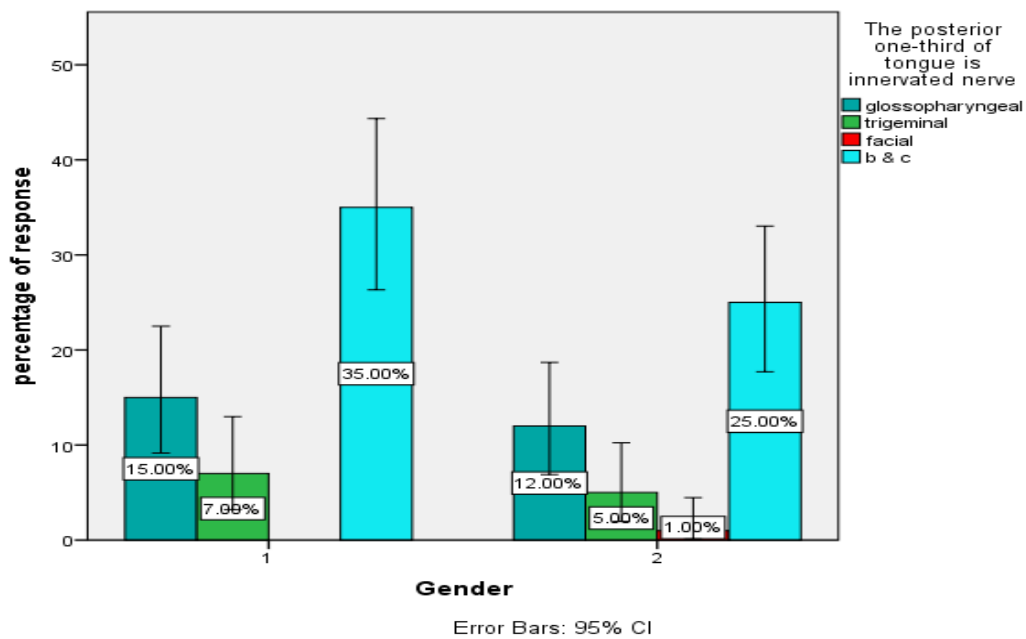


Figure 12 : Bar graph depicts association between gender of participants and knowledge about nerve supply of posterior one-third of tongue. The X-axis represents gender whereas the Y-axis

represents the percentage of response . Cadet Blue denotes glossopharyngeal nerve ,dark green denotes trigeminal nerve and red denotes facial nerve and azure blue denotes both trigeminal and facial nerve. Majority 35% of male were aware of nerves that supply the posterior one third of the tongue than 25% of females. Pearson chi square test shows p value is 0.957, (p value > 0.05). Hence, statistically not significant.

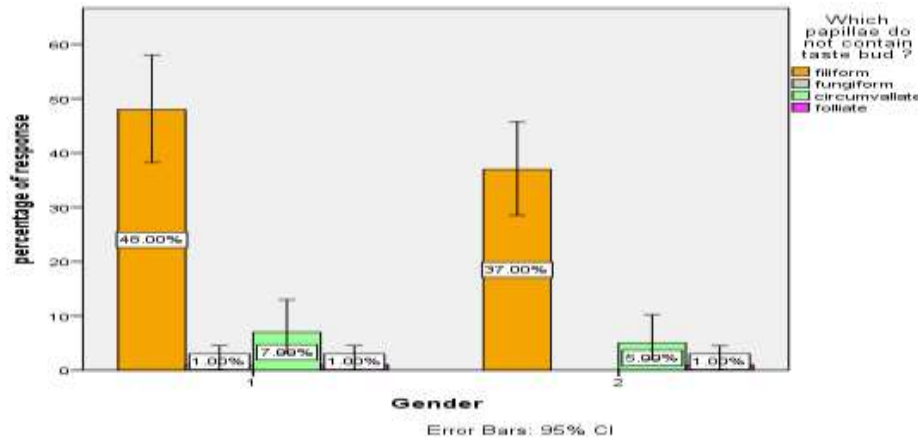


Figure 13 : Bar graph represents association between gender and knowledge about papillae that do not contain taste buds. X-axis represents gender population and Y-axis represents the percentage of response . Orange denotes filiform papillae, grey denotes fungiform papillae, and sky blue denotes circumvallate , pink denotes foliate papillae. Majority (48%) of male were more aware that filiform papillae do not contain taste buds when compared to females (37%). Pearson chi square test shows p value is 0.937, (p value > 0.05). Hence, statistically not significant.

## DISCUSSION:

In our present study, males were 64% and females were 36% . This study found that the majority of the males have adequate knowledge than that of females. And 79.21% of the students were aware that the tongue is about to develop around the fifth week of intrauterine life and 20.8% of them were not aware. Pharyngeal arch is also known as mandibular arch and it is developed in the sixth week. According to our study, the majority (79%) of them were aware that the anterior two-third of tongue is derived from the first arch.

Genioglossus muscle is a paired extrinsic muscle and also helps in attachment of mandibular symphysis and protrusion of tongue. In this study, the majority (87%) of the population were aware that genioglossus muscles help the tongue to move forward. Superior longitudinal muscle arises from fibrous tissue deep to the mucous membrane on the dorsum of tongue (26). In this study, the majority (83%) of them were not aware that superior longitudinal muscle is an intrinsic muscle.

Glossopharyngeal nerve is both sensory and motor nerve. It carries both afferent sensory and efferent motor information. In the present study, the majority (57%) of the population were

aware that general sensation to the anterior one third tongue is sensed by the glossopharyngeal nerve (27). Trigeminal nerve originates at infratemporal fossa, it passes through the oropharyngeal triangle and reaches the oral cavity and it continues as the lingual nerve reaches the submandibular duct, and after looping around it, it descends into the tongue (28,29). In our study, the majority (61%) of the population were aware that trigeminal nerve supplies posterior one third of tongue.

Tongue contains many taste buds and papillae like filiform papillae, fungiform papillae, circumvallate papillae and foliate papillae (30). Filiform papillae are arranged in distinct rows diverging to right and left from the middle line (31). In the present study, the majority (85%) of the population were aware that filiform papillae do not contain any taste buds. Foliate papillae is located on the posterolateral margin of the tongue surface and it is supplied by the facial nerve and glossopharyngeal nerve. In the present study, the majority of the students (85%) were aware that foliate papillae are mushroom shaped and have adequate knowledge regarding papillae.

As per as the responses collected from the survey, majority (86%) of the students were aware that filiform papillae is the only papillae which is keratinised. In this study, the majority of the correct answers were given by male. Thus this study shows males have more knowledge regarding histology of tongue than females and more practices and classes are needed for students to improve their knowledge on histology of tongue.

Simultaneous lectures and slide reading might help them to understand the histology of the tongue in a better way. Also, tongue models to make them visualise the tongue movements, blood supply and nerve supply will make the subject easy to learn and hard to forget. The study has been done on a small scale population involving only 10 questions. This study should be done involving a large population with more questionnaires among various dental colleges for significant results and new findings.

#### **CONCLUSION:**

From the obtained results within the limitations of study, it is concluded that it is important for dental students to know about the tongue and its histology to understand the difference between normal and pathology. This study is done to evaluate knowledge and information about the tongue among dental students and concluded that the participants in the survey have adequate knowledge regarding tongue. However males had answered correctly for most of the questions than females. This study should be conducted in the larger population for the better understanding of the subject among the students.

#### **ACKNOWLEDGMENT:**

The authors would like to thank all the participants for their valuable support and Saveetha Dental College, Saveetha Institute of Medical and Technical Science, Saveetha University for their support to conduct the study.

**CONFLICT OF INTEREST:**

All the authors declare that there was no conflict of interest in present study.

**AUTHORS CONTRIBUTION:**

Ramya Anbu: literature search , data collection, analysis, manuscript drafting.

Dr.Suganya : Data verification , manuscript drafting.

**SOURCE OF FUNDING:**

The present study was supported by the following agencies

- Saveetha Dental College,
- Saveetha Institute of Medical and Technical Science,
- Saveetha University
- Prompt paper products private LTD.,

**REFERENCE:**

1. [No title] [Internet]. [cited 2021 May 27]. Available from:  
<https://pubs.rsna.org/doi/pdf/10.1148/rg.317095738>
2. Abd-el-Malek S. Observations on the morphology of the human tongue. *J Anat.* 1939 Jan;73(Pt 2):201.
3. Khanna AK, Tiwary SK. *Ulcers of the Lower Extremity.* Springer; 2016. 479 p.
4. [No title] [Internet]. [cited 2021 May 31]. Available from: <https://paperpile.com/c/oQo3sT/njGp>
5. Chaurasia BD, Garg K. *Bd Chaurasia's Human Anatomy for Dental Students.* CBS Publishers & Distributors Pvt Limited, India; 2018.
6. Princeton B, Santhakumar P, Prathap L. Awareness on Preventive Measures taken by Health Care Professionals Attending COVID-19 Patients among Dental Students. *Eur J Dent.* 2020 Dec;14(S 01):S105–9.
7. Mathew MG, Samuel SR, Soni AJ, Roopa KB. Evaluation of adhesion of *Streptococcus mutans*, plaque accumulation on zirconia and stainless steel crowns, and surrounding gingival inflammation in primary molars: randomized controlled trial. *Clin Oral Investig.* 2020 Sep;24(9):3275–80.
8. Sridharan G, Ramani P, Patankar S, Vijayaraghavan R. Evaluation of salivary metabolomics in oral leukoplakia and oral squamous cell carcinoma. *J Oral Pathol Med.* 2019 Apr;48(4):299–306.

9. R H, Hannah R, Ramani P, Ramanathan A, Jancy MR, Gheena S, et al. CYP2 C9 polymorphism among patients with oral squamous cell carcinoma and its role in altering the metabolism of benzo[a]pyrene [Internet]. Vol. 130, Oral Surgery, Oral Medicine, Oral Pathology and Oral Radiology. 2020. p. 306–12. Available from: <http://dx.doi.org/10.1016/j.oooo.2020.06.021>
10. Antony JVM, Ramani P, Ramasubramanian A, Sukumaran G. Particle size penetration rate and effects of smoke and smokeless tobacco products - An invitro analysis. *Heliyon*. 2021 Mar 1;7(3):e06455.
11. Sarode SC, Gondivkar S, Sarode GS, Gadbail A, Yuwanati M. Hybrid oral potentially malignant disorder: A neglected fact in oral submucous fibrosis. *Oral Oncol*. 2021 Jun 16;105390.
12. Hannah R, Ramani P, WM Tilakaratne, Sukumaran G, Ramasubramanian A, Krishnan RP. Author response for “Critical appraisal of different triggering pathways for the pathobiology of pemphigus vulgaris—A review” [Internet]. Wiley; 2021. Available from: <https://publons.com/publon/47643844>
13. Chandrasekar R, Chandrasekhar S, Sundari KKS, Ravi P. Development and validation of a formula for objective assessment of cervical vertebral bone age. *Prog Orthod*. 2020 Oct 12;21(1):38.
14. Subramanyam D, Gurunathan D, Gaayathri R, Vishnu Priya V. Comparative evaluation of salivary malondialdehyde levels as a marker of lipid peroxidation in early childhood caries. *Eur J Dent*. 2018 Jan;12(1):67–70.
15. Jeevanandan G, Thomas E. Volumetric analysis of hand, reciprocating and rotary instrumentation techniques in primary molars using spiral computed tomography: An in vitro comparative study. *Eur J Dent*. 2018 Jan;12(1):21–6.
16. Ponnulakshmi R, Shyamaladevi B, Vijayalakshmi P, Selvaraj J. In silico and in vivo analysis to identify the antidiabetic activity of beta sitosterol in adipose tissue of high fat diet and sucrose induced type-2 diabetic experimental rats. *Toxicol Mech Methods*. 2019 May;29(4):276–90.
17. Sundaram R, Nandhakumar E, Haseena Banu H. Hesperidin, a citrus flavonoid ameliorates hyperglycemia by regulating key enzymes of carbohydrate metabolism in streptozotocin-induced diabetic rats. *Toxicol Mech Methods*. 2019 Nov;29(9):644–53.
18. Alsawalha M, Rao CV, Al-Subaie AM, Haque SKM, Veeraraghavan VP, Surapaneni KM. Novel mathematical modelling of Saudi Arabian natural diatomite clay. *Mater Res Express*. 2019 Sep 4;6(10):105531.
19. Yu J, Li M, Zhan D, Shi C, Fang L, Ban C, et al. Inhibitory effects of triterpenoid betulin on inflammatory mediators inducible nitric oxide synthase, cyclooxygenase-2, tumor necrosis factor-alpha, interleukin-6, and proliferating cell nuclear antigen in 1, 2-dimethylhydrazine-induced rat colon carcinogenesis. *Pharmacogn Mag*. 2020;16(72):836.
20. Shree KH, Hema Shree K, Ramani P, Herald Sherlin, Sukumaran G, Jeyaraj G, et al. Saliva as a

- Diagnostic Tool in Oral Squamous Cell Carcinoma – a Systematic Review with Meta Analysis [Internet]. Vol. 25, Pathology & Oncology Research. 2019. p. 447–53. Available from: <http://dx.doi.org/10.1007/s12253-019-00588-2>
21. Zafar A, Sherlin HJ, Jayaraj G, Ramani P, Don KR, Santhanam A. Diagnostic utility of touch imprint cytology for intraoperative assessment of surgical margins and sentinel lymph nodes in oral squamous cell carcinoma patients using four different cytological stains. *Diagn Cytopathol.* 2020 Feb;48(2):101–10.
  22. Karunagaran M, Murali P, Palaniappan V, Sivapathasundharam B. Expression and distribution pattern of podoplanin in oral submucous fibrosis with varying degrees of dysplasia – an immunohistochemical study [Internet]. Vol. 42, *Journal of Histotechnology.* 2019. p. 80–6. Available from: <http://dx.doi.org/10.1080/01478885.2019.1594543>
  23. Sarode SC, Gondivkar S, Gadail A, Sarode GS, Yuwanati M. Oral submucous fibrosis and heterogeneity in outcome measures: a critical viewpoint. *Future Oncol.* 2021 Jun;17(17):2123–6.
  24. Raj Preeth D, Saravanan S, Shairam M, Selvakumar N, Selestin Raja I, Dhanasekaran A, et al. Bioactive Zinc(II) complex incorporated PCL/gelatin electrospun nanofiber enhanced bone tissue regeneration. *Eur J Pharm Sci.* 2021 May 1;160:105768.
  25. Prithviraj N, Yang GE, Thangavelu L, Yan J. Anticancer Compounds From Starfish Regenerating Tissues and Their Antioxidant Properties on Human Oral Epidermoid Carcinoma KB Cells. In: PANCREAS. LIPPINCOTT WILLIAMS & WILKINS TWO COMMERCE SQ, 2001 MARKET ST, PHILADELPHIA ...; 2020. p. 155–6.
  26. [No title] [Internet]. [cited 2021 May 31]. Available from: <https://paperpile.com/c/oQo3sT/AlYV>
  27. Williams DJ, Lane S. Arteritis of the tongue [Internet]. Vol. 43, *Journal of Clinical Pathology.* 1990. p. 349–349. Available from: <http://dx.doi.org/10.1136/jcp.43.4.349-b>
  28. Error - Cookies Turned Off [Internet]. [cited 2021 May 29]. Available from: <https://onlinelibrary.wiley.com/doi/abs/10.1002/ca.21011>
  29. Touré G, Bicchieray L, Selva J, Vacher C. The intra-lingual course of the nerves of the tongue. *Surg Radiol Anat.* 2005 Oct 22;27(4):297–302.
  30. Tang X, Yu J, Li M, Zhan D, Shi C, Fang L, et al. Inhibitory effects of triterpenoid betulin on inflammatory mediators inducible nitric oxide synthase, cyclooxygenase-2, tumor necrosis factor- $\alpha$ , interleukin-6, and proliferating cell nuclear antigen in 1,2-dimethylhydrazine-induced rat colon carcinogenesis [Internet]. Vol. 16, *Pharmacognosy Magazine.* 2020. p. 841. Available from: [http://dx.doi.org/10.4103/pm.pm\\_516\\_19](http://dx.doi.org/10.4103/pm.pm_516_19)
  31. Ozdener MH, Brand JG, Spielman AI, Lischka FW, Teeter JH, Breslin PAS, et al. Characterization of

Human Fungiform Papillae Cells in Culture. *Chem Senses*. 2011 Apr 6;36(7):601–12.

32. Dotiwala A, Samra N. Anatomy, Head and Neck, Tongue. *StatPearls* [Internet]. 2021 [cited 2021 May 27]; Available from: <https://www.statpearls.com/ArticleLibrary/viewarticle/30245>
33. Koplun BS. Prominent pigmented papillae of the tongue [Internet]. Vol. 95, *Archives of Dermatology*. 1967. p. 394–6. Available from: <http://dx.doi.org/10.1001/archderm.95.4.394>