

Knowledge On Tooth Development Among Undergraduates - A Cross-Sectional Survey

A. Annika Rajaselin

Saveetha Dental College and Hospitals,
Saveetha Institute of Medical and Technical Science,
Saveetha University
Chennai- 600077
Tamil Nadu, India
Email: 152001020.sdc@saveetha.com

Dr. R. Priyadharshini

Senior Lecturer
Department of Pathology
Saveetha Institute of Medical and Technical Sciences,
Saveetha University,
Chennai-600077
Email: priyadharshinir.sdc@saveetha.com

Dr. Suganya.P

Senior Lecturer
Department of Oral Pathology
Saveetha Dental College and Hospitals,
Saveetha Institute of Medical and Technical Sciences,
Chennai-600077
Email: Suganyap.sdc@saveetha.com

Abstract

Background : Tooth development is a very complex process involving many growth factors. The morphological stages of tooth development includes bud stage, cap stage, bell stage and advanced bell stage.

Aim: The aim of the present study is to assess the knowledge on tooth development among undergraduates.

Materials and methods : This is a questionnaire based cross sectional study performed among 113 dental UG students in a private dental college. The data was collected and analysed using SPSS software version 23.

Result: In this study, 26% were first year, 31% were second year, 18% were third year, 2% were fourth year and 23% were interns. An association graph was done between the year of study and the number of responses for the question. Majority (23%) were the second years who were aware about the development of teeth when compared to first (19%), third (2%), fourth year (1%) and interns (8%). Pearson chi square test was done and the p value is 0.003 and hence it is statistically significant.

Conclusion: The second year undergraduate dental students had much knowledge about tooth development compared to first, third, fourth and interns. Further reinforcements with activity based learning can establish better knowledge in the subject among undergraduate dental students.

Keywords: tooth development, awareness, stages of tooth development, innovative technology

Introduction

Development of teeth occurs in the 6th week of intrauterine life with the formation of a primary epithelial band which divides into a lingual process called dental lamina and a buccal process called vestibular lamina (1). The odontogenic cells continue to proliferate, forming swellings called enamel organs in areas where teeth are going to form. All deciduous teeth arise from this dental lamina, later the permanent successors arise from its lingual extension and the permanent molars from its distal extension (2). The tooth germ consists of an enamel organ, dental papilla and dental follicle (3). The enamel is formed from the enamel organ, the dentin and pulp from dental papilla and the supporting tissues (cementum, periodontal ligament and the alveolar bone) from the dental follicle (4).

The stages of tooth formation may be classified as the bud, cap and the bell stage based on the shape of the enamel organ (5). The peripheral cuboidal cells that line the convexity of the enamel organ are called the outer enamel epithelium while those lining the inner concavity are called the inner enamel epithelium (6). The star shaped cells in the center forming a network are called stellate reticulum which is a shock absorber (7). The stratum intermedium consists of two or four rows of squamous cells which help in enamel formation (8). The junction of inner and outer enamel epithelium is called the cervical loop which marks the future cemento enamel junction (9).

The commencement of mineralization and root formation occur during the advanced bell stage (10). Hertwig's epithelial root sheath outlines the future root and thus responsible for the shape, length, size and number of roots (11). The development of the roots begins after enamel and dentin formation has reached the cemento enamel junction (12). The outermost dental follicle cells differentiate into osteoblast forms the alveolar bone and the tooth develops within the bony crypt (13). It is necessary for the dental students to know the development of teeth which remains the platform for basic histology (14). Also, our team has extensive knowledge and research experience that has translated into high quality publications (15-31). Thus, the aim of the present study is to assess the knowledge on tooth development among undergraduates.

Materials and methods

A descriptive cross sectional study was done to analyse the knowledge of tooth development among the dental students from a private dental college. A self administered questionnaire consisting 10 questions regarding the tooth development was prepared and distributed among the students through google docs and received 113 responses. The responses were collected and tabulated in the excel sheet and analysed using SPSS version 23 and the results were represented in a pie chart and cross tabs. Chi square test was used to analyze and comparative bar graphs were plotted and it is statistically significant only if the p value is less than 0.05

The questionnaire for the study is below;

1. Which of the following do you think Dental papilla gives rise to?
 - Pulp and periodontal ligament
 - Pulp and dentin
 - Cementum
 - Only dentin

2. Which of the following cells are responsible for the formation of Hertwig's epithelial root sheath?
 - Outer and inner enamel epithelium
 - Stratum intermedium
 - Stellate reticulum
 - Hyaline layer of hopewell smith

3. Signs of developing teeth are seen in which period of the gestation?
 - 2nd week IU
 - 6th week IU
 - 9th week IU

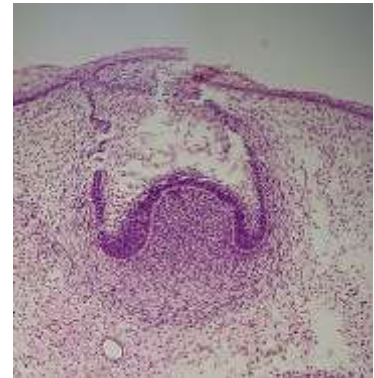
4. Do you know the given image?
 - Cap stage
 - Bell stage
 - Advanced bell stage
 - Bud stage

5. Which of the following remnants are cell rests of malassez?
 - Cervical ameloblasts
 - Root sheath
 - Dental papilla

6. Which of the following are formed from the dental sac?
 - Root sheath
 - Dental pulp
 - Cementum and periodontal ligament
 - Periodontal ligament

7. Dental lamina is active up to which year ?
 - 1 year
 - 3 years
 - 5 years
 - 8 years

8. Which of the following is the main function of ectodermal cells?
 - Determination of shape and crown of root
 - Formation of cementum



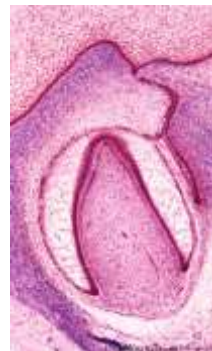- Bud stage
- Formation of enamel

9. Which type of cells forms the enamel?

- Odontoblasts
- Ameloblasts
- Ectodermal cells

10. Can you find the developing stage of the given picture?

- Bell stage
- Cap stage
- Advanced bell stage
- Bud stage



Results

In the present study, the responses were collected from the undergraduate dental students. And 26.55% of the respondents were first year 32.86% of the respondents were second year, 18.58% of the respondents were third years and 18.58% were from fourth year, 20.35% of the respondents were from fifth year (**figure 1**). According to the study, 61.95% of the respondents were aware of dental papilla (**figure 2**). In our study, 52.21% of the respondents were aware about the formation of hertwig's epithelial root sheath (**figure 3**). In our study, 51.33% of the participants were aware about the developing period of the tooth (**figure 4**). According to our study, 63.72% were aware about the cap stage (**figure 5**) and 67.26% of the participants were aware about cell rest of malassez (**figure 6**). In the present study, 60.18% were aware that cementum and periodontal ligament is formed from dental sac (**figure 7**).

In the present study, only 30.97% were aware that dental lamina is active upto 5 years (**figure 8**). In the same study, 60.18% of the participants were aware about the function of ectodermal cells (**figure 9**). In the present study, 87.61% of the participants were aware about the formation of enamel (**figure 10**). Then, 41.59% were aware of the advanced bell stage (**figure 11**). The association between the year of study and the number of responses for the cell layers in Hertwig's epithelial root sheath yields a p value of 0.015 and majority of the second year (20.35%) students were aware that Hertwig's epithelial root sheath is made up of outer and inner enamel epithelium when compared to first (1.77%) third (11.50%) fourth (1.77%) and fifth (7.08%) and it was statistically significant (**figure 12**). The association between the year of study and the number of responses for the period of tooth development in the gestation yields a p value of 0.003 and hence it is statistically significant where the majority of second year students (20.35%) had more knowledge about the developing stage of teeth compared to first (16.81%), third (15.93%), fourth (0.88%) and fifth (13.27%) years of dental students (**figure 13**). The association between the year of study and the percentage of responses for derivatives of cell rests of Malassez is evaluated using Pearson chi square test yields a p value of 0.023 and it is concluded that second year students were aware of cell rest of malassez compared to first, third, fourth and fifth year dental students (**figure 14**).

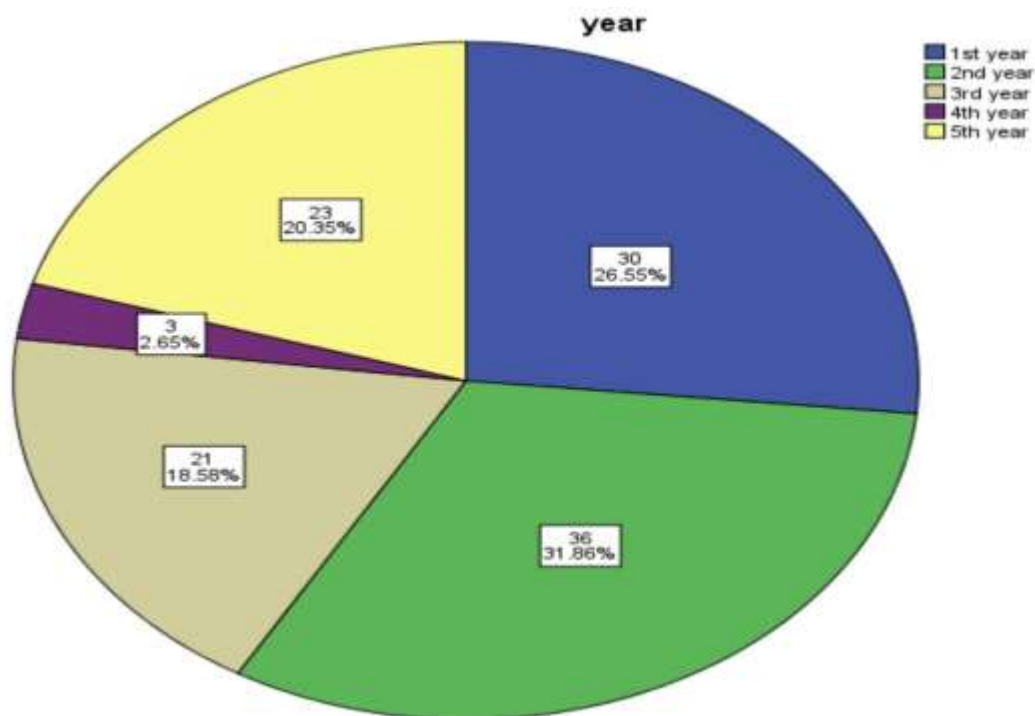


Fig 1. Pie chart depicts the percentage of responses of undergraduate dental students. Blue denotes the percentage of respondents from the first year (30%), green denotes second year (36%), beige denotes third year (21%), purple denotes fourth year (3%), yellow denotes fifth year (23%) respectively. Majority (31.86%) of the participants were from second year, 26.55% were first year, 18.58% were from third year, 2.65% from fourth year and 20.35% were from fifth year.

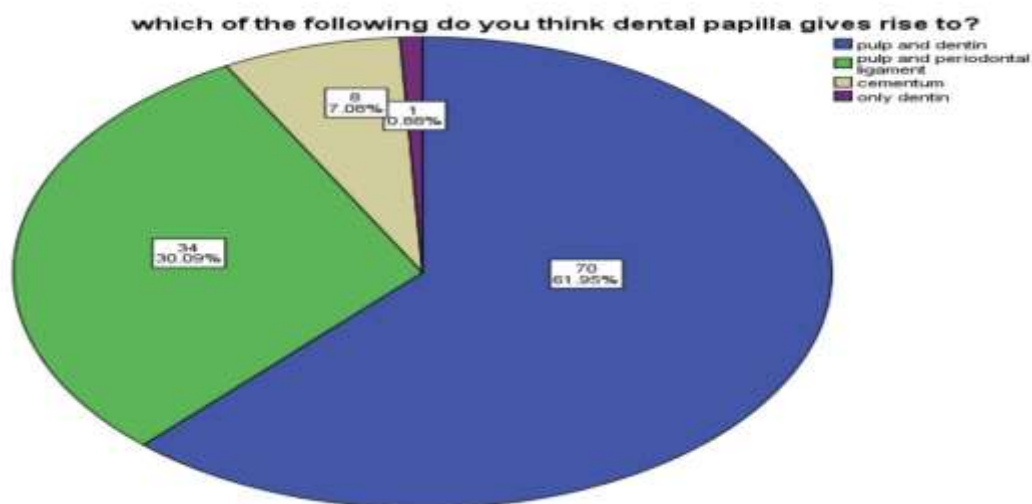


Fig 2. Pie chart represents the percentage of responses for the question about dental papilla. Here blue indicates pulp and periodontal ligament, green indicates pulp and periodontal ligament, purple indicates only dentin, and beige indicates only cementum. Majority (61.95%) of the population were aware, whereas 30.09% (pulp and periodontal ligament), 7.08% (cementum) and 0.88% (only dentin) were unaware about derivatives of dental papilla.

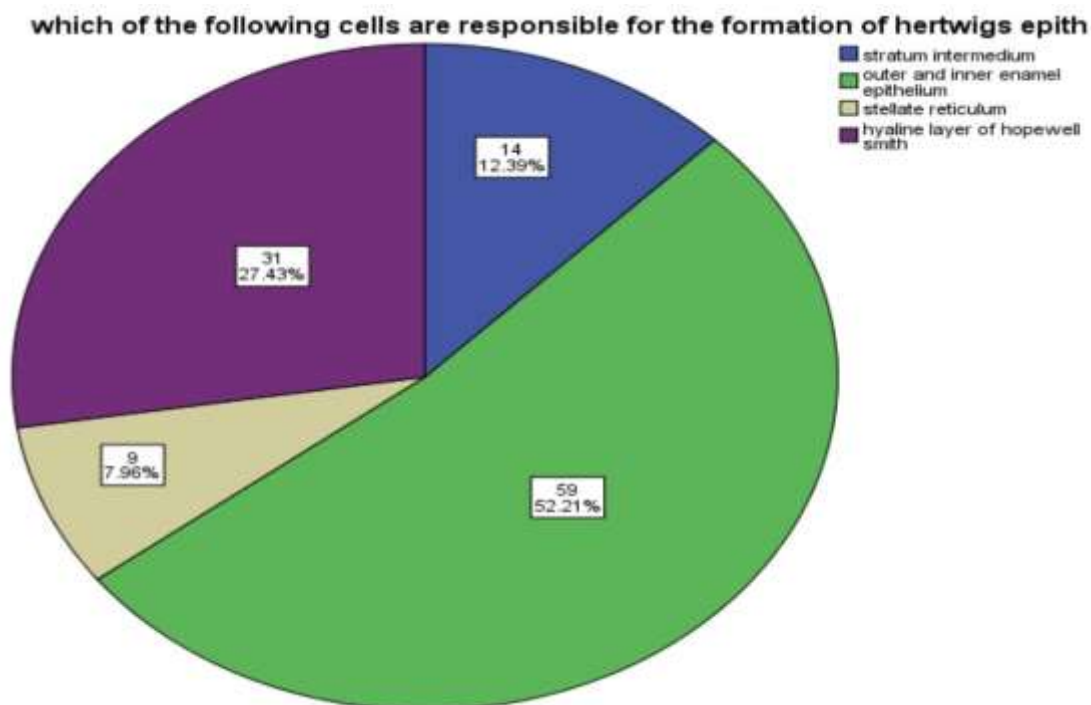


Fig 3. Pie chart represents the percentage of responses regarding the formation of hertwig's epithelial root sheath. Blue indicates stratum intermedium, green indicates outer and inner enamel epithelium, purple indicates hyaline layer of hopewell smith and beige indicates stellate reticulum. Majority (52.21%) of the participants were aware whereas 27.43% (hyaline layer of hopewell smith) , 12.39% (stratum intermedium) and 7.96% (stellate reticulum) were unaware about the formation of root.

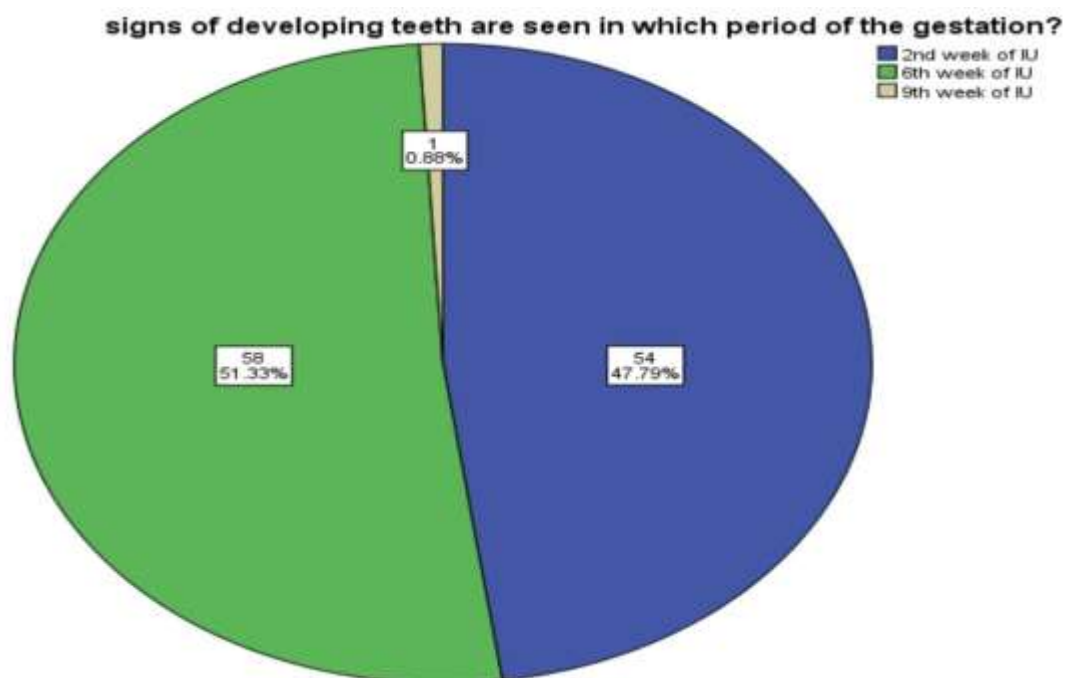


Fig 4. Pie chart represents the percentage of responses regarding the first appearance of teeth. Blue indicates the 2nd week of IU, green indicates the 6th week of IU and beige indicates 9th week of IU. Majority 51.33% of the participants were aware whereas 47.79%

(2nd week of IU), 0.88% (9th week of IU) were unaware about the formation of teeth during gestation.

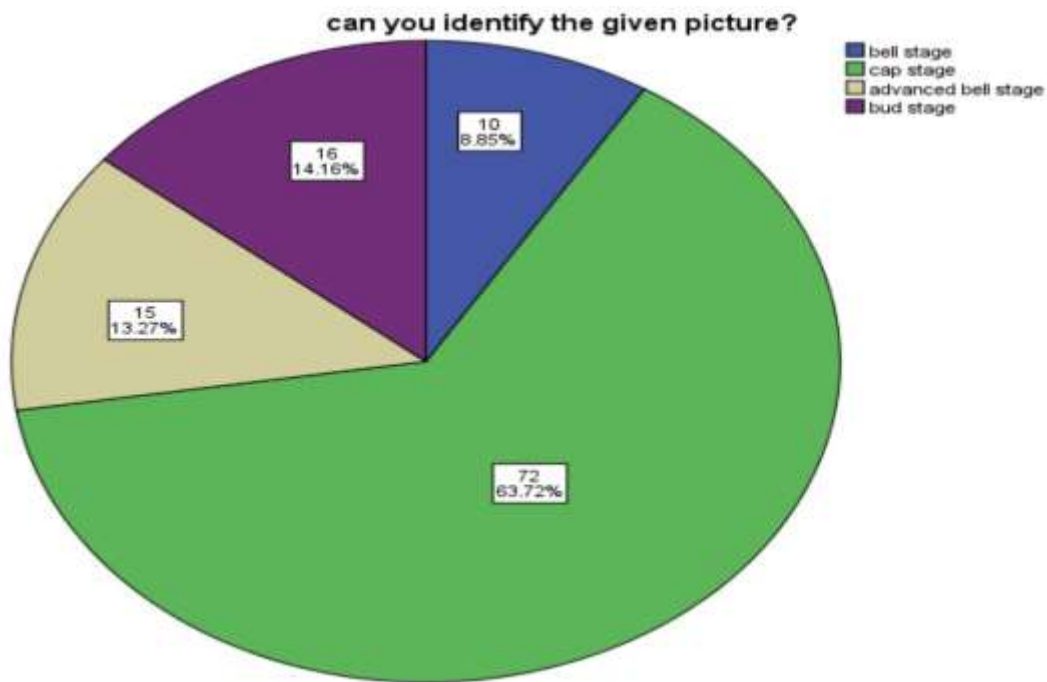


Fig 5. Pie chart represents the percentage of responses for the given picture. Green indicates cap stage, blue indicates the bell stage, purple indicates bud stage and beige indicates advanced bell stage. Majority 63.72% (cap stage) of the participants were aware whereas 14.16% (bud stage), 13.27% (advanced bell stage) and 8.85% (bell stage) were unaware that the given picture was the cap stage of tooth development.

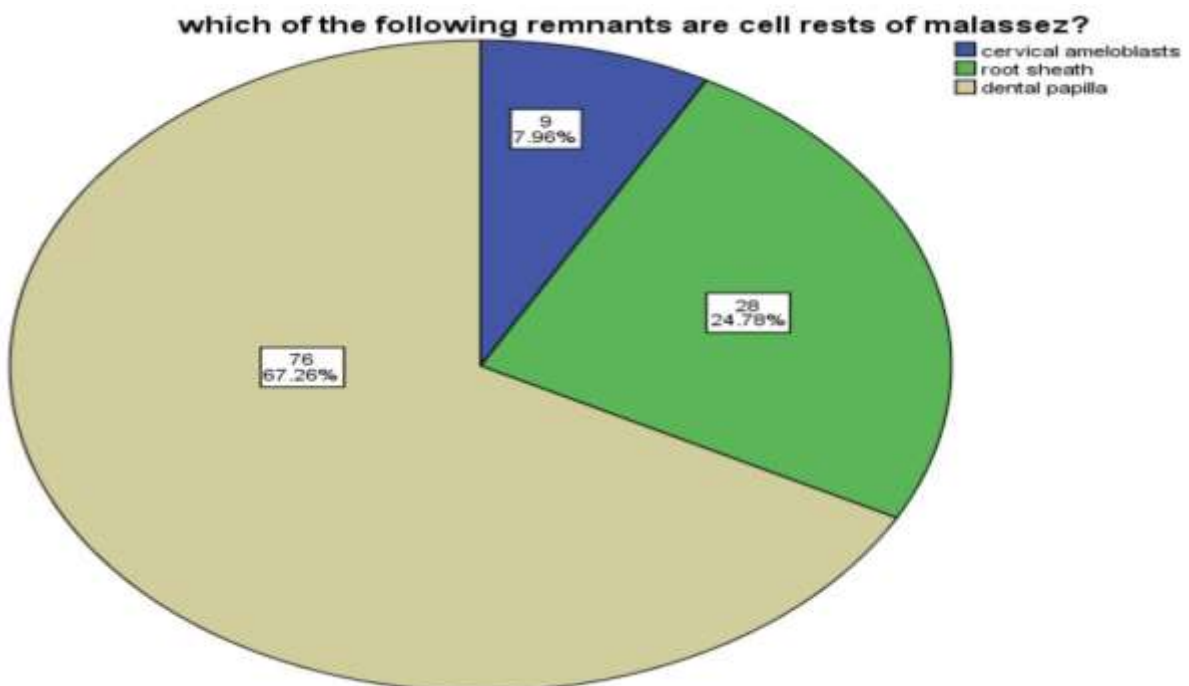


Fig 6. Pie chart shows the percentage of response for the Cell rest of malassez. Beige indicates root sheath, green indicates dental papilla and blue indicates cervical ameloblasts. Majority (67.26%) of

the participants were aware whereas 24.78% (dental papilla) and 7.96% (cervical ameloblasts) were unaware that remnants of Hertwig’s epithelial root sheath are cell rests of Malassez.

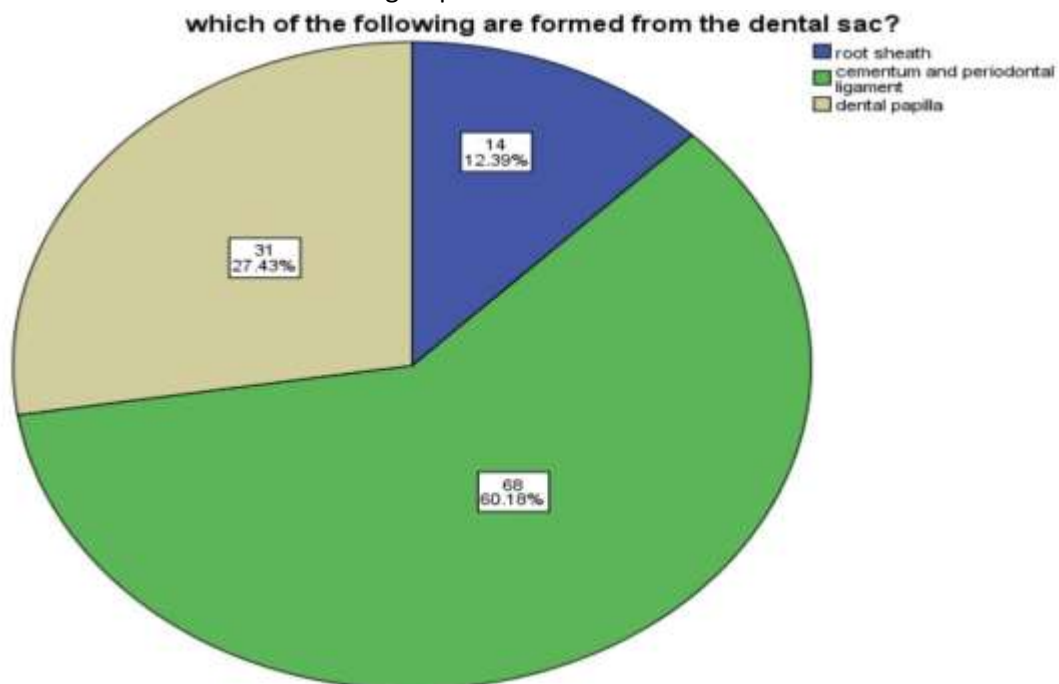


Fig 7. Pie chart shows the percentage of responses for derivatives of Dental sac. Green indicates cementum and periodontal ligament, beige indicates dental papilla and blue indicates root sheath. Majority (60.18%) of the participants were aware whereas 27.43% (dental papilla) and 12.39% (root sheath) were unaware that cementum and periodontal ligament is formed from the dental sac.

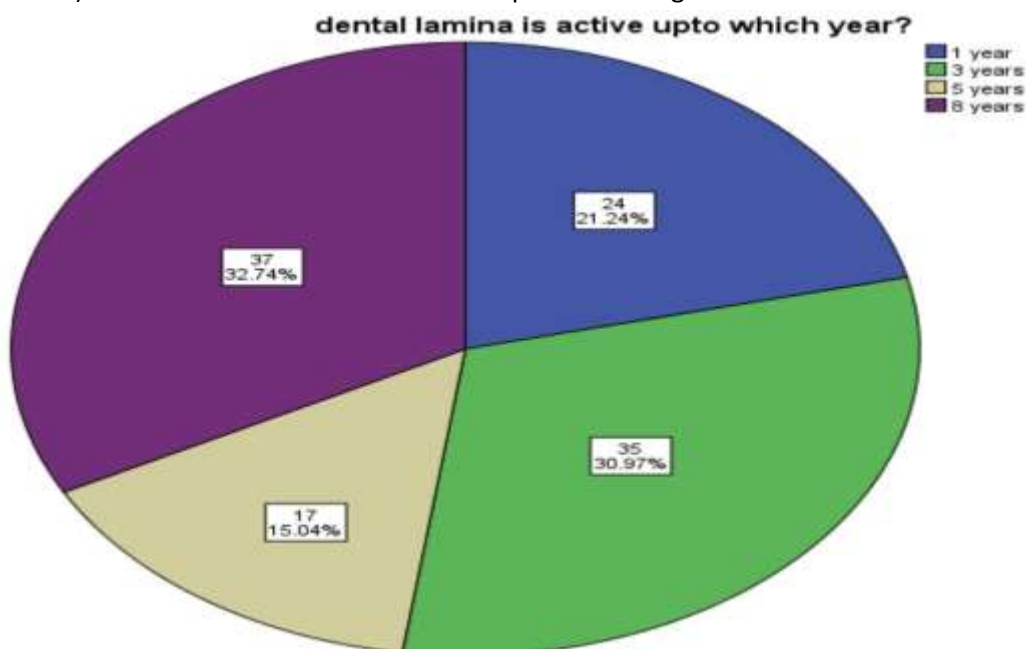


Fig 8. Pie chart shows the percentage of responses for the active period of dental lamina. Blue indicates 1 year, green indicates 3 years, beige indicates 5 years and purple indicates 8 years. Only (30.97%) of the participants were aware whereas 32.74% (8 years), 21.24% (1 year) and 15.04% (5 years) were aware about the active period of dental lamina.

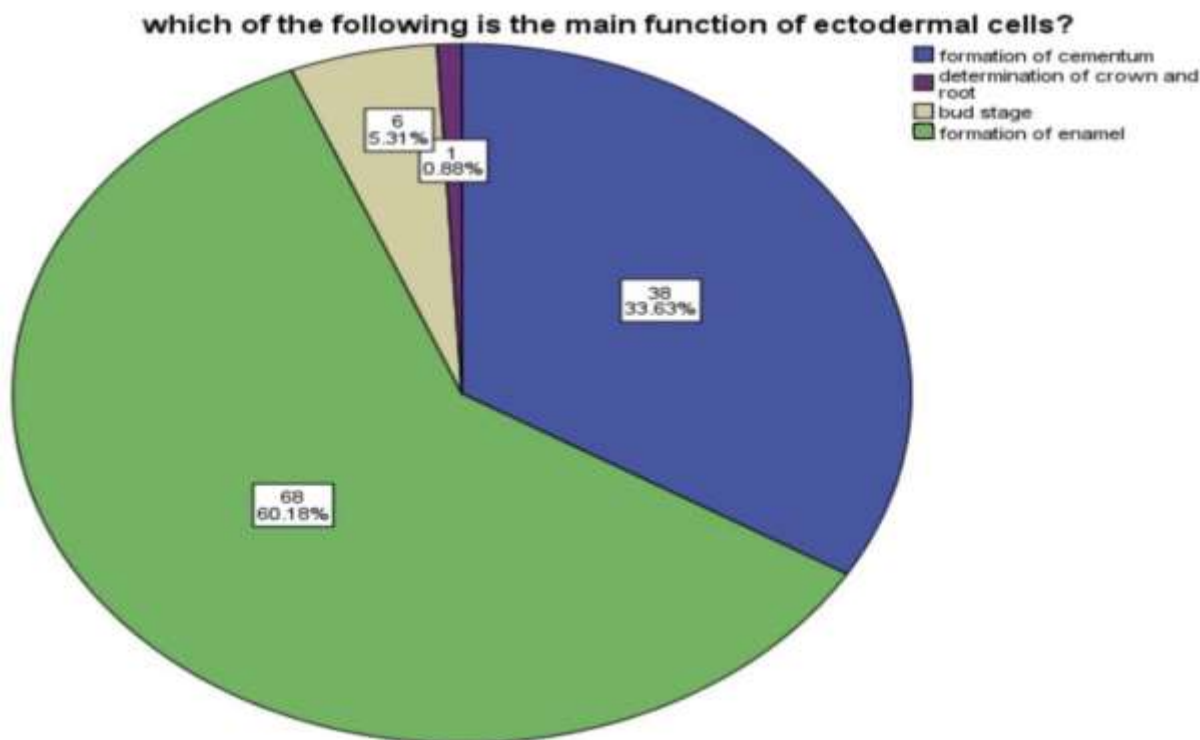


Fig 9. Pie chart shows the percentage of responses for the function of ectodermal cells. Blue indicates formation of cementum, purple indicates determination of crown and root, beige indicates bud stage and green indicates formation of enamel. Majority (60.18%) of the participants were aware whereas 33.63% (formation of cementum), 5.31% (bud stage) and 0.88% (determination of crown and root) were unaware about the function of ectodermal cells.

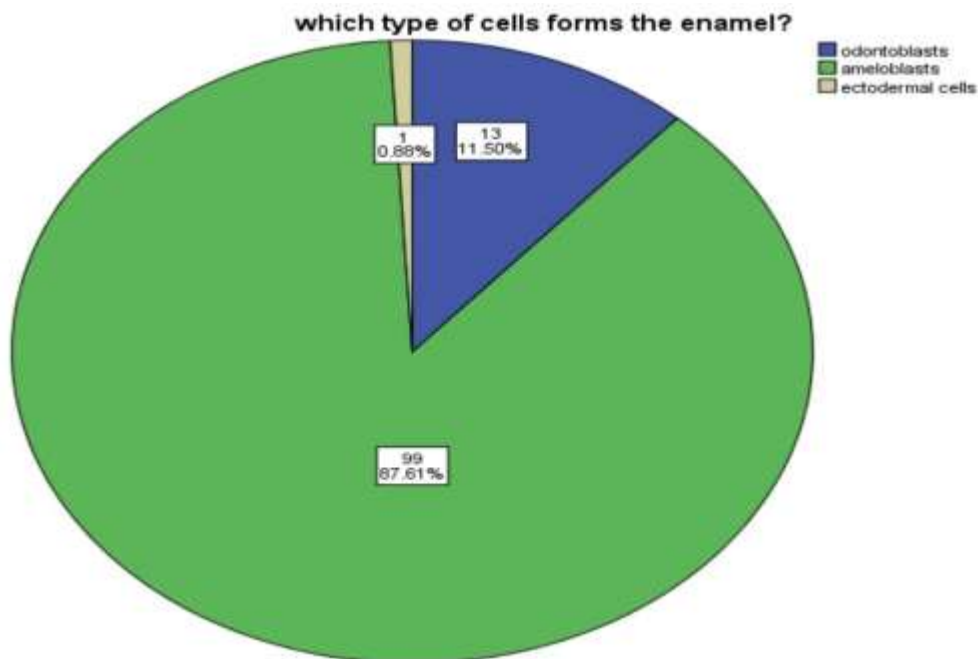


Fig 10. Pie chart shows the percentage of response for cells that form enamel. Green indicates ameloblasts, blue indicates odontoblasts and beige indicates ectodermal cells. Majority (87.61%) of the participants were aware whereas 11.05% (odontoblasts) and 0.88% (ectodermal cells) were not aware about enamel formation.

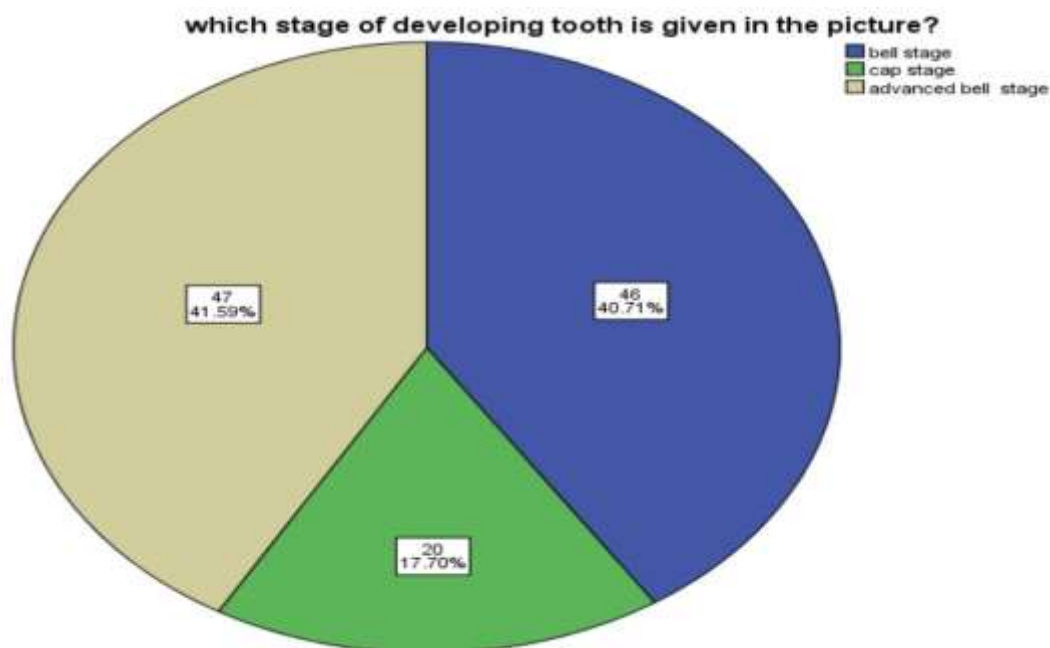


Fig 11. Pie chart shows the percentage of response for the identification of the picture. Blue indicates bell stage, beige indicates bell stage and green indicates cap stage. Majority (41.59%) of the participants were aware whereas 40.71% (bell stage) and 17.70% (cap stage) were unaware that the given picture is an advanced bell stage of tooth development.

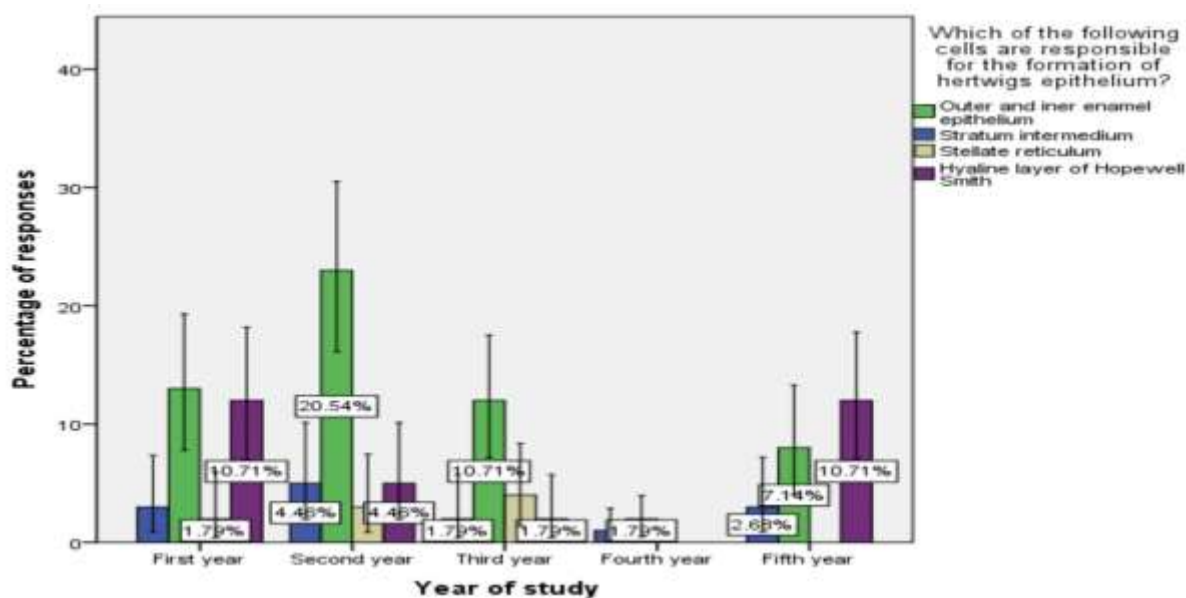


Fig 12. The bar graph depicts the association between the year of study and the number of responses for the cell layers in Hertwig's epithelial root sheath. X- axis represents the year of study and Y- axis represents the percentage of response. Green colour represents outer and inner enamel epithelium, blue colour represents stratum intermedium, beige represents stellate reticulum and purple colour represents the hyaline layer of hopewell smith. Majority of the second year (20.54%) students were aware that Hertwig's epithelial root sheath is made up of outer and inner enamel epithelium when compared to first (1.79%) third (10.71%) fourth (1.79%) and fifth (7.14%). The second year students

had more knowledge about root formation. This difference was statistically significant. (chi square value $p = 0.015$)

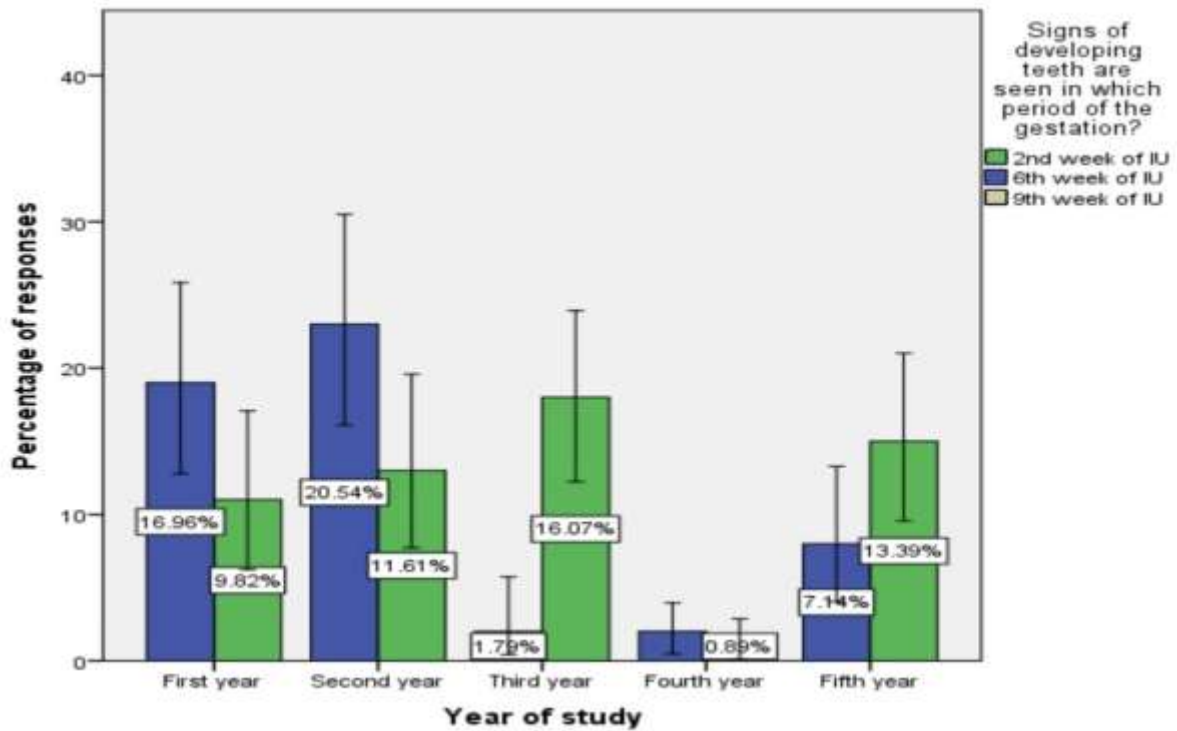


Fig 13. The bar graph depicts the association between the year of study and the number of responses for the period of tooth development in the gestation. The X- axis represents the year of study and the Y- axis represents the percentage of respondents to the question. Green colour represents the 2nd week of IU, blue colour represents the 6th week of IU which is the correct answer, beige colour represents the 9th week of IU. The majority of second year students (20.54%) had more knowledge about the developing stage of teeth compared to first (16.96%), third (1.79%), fourth (0.89%) and fifth (7.14%) years of dental students. The difference was statistically significant (chi square value $p = 0.003$).

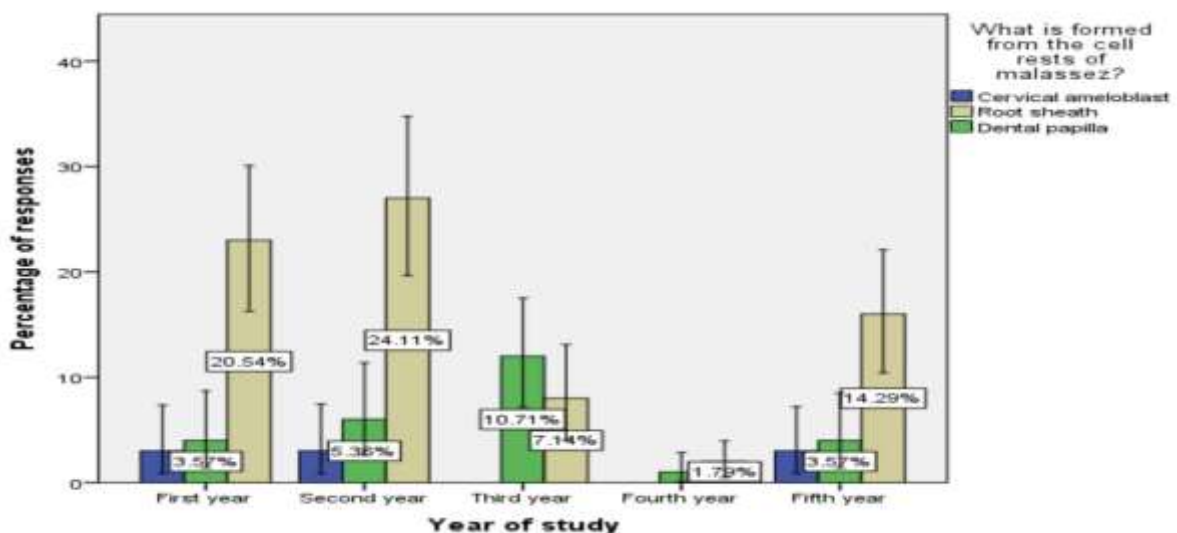


Fig 14. The bar graph depicts the association between the year of study and the percentage of responses for derivatives of cell rests of Malassez. The X-axis represents the year of study and the Y-axis represents the percentage of respondents for derivatives of cell rest of malassez. Blue colour represents cervical ameloblasts, beige colour represents root sheath which is the correct option, green represents the option dental papilla and purple represents enamel. Majority of the second (24.11%) year students had more knowledge regarding the derivatives of cell rests of malassez compared to first (20.54%), third (7.14%), fourth (1.79%) and fifth (14.29%) year dental students. The difference was statistically significant (chi square value $p = 0.023$).

Discussion

In our present study, majority of the second year (20.35%) students were aware that Hertwig's epithelial root sheath is made up of outer and inner enamel epithelium compared to first (1.77%) third (11.50%) fourth (1.77%) and fifth (7.08%). The second year students had more knowledge about root formation. As a result of the current study, it is evident that second year students are more aware of tooth development also the majority of the percentage was observed to be 23.89% for second year students followed by 20.35% of first year students, 7.08% of third year students, 1.77% of fourth year and 14.16% of interns. It is concluded that second year students were aware of cell rest of malassez compared to other years of study.

There are four stages in the development of the tooth germ (15). These stages include Bud stage, Cap stage, advanced bell stage and Late bell stage (16). Cap stage is the second stage of tooth development and it is marked by the growth and expansion of the enamel organ, which results in the formation of a concavity in its inner aspect (17). The inner enamel epithelium cells are columnar in shape and define the shape of the crown and later differentiates into ameloblasts responsible for the formation of enamel (18). The enamel organ has a surrounding fibrous capsule known as the dental follicle, which later forms the periodontal ligament (19). This tooth germ is further developed than those seen in the preceding images (20). The cells in the cervical loop area proliferate causing the rim of the cap to grow deeper into the connective tissue (21). This transforms the shape of the dental organ from a cap to a bell (22). The tooth germ in the given picture is considered to be the advanced bell stage. The picture shows the increase in intercellular material in the stellate reticulum and the elongation of the IDE cells into columnar cells. In the present study, 63.72% and 41.59% of the participants were aware about the cap and advanced bell stage of tooth development (23).

The primitive dental sac, or dental follicle, which originates from odontogenic ectomesenchyme, is part of the tooth germ and is physiologically involved in the formation of cementum, periodontal ligament, and alveolar bone (24). It radiographically appears as thin pericoronal radiolucency, considered normal by some authors when within 3 mm of thickness and by others when it is within 2.5mm of thickness (25). In the present study, 60.18% of the participants were aware that cementum and periodontal ligament is formed from the dental sac.

Hertwig's epithelial root sheath is a bilayer sheath originating from the apical region of enamel organ (26). It is important in guiding tooth root formation by differentiating into cementoblasts through epithelial-mesenchymal transition (EMT) and inducing odontoblastic differentiation of dental

papilla through epithelial–mesenchymal interaction (EMI) during the tooth root development (27). Thus, HERS cells are critical for cementum and dentin formation and might be a potential cell source to achieve tooth root regeneration (28). In the present study, 52.21% of the participants were aware that outer and inner enamel epithelium forms the Hertwig's epithelial root sheath.

The epithelial cell rests of Malassez are resulting from cell fragmentation of the Hertwig epithelial root sheath (HERS), an apical extent of internal and external epithelial enamel, which stimulates the differentiation of ectomesenchymal cells into odontoblasts, secreting root dentin (29). Malassez was the first to detail the histological characteristics of epithelial rests and their distribution in the periodontal ligament (30). In longitudinal and transverse slices of human specimens, Malassez noted the presence of epithelial cells that persisted around the roots (31). After the first descriptions made by Malassez, other authors described the distribution of ERM and its relation to the dental element in a more detailed manner. These structures thus came to be known as the "epithelial rests of Malassez", receiving the eponymous name of its principal investigator (32). In the present study, 67.26% of the participants were aware that cell rests of Malassez are the remnants of root sheath. The sample size was small and more sample size would be beneficial to assess the knowledge about development of teeth more accurately. The survey can be conducted in offline mode rather than online so that the knowledge of the subjects could be analysed accurately. Equal number of male and female samples can be evaluated without difficulty.

Conclusion

The present study assessed good knowledge among dental students about various stages and formation of teeth. The second year undergraduate dental students had much knowledge about tooth development compared to first, second, third, fourth and fifth year students. Further reinforcements with activity based learning can establish better knowledge in the subject among undergraduate dental students.

ACKNOWLEDGEMENT:

The authors would like to thank the study participants for their participation for their kind cooperation throughout the study and Saveetha Dental College, Saveetha Institute of Medical and Technical Science, Saveetha University to conduct the study.

CONFLICTS OF INTEREST:

The authors declare that there are no conflicts of interest in the present study

SOURCE OF FUNDING:

The present study was supported by the following agencies

- Saveetha Dental College,
- Saveetha Institute of Medical and Technical Science,
- Saveetha University.
- Dhanalakshmi Multispeciality Dental Clinic.

Reference

1. Yu T, Klein OD. Molecular and cellular mechanisms of tooth development, homeostasis and repair. *Development* [Internet]. 2020 Jan 15 [cited 2021 Mar 10];147(2). Available from:

<https://dev.biologists.org/content/147/2/dev184754.abstract>

2. Princeton B, Santhakumar P, Prathap L. Awareness on Preventive Measures taken by Health Care Professionals Attending COVID-19 Patients among Dental Students. *Eur J Dent*. 2020 Dec;14(S 01):S105–9.
3. Mathew MG, Samuel SR, Soni AJ, Roopa KB. Evaluation of adhesion of *Streptococcus mutans*, plaque accumulation on zirconia and stainless steel crowns, and surrounding gingival inflammation in primary molars: randomized controlled trial. *Clin Oral Investig*. 2020 Sep;24(9):3275–80.
4. Chen Y, Bei M, Woo I, Satokata I, Maas R. Msx1 controls inductive signaling in mammalian tooth morphogenesis. *Development*. 1996 Oct;122(10):3035–44.
5. Ahn Y. Signaling in Tooth, Hair, and Mammary Placodes [Internet]. *Current Topics in Developmental Biology*. 2015. p. 421–59. Available from: <http://dx.doi.org/10.1016/bs.ctdb.2014.11.013>
6. Sridharan G, Ramani P, Patankar S, Vijayaraghavan R. Evaluation of salivary metabolomics in oral leukoplakia and oral squamous cell carcinoma. *J Oral Pathol Med*. 2019 Apr;48(4):299–306.
7. Harada H, Kettunen P, Jung H-S, Mustonen T, Alan Wang Y, Thesleff I. Localization of Putative Stem Cells in Dental Epithelium and Their Association with Notch and Fgf Signaling [Internet]. Vol. 147, *Journal of Cell Biology*. 1999. p. 105–20. Available from: <http://dx.doi.org/10.1083/jcb.147.1.105>
8. Tummers M, Thesleff I. The importance of signal pathway modulation in all aspects of tooth development [Internet]. Vol. 312B, *Journal of Experimental Zoology Part B: Molecular and Developmental Evolution*. 2009. p. 309–19. Available from: <http://dx.doi.org/10.1002/jez.b.21280>
9. Website [Internet]. Available from: R H, Hannah R, Ramani P, Ramanathan A, Jancy MR, Gheena S, et al. CYP2 C9 polymorphism among patients with oral squamous cell carcinoma and its role in altering the metabolism of benzo[a]pyrene [Internet]. Vol. 130, *Oral Surgery, Oral Medicine, Oral Pathology and Oral Radiology*. 2020. p. 306–12. Available from: <http://dx.doi.org/10.1016/j.oooo.2020.06.021>
10. Antony JVM, Ramani P, Ramasubramanian A, Sukumaran G. Particle size penetration rate and effects of smoke and smokeless tobacco products - An invitro analysis. *Heliyon*. 2021 Mar;7(3):e06455.
11. Sarode SC, Gondivkar S, Sarode GS, Gadbail A, Yuwanati M. Hybrid oral potentially malignant disorder: A neglected fact in oral submucous fibrosis. *Oral Oncol*. 2021 Jun 16;105390.
12. Chandrasekar R, Chandrasekhar S, Sundari KKS, Ravi P. Development and validation of a formula for objective assessment of cervical vertebral bone age. *Prog Orthod*. 2020 Oct 12;21(1):38.
13. Subramanyam D, Gurunathan D, Gaayathri R, Vishnu Priya V. Comparative evaluation of salivary

- malondialdehyde levels as a marker of lipid peroxidation in early childhood caries. *Eur J Dent.* 2018 Jan;12(1):67–70.
14. Jeevanandan G, Thomas E. Volumetric analysis of hand, reciprocating and rotary instrumentation techniques in primary molars using spiral computed tomography: An in vitro comparative study [Internet]. Vol. 12, *European Journal of Dentistry*. 2018. p. 021–6. Available from: http://dx.doi.org/10.4103/ejd.ejd_247_17
 15. Sundaram R, Nandhakumar E, Haseena Banu H. Hesperidin, a citrus flavonoid ameliorates hyperglycemia by regulating key enzymes of carbohydrate metabolism in streptozotocin-induced diabetic rats. *Toxicol Mech Methods*. 2019 Nov;29(9):644–53.
 16. Ponnulakshmi R, Shyamaladevi B, Vijayalakshmi P, Selvaraj J. In silico and in vivo analysis to identify the antidiabetic activity of beta sitosterol in adipose tissue of high fat diet and sucrose induced type-2 diabetic experimental rats. *Toxicol Mech Methods*. 2019 May;29(4):276–90.
 17. Farooqi AA, Ismail M. *Molecular Oncology: Underlying Mechanisms and Translational Advancements*. Springer; 2017. 302 p.
 18. Shree KH, Hema Shree K, Ramani P, Herald Sherlin, Sukumaran G, Jeyaraj G, et al. Saliva as a Diagnostic Tool in Oral Squamous Cell Carcinoma – a Systematic Review with Meta Analysis [Internet]. Vol. 25, *Pathology & Oncology Research*. 2019. p. 447–53. Available from: <http://dx.doi.org/10.1007/s12253-019-00588-2>
 19. Jheon AH, Seidel K, Biehs B, Klein OD. From molecules to mastication: the development and evolution of teeth [Internet]. Vol. 2, *Wiley Interdisciplinary Reviews: Developmental Biology*. 2013. p. 165–82. Available from: <http://dx.doi.org/10.1002/wdev.63>
 20. Zafar A, Sherlin HJ, Jayaraj G, Ramani P, Don KR, Santhanam A. Diagnostic utility of touch imprint cytology for intraoperative assessment of surgical margins and sentinel lymph nodes in oral squamous cell carcinoma patients using four different cytological stains. *Diagn Cytopathol*. 2020 Feb;48(2):101–10.
 21. Sivapathasundharam B. *Textbook of Oral Embryology & Histology*. Jaypee Brothers Medical Publishers; 2018. 370 p.
 22. Sarode SC, Gondivkar S, Gadail A, Sarode GS, Yuwanati M. Oral submucous fibrosis and heterogeneity in outcome measures: a critical viewpoint. *Future Oncol*. 2021 Jun;17(17):2123–6.
 23. Alsawalha M, Rao CV, Al-Subaie AM, Haque SKM, Veeraraghavan VP, Surapaneni KM. Novel mathematical modelling of Saudi Arabian natural diatomite clay [Internet]. Vol. 6, *Materials Research Express*. 2019. p. 105531. Available from: <http://dx.doi.org/10.1088/2053-1591/ab2f9b>
 24. Mesgarzadeh A, Esmailzadeh H, Abdolrahimi M, Shahamfar M. Pathosis associated with radiographically normal follicular tissues in third molar impactions: A clinicopathological study [Internet]. Vol. 19, *Indian Journal of Dental Research*. 2008. p. 208. Available from: <http://dx.doi.org/10.4103/0970-9290.42952>

25. Saravana GHL, Subhashraj K. Cystic changes in dental follicle associated with radiographically normal impacted mandibular third molar [Internet]. Vol. 46, *British Journal of Oral and Maxillofacial Surgery*. 2008. p. 552–3. Available from: <http://dx.doi.org/10.1016/j.bjoms.2008.02.008>
26. Sonoyama W, Seo B-M, Yamaza T, Shi S. Human Hertwig's Epithelial Root Sheath Cells Play Crucial Roles in Cementum Formation [Internet]. Vol. 86, *Journal of Dental Research*. 2007. p. 594–9. Available from: <http://dx.doi.org/10.1177/154405910708600703>
27. Myers J. *Oral Cancer Metastasis*. Springer Science & Business Media; 2009. 346 p.
28. Volponi AA, Pang Y, Sharpe PT. Stem cell-based biological tooth repair and regeneration [Internet]. Vol. 20, *Trends in Cell Biology*. 2010. p. 715–22. Available from: <http://dx.doi.org/10.1016/j.tcb.2010.09.012>
29. Legros C, Dean MS, Magitot E. The origin and formation of the dental follicle. The first memoir on the development of the teeth. By Drs. Ch. Legros and E. Magitot. A translation from the French, with introduction and notes, by M.S. Dean. Authorized and rev. by Dr. Magitot, the surviving author [Internet]. 1880. Available from: <http://dx.doi.org/10.5962/bhl.title.43994>
30. Xiong J, Mroziak K, Gronthos S, Mark Bartold P. Epithelial Cell Rests of Malassez Contain Unique Stem Cell Populations Capable of Undergoing Epithelial–Mesenchymal Transition [Internet]. Vol. 21, *Stem Cells and Development*. 2012. p. 2012–25. Available from: <http://dx.doi.org/10.1089/scd.2011.0471>
31. Raj Preeth D, Saravanan S, Shairam M, Selvakumar N, Selestina Raja I, Dhanasekaran A, et al. Bioactive Zinc(II) complex incorporated PCL/gelatin electrospun nanofiber enhanced bone tissue regeneration. *Eur J Pharm Sci*. 2021 May 1;160:105768.
32. Becktor KB, Nolting D, Becktor JP, Kjaer I. Immunohistochemical localization of epithelial rests of Malassez in human periodontal membrane [Internet]. Vol. 29, *The European Journal of Orthodontics*. 2007. p. 350–3. Available from: <http://dx.doi.org/10.1093/ejo/cjm023>