

Comparison Of InterCanthal Distance Between Different Genders.

Fathima Hinaz.Z, Dr. Gheena S, Dr. Sandhya

1 Saveetha Dental College and Hospitals,
Saveetha Institute of Medical and Technical Sciences (SIMATS),
Saveetha University,
Chennai – 600077
Tamil Nadu, India
Email ID: 152001081.sdc@saveetha.com

2 Professor,
Department of Oral Pathology,
Saveetha Dental College and Hospitals,
Saveetha Institute of Medical and Technical sciences (SIMATS),
Saveetha University,
Chennai – 600077
Tamil Nadu, India
Email ID: gheena@saveetha.com

3 Senior lecturer,
Department of Dental Anatomy,
Saveetha Dental College and Hospitals,
Saveetha Institute of Medical and Technical sciences (SIMATS),
Saveetha University,
Chennai – 600077
Tamil Nadu, India
Email ID: sandhyas.sdc@saveetha.com

Abstract

BACKGROUND: The face is considered to be the most attractive and appealing part of the human body therefore this intercanthal measurement also serves as an important parameter in understanding and diagnosing various facial complications.

AIM:

The aim of the study is to evaluate and compare the mean intercanthal distance in males and females of chennai population.

MATERIALS AND METHODS: This cross-sectional study was conducted among the undergraduate students of a private dental college in chennai. InterCanthal distance was measured among the study population using digital vernier calipers. The data collected were tabulated and analysed with Pearson's chi-square tests for correlating between the two groups and t-test for equality of means, using IBM SPSS software, version 21.81.

RESULTS: The study consisted of 100 participants. The mean intercanthal distance of the study samples was $21.78 \pm$. The mean intercanthal distance of male participants was (21.81 ± 1.96) and that of female participants was (21.69 ± 4.86) . The significant difference between the groups were statistically insignificant (chi-square, p value =0.84)

CONCLUSION:

The study infers that there exists greater Intercanthal distance in Males compared to that in females. Normal canthal values can function as a guide for the diagnosis of pathology and interventions for craniofacial abnormalities. The Intercanthal distance becomes the single major criteria for aesthetic selection of teeth and their arrangement.

KEYWORDS: Intercanthal distance, Diagnosis, Dysmorphic syndrome, Implications, cosmetic surgery, Novel analysis.

Running title: Gender based comparison of intercanthal distance

Introduction:

The face is the most attractive and appealing part of the human body; it influences visual judgement of a person(1). Knowledge of variation in the morphological and anatomical relationships of periorbital structures among different ethnic groups helps the surgeons to retain the ethical features and to derive an ideal outcome in the reconstructive and cosmetic surgeries(2). Even though the constant relation of golden proportion and inner canthal distance (ICD) with the width of the maxillary central incisor (CIW) has been found in European population, it may not be applied to Indian population as we differ from Europeans racially and genetically (3) (4),(5),(6),(7),(8),(9)

Various anatomical measurements have been suggested, such as intercanthal distance, interpupillary distance, outer-canthal distance, interalar distance, bizygomatic distance, intercommis- sural distance, intercondylar width, and philtrum to overcome these circumstances. All these relations may be used in combination and utilized as reference for deter- mining the width of the maxillary anteriors, although the measurements may be different considering race and gender differences (3)(10),(11),(12),(13),(14) Anthropometry is a branch of anthropology, which is all about measuring human physical dimensions(15). Measuring soft tissue with the help of anthropometric instruments is one of the direct quantitative methods that can help in assessing the physical dimensions and this method is also considered to be non-invasive and it is also easy to perform(16),(17),(18),(19),(20),(21),(22). The canthal distance is of two types: the inner inter-cancel distance ICD and the outer canthal distance OCD. The inner intercanthal distance is the distance between medial canthus of eyes and the outer canthal distance is the distance between lateral Canthi of eyes(23). Normal values of canthal distances can help in various diagnostic purposes and also help in understanding the pathological studies and the morphological changes.

Abnormalities in intercanthal distance can cause Dysmorphic syndrome, congenital and post traumatic deformities, Ocular hypotelorism, craniosynostosis and various other clinical complications(24). Knowledge on variation in different morphological and anatomical relationships of varied periorbital structures amidst varied ethnic groups helps the surgeons during reconstructive and other cosmetic surgeries(24,25). Varied guidelines have been provided for determining the Width of maxillary anterior teeth, when the records for the pre-extraction is missing or not available these guidelines that we mentioned here also includes canthal distance as a major parameter (26). Variations in these measurements do exist as a result of the changes and variations that persist among different ethnicities age groups and sex((27). We came up with this research, with the objective of comparing the intercanthal distance within the two genders in the normal South Indian population.

Materials and methods:

This cross-sectional study was conducted in February 2021 and was carried out in the study population. The research was SRB approved. The sample size was 100. The study selected a population among the undergraduate students of the Saveetha Dental College, and the sampling was convenient. There was a random selection of students from different batches. All students male and female individuals who are between 17 to 21 years and greater, were eligible for inclusion criteria. The students were informed and voluntary consent was obtained before taking the measurements. The digital vernier caliper was the major instrument used, in few cases the readings were biased due to

non cooperative students. Data was obtained on all the basis of two variables of gender and age group. Then later the data collected was entered and analysed. Levene's test for equality of variances and t-test for equality of means. For the quantitative outcome variables ICD the mean and the standard deviation was obtained using SPSS statistical software. The correlation between male and females was found using a chi-square test, the p value Of <0.05 was considered significant.

Results:

This study consisted of a total of hundred students of which 50 of them were females and 50 of them were males. The overall mean value of the intercanthal distance was found to be 21.78 (Table 1). The mean value of the inter-canthal distance for males was found to be 21.81, whereas for the females it was found to be 21.69 (Table 2). The standard deviation for the intercanthal distance amongst females was found to be 4.86, whereas for males it was found to be 1.97 (Table 1). The P value was found to be 0.84 >0.05 (Figure 1), and therefore there was no significant difference in the intercanthal distance among males and females of the study population.

TABLE 1: One-sample statistics revealed overall mean value of 21.78 and a standard deviation of 2.94

	N	MEAN	Std.Deviation
Intercanthal distance	100	21.7856	2.94356

TABLE 2: Group statistics provided the mean values of 21.81 and 21.69 for the two groups, males and females respectively and a standard deviation of 4.86 and 1.97 for females and males respectively.

	sex	N	MEAN	Std.Deviation	p-value
Intercanthal distance	females	50	21.69	4.86883	0.84
	males	50	21.81	1.97482	

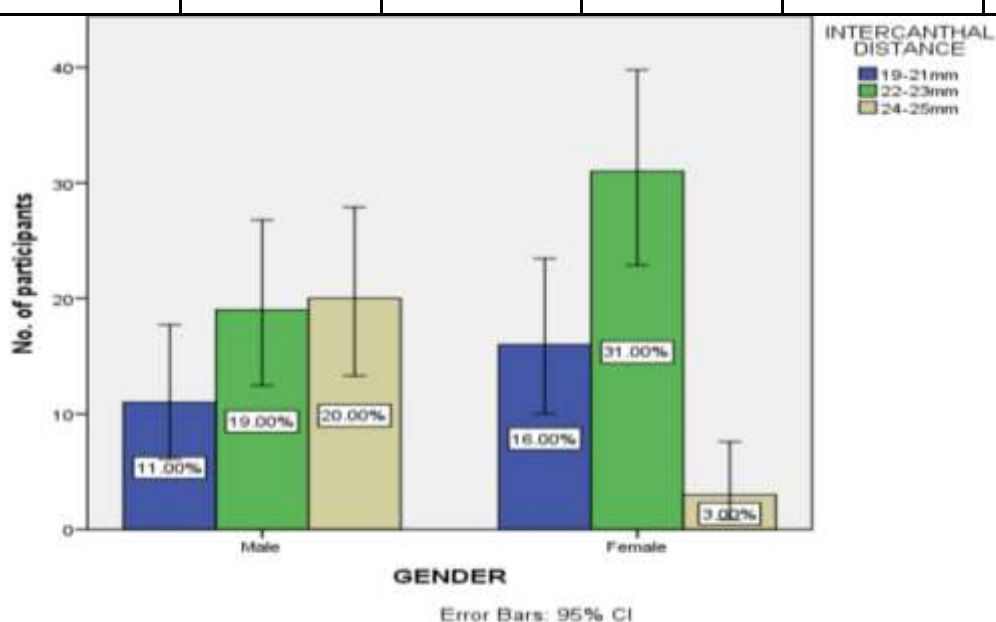


FIGURE 1: This bar graph represents the relation between gender and their intercanthal distance. X axis represents gender and the Y axis represents the number of participants having different

intercanthal distances. Blue colour represents the intercanthal distance of the range 19-21mm , green represents the range of 22-23 mm and yellow represents the range of 24-25 mm. The range of 22-23 mm are predominant in females and a range of 24-25 are predominant in males. The difference between the groups was statistically insignificant (chi-square, p value =0.84)

Discussion:

In this study we observed that the intercanthal distance was found to be greater in males than in females. In a study conducted by Radha et al, it was observed that all the values were significantly higher in males than females of south Indian ethnic origin and there is a significant sexual dimorphism in inner intercanthal distance (3). In another study conducted the highest mean for inner canthal distance was found at age 18 in males and age 15 in female. The highest mean for outer canthal distance in males is at age 18 and a female is at age 18. The highest mean values for the canthal index in males is at age 10 and females at age 15 ,whereas in this study there was no significant difference in the intercanthal distance between males and females (28).

It is absolutely essential to know the standard values of intercanthal distance in different specialties such as in orbital surgery, optometry, genetics and various other clinical complications (29). The facial profile varies from different ethnic groups, one of the dominant characteristics of Asian faces is a wider inner-canthal distance with relation to a shorter palpebral fissure comparatively (30). When a study was conducted on the Zairian Children, the ICD values showed a drastic progress, which increased from the age of 2 1/2 years to 18 years (31). Another study conducted revealed some major sources, which found that the Malaysian population reported that the ICD in case of the Malaysian South Indians was found to be similar to the Russians and Indians while that of the OCD was similar to Bulgarians, and it was found to be wider in Latvians and lesser in the middle eastern population (32). In a study conducted by Mohammad Etezard, he reported a linear correlation was found between the IPD and increasing age, just like that of ICD(33),(34),(35)(36). It is also found that the inner intercanthal distance set out as a guide in estimating the width of maxillary central incisors, which is one of the major determinants in the field of facial aesthetics (37). They have observed sexual dimorphism in all sorts of parameters whereas in an early study conducted there is significant sexual dimorphism in the inter-canthal distance only (38).

The study was limited only to a small sample size, that is only within the study population. Further studies should encompass larger sample sizes for more accurate results, which will include different ethnicities and age groups.

Future scope, through this research we provide the normative values for the inter canthal distance which will help in serving an important tool in diagnosing various orbital and clinical implications as well as planning an oculoplastic or orbital surgery.

Conclusion:

Through this study we can conclude that, there was no significant difference in the intercanthal distance between the two genders though males were found to have larger ICD than females. These data values will set out important aiding tools to dentists in the estimation, aesthetic selection and the arrangement of the maxillary anterior teeth. Orbitofacial anthropometric measurements can be used in identification of gender in forensic anthropology as well.

ACKNOWLEDGMENT:

Saveetha Dental College and Hospitals, Saveetha Institute of Medical and Technical Science, Saveetha University

AUTHORS CONTRIBUTION:

Fathima Hinaz: Literature search, data collection, Analysis, Manuscript drafting

Gheena.S: Data verification, Manuscript drafting

CONFLICT OF INTEREST:

All the authors declare that there was no conflict of interest in the present study.

SOURCE OF FUNDING:

The present study was supported by the following agencies

- Saveetha Dental College,
- Saveetha Institute of Medical and Technical Science,
- Saveetha University
- Honeywell International Middle East Ltd.,

REFERENCES:

1. Yaw LK, Subrata G, Ardan R. Determination of vertical dimension using intercanthal distance in adult Mongoloid race [Internet]. Vol. 26, Padjadjaran Journal of Dentistry. 2014. Available from: <http://dx.doi.org/10.24198/pjd.vol26no3.14003>
2. Anthropometric Assessment of Canthal Distances and Canthal Index of South Indian Region: A Cross-Sectional Study [Internet]. Medico-Legal Update. 2021. Available from: <http://dx.doi.org/10.37506/mlu.v21i1.2413>
3. Bhat V, George S. Inner canthal distance and golden proportion as predictors of maxillary central incisor width in south Indian population [Internet]. Vol. 21, Indian Journal of Dental Research. 2010. p. 491. Available from: <http://dx.doi.org/10.4103/0970-9290.74214>
4. Princeton B, Santhakumar P, Prathap L. Awareness on Preventive Measures taken by Health Care Professionals Attending COVID-19 Patients among Dental Students. Eur J Dent. 2020 Dec;14(S 01):S105–9.
5. Mathew MG, Samuel SR, Soni AJ, Roopa KB. Evaluation of adhesion of Streptococcus mutans, plaque accumulation on zirconia and stainless steel crowns, and surrounding gingival inflammation in primary molars: randomized controlled trial. Clin Oral Investig. 2020 Sep;24(9):3275–80.
6. Sridharan G, Ramani P, Patankar S, Vijayaraghavan R. Evaluation of salivary metabolomics in oral leukoplakia and oral squamous cell carcinoma. J Oral Pathol Med. 2019 Apr;48(4):299–306.
7. R H, Hannah R, Ramani P, Ramanathan A, Jancy MR, Gheena S, et al. CYP2 C9 polymorphism among patients with oral squamous cell carcinoma and its role in altering the metabolism of benzo[a]pyrene [Internet]. Vol. 130, Oral Surgery, Oral Medicine, Oral Pathology and Oral Radiology. 2020. p. 306–12. Available from: <http://dx.doi.org/10.1016/j.oooo.2020.06.021>

8. Antony JVM, Ramani P, Ramasubramanian A, Sukumaran G. Particle size penetration rate and effects of smoke and smokeless tobacco products - An invitro analysis. *Heliyon*. 2021 Mar 1;7(3):e06455.
9. Sarode SC, Gondivkar S, Sarode GS, Gadgil A, Yuwanati M. Hybrid oral potentially malignant disorder: A neglected fact in oral submucous fibrosis. *Oral Oncol*. 2021 Jun 16;105390.
10. Hannah R, Ramani P, WM Tilakaratne, Sukumaran G, Ramasubramanian A, Krishnan RP. Author response for "Critical appraisal of different triggering pathways for the pathobiology of pemphigus vulgaris—A review" [Internet]. Wiley; 2021. Available from: <https://publons.com/publon/47643844>
11. Chandrasekar R, Chandrasekhar S, Sundari KKS, Ravi P. Development and validation of a formula for objective assessment of cervical vertebral bone age. *Prog Orthod*. 2020 Oct 12;21(1):38.
12. Subramanyam D, Gurunathan D, Gaayathri R, Vishnu Priya V. Comparative evaluation of salivary malondialdehyde levels as a marker of lipid peroxidation in early childhood caries. *Eur J Dent*. 2018 Jan;12(1):67–70.
13. Jeevanandan G, Thomas E. Volumetric analysis of hand, reciprocating and rotary instrumentation techniques in primary molars using spiral computed tomography: An in vitro comparative study. *Eur J Dent*. 2018 Jan;12(1):21–6.
14. Ponnulakshmi R, Shyamaladevi B, Vijayalakshmi P, Selvaraj J. In silico and in vivo analysis to identify the antidiabetic activity of beta sitosterol in adipose tissue of high fat diet and sucrose induced type-2 diabetic experimental rats. *Toxicol Mech Methods*. 2019 May;29(4):276–90.
15. Adhikari N, Ambekar MN, Kc S. An Anthropometric Comparison of Inner Canthal Distance, Outer Canthal Distance and Canthal Index in the Indian and Nepalese Undergraduate Students of Nepalgunj Medical College [Internet]. Vol. 14, *Journal of Nepalgunj Medical College*. 2018. p. 12–4. Available from: <http://dx.doi.org/10.3126/jngmc.v14i2.21529>
16. Hayat N, Alkhairy S, Cheema A, Ehsan M, Khan MA. Normal interpupillary, inner canthal distance and outer canthal distance in a normal population of Pakistan [Internet]. Vol. 35, *Pakistan Journal of Medical Sciences*. 2019. Available from: <http://dx.doi.org/10.12669/pjms.35.1.288>
17. Sundaram R, Nandhakumar E, Haseena Banu H. Hesperidin, a citrus flavonoid ameliorates hyperglycemia by regulating key enzymes of carbohydrate metabolism in streptozotocin-induced diabetic rats. *Toxicol Mech Methods*. 2019 Nov;29(9):644–53.
18. Alsawalha M, Rao CV, Al-Subaie AM, Haque SKM, Veeraraghavan VP, Surapaneni KM. Novel mathematical modelling of Saudi Arabian natural diatomite clay. *Mater Res Express*. 2019 Sep 4;6(10):105531.
19. Yu J, Li M, Zhan D, Shi C, Fang L, Ban C, et al. Inhibitory effects of triterpenoid betulin on inflammatory mediators inducible nitric oxide synthase, cyclooxygenase-2, tumor necrosis factor-alpha, interleukin-6, and proliferating cell nuclear antigen in 1, 2-dimethylhydrazine-

induced rat colon carcinogenesis. *Pharmacogn Mag.* 2020;16(72):836.

20. Shree KH, Hema Shree K, Ramani P, Herald Sherlin, Sukumaran G, Jeyaraj G, et al. Saliva as a Diagnostic Tool in Oral Squamous Cell Carcinoma – a Systematic Review with Meta Analysis [Internet]. Vol. 25, Pathology & Oncology Research. 2019. p. 447–53. Available from: <http://dx.doi.org/10.1007/s12253-019-00588-2>
21. Zafar A, Sherlin HJ, Jayaraj G, Ramani P, Don KR, Santhanam A. Diagnostic utility of touch imprint cytology for intraoperative assessment of surgical margins and sentinel lymph nodes in oral squamous cell carcinoma patients using four different cytological stains. *Diagn Cytopathol.* 2020 Feb;48(2):101–10.
22. Karunakaran M, Murali P, Palaniappan V, Sivapathasundharam B. Expression and distribution pattern of podoplanin in oral submucous fibrosis with varying degrees of dysplasia – an immunohistochemical study [Internet]. Vol. 42, Journal of Histotechnology. 2019. p. 80–6. Available from: <http://dx.doi.org/10.1080/01478885.2019.1594543>
23. Osunwoke E. Photometric Facial Analysis of Soft Tissue Profile of Okrika Adults [Internet]. Vol. 4, Annual Research & Review in Biology. 2014. p. 1980–7. Available from: <http://dx.doi.org/10.9734/arrb/2014/5477>
24. Sadacharan CM. Orbitofacial Assessment of Indian Americans and Its Significance – An Anthropometric Study [Internet]. Vol. 1, MOJ Anatomy & Physiology. 2015. Available from: <http://dx.doi.org/10.15406/mojap.2015.01.00018>
25. Gudek MA, Uzun A. Anthropometric measurements of the orbital contour and canthal distance in young Turkish [Internet]. Vol. 64, Journal of the Anatomical Society of India. 2015. p. S1–6. Available from: <http://dx.doi.org/10.1016/j.jasi.2014.09.007>
26. Ellakwa A, McNamara K, Sandhu J, James K, Arora A, Klineberg I, et al. Quantifying the selection of maxillary anterior teeth using intraoral and extraoral anatomical landmarks. *J Contemp Dent Pract.* 2011 Nov 1;12(6):414–21.
27. Usman A. Frase Nomina Bahasa Gorontalo [Internet]. Vol. 3, Kajian Linguistik. 2015. Available from: <http://dx.doi.org/10.35796/kaling.3.1.2015.8608>
28. Gabriel S. Wissensmanagement an BMHS [Internet]. 2013. Available from: <http://dx.doi.org/10.3726/978-3-653-02968-0>
29. Hamosh A, Scott AF, Amberger J, Bocchini C, Valle D, McKusick VA. Online Mendelian Inheritance in Man (OMIM), a knowledgebase of human genes and genetic disorders. *Nucleic Acids Res.* 2002 Jan 1;30(1):52–5.
30. Le TT, Farkas LG, Ngim RCK, Levin LS, Forrest CR. Proportionality in Asian and North American Caucasian faces using neoclassical facial canons as criteria. *Aesthetic Plast Surg.* 2002 Jan;26(1):64–9.

31. Kaimbo DK, Kayembe D. [Orbital measurements in Zairian children. Inner canthal, outer orbital, inter-pupillary distances and proptosis]. *J Fr Ophtalmol*. 1994;17(8-9):496–500.
32. Singh JR, Banerjee S. Normal Values for Interpupillary, Inner Canthal and Outer Canthal Distances in an Indian Population [Internet]. Vol. 33, *Human Heredity*. 1983. p. 326–8. Available from: <http://dx.doi.org/10.1159/000153399>
33. Sarode SC, Gondivkar S, Gadbail A, Sarode GS, Yuwanati M. Oral submucous fibrosis and heterogeneity in outcome measures: a critical viewpoint. *Future Oncol*. 2021 Jun;17(17):2123–6.
34. Raj Preeth D, Saravanan S, Shairam M, Selvakumar N, Selestina Raja I, Dhanasekaran A, et al. Bioactive Zinc(II) complex incorporated PCL/gelatin electrospun nanofiber enhanced bone tissue regeneration. *Eur J Pharm Sci*. 2021 May 1;160:105768.
35. Prithiviraj N, Yang GE, Thangavelu L, Yan J. Anticancer Compounds From Starfish Regenerating Tissues and Their Antioxidant Properties on Human Oral Epidermoid Carcinoma KB Cells. In: *PANCREAS. LIPPINCOTT WILLIAMS & WILKINS TWO COMMERCE SQ, 2001 MARKET ST, PHILADELPHIA ...*; 2020. p. 155–6.
36. Razavi ME, Abotoraby RB, Kakhki RD, Ghanavati SZ, Layegh P, Taghavi M, et al. Clinical evaluation of Graves ophthalmopathy in north-east Islamic Republic of Iran. *East Mediterr Health J*. 2008 Jul;14(4):841–9.
37. Rehulina, Rehulina. Hak Dan Kewajiban Penjual Dan Pembeli Sebagai Substansi Kontrak Dagang Elektronik Mereduksi Asas Kebebasan Berkontrak [Internet]. Available from: <http://dx.doi.org/10.31227/osf.io/5m37z>
38. A. H. Sexual Dimorphism Using Geometric Morphometric Approach [Internet]. *Sexual Dimorphism*. 2013. Available from: <http://dx.doi.org/10.5772/55195>