

## Evaluation of effect of platelet rich fibrin (PRF) and Demineralised Freeze-dried bone allograft (DFDBA) in maintaining dimensional changes of Transalveolar extraction socket

Hanan Ghazi Shanab <sup>1</sup>, Farheena Ustad <sup>1</sup> Fazlur Rahman Sayed <sup>2</sup>, Sufiyan Shaikh <sup>3</sup>, Olfat Mohamed Gaballah <sup>1,4</sup>, Hend Elkafrawy <sup>5,6</sup>, Amira A. R. Moawad <sup>1,7</sup>, Ghufuran Alayfan <sup>1</sup>, Hoda Abdelwahab Fansa <sup>8,9</sup>, Eman Abd El Sattar Abd El Megid Tella <sup>8</sup> and Shaeesta Khaleelahmed Bhavikatti <sup>10,\*</sup>

<sup>1</sup> Department of Oral and Maxillofacial Surgery and Diagnostic Sciences, College of Dentistry, Majmaah University . Al-Majmaah University 11952 . Saudi Arabia.

<sup>2</sup> Badr Al Samaa Group of Hospitals, Al Khuwair 112, Oman.

<sup>3</sup> Happy Mouth Dental Clinic, Mumbai 400018, Maharashtra, India.

<sup>4</sup> Department of Oral Biology, Faculty of Dentistry, Tanta University, Tanta, Egypt.

<sup>5</sup> Department of Restorative Dental Science, College of Dentistry, Majmaah University. Al-Majmaah University 11952 . Saudi Arabia.

<sup>6</sup> Dental Biomaterials Department, Faculty of Dentistry, Tanta University, Tanta, Egypt.

<sup>7</sup> Department of Oral Biology, Faculty of Dentistry, Mansoura University, Mansoura, Egypt.

<sup>8</sup> Department of Basic and Clinical Oral Sciences, College of Dentistry, Umm Al-Qura University, Saudi Arabia.

<sup>9</sup> Department of Oral Biology, Faculty of Dentistry, Alexandria University, Alexandria, Egypt.

<sup>10</sup> Department of Periodontics, Saveetha Dental College & Hospitals, Saveetha Institute of Medical and Technical Sciences University, Chennai 600077, India

---

### Abstract:

**Aim:** Comparison of dimensional changes in non-augmented transalveolar extraction sockets with those augmented with Platelet-rich fibrin (PRF) and Demineralized Freeze-Dried Bone Allograft (DFDBA).

**Methodology:** The study included 30 patients between 18 to 50 years who are scheduled to undergo transalveolar extractions of the mandibular third molar. Patients were randomly divided into three groups. In group A extraction sockets will be left for routine healing while in group B augmented with PRF while in group C, augmentation was done with DFDBA. All the patients were observed for 6 months after the surgery. Clinical Parameters (Pain and soft tissue healing) were taken at baseline, 1 week and 6 month intervals while Radiological parameters like .mesiodistal width and cervico-apical height were compared with CBCT image help at baseline and 6 months.

**Result:** The matching groups were matched based on Age, Gender and Tooth number. There was a non-significant difference in pain scale and soft tissue healing between the groups at all time intervals. The mean vertical height of bone was comparable at baseline but showed a significant difference in group A (7.59±0.74 mm) as a comparison to group B (10.95±0.66 mm) and group

C( $10.53 \pm 0.75$  mm) at 6 months. A similar result was also obtained with mean mesio-distal width, which also showed a significant difference in group A ( $8.62 \pm 1.60$  mm) as a comparison to group B ( $9.77 \pm 1.10$  mm) and group C ( $9.95 \pm 0.98$  mm) at 6 months.

**Conclusion:** The present study indicates a significant improvement in the regeneration of bone after third molar surgery in cases treated with PRF and DFDBA. The use of autologous PRF and DFDBA in the healing sockets (extraction sites) and surgical sites is recommended to improve bone healing and minimize resorption

**Keywords:** platelet-rich fibrin (PRF), Demineralized Freeze-dried bone allograft (DFDBA), Pain

## 1. Introduction

Tooth extraction is a standard dental procedure in managing tooth decay, complicated fractures, periodontal disease, infections and orthodontic space creation. Physiologic healing of the post-extraction socket involves a complex process of bone cells migration and maturation, leading to selective bone resorption and apposition (1,2). These post-extraction events result in a dimensional loss in the residual alveolar ridge's horizontal and vertical planes.

The dimensional change of an alveolar ridge is inevitable overtime after tooth extraction. Bone resorption is more rapid in existing periodontal disease, inflammatory periapical lesions, or severe previous bone wall defects after the extraction. The soft tissue collapses into the defect, hindering normal and natural healing. (3) Therefore, various methods were attempted to minimize alveolar bone resorption and ridge preservation. Socket preservation using biomaterials has been proposed, and autologous platelet concentrates, including platelet-rich fibrin (PRF) and are employed (4,5) Platelet-rich fibrin gel was first described by Choukroun et al. (6) in France. It has been referred to as the second generation plateletfibrin gel concentrate. It has the following advantages; Ease of preparation, Lack of biochemical handling of blood, Strictly autologous nature.

Freeze-dried bone allograft (FDBA) and Demineralized freeze-dried bone allograft (DFDBA) are harvested from cadaverous sources in the same manner, with the difference being that the DFDBA material undergoes the additional step of decalcification. (7) Exposure of bone morphogenetic protein (BMP) by demineralization of the allograft material is thought to enhance the osteogenic potential of the graft material. DFDBA alone is the most predictable regenerative procedure for achieving selected treatment outcomes in intrabony and furcation defects. (8)

Demineralized freeze-dried bone graft (DFDBA) has both osteoconductive and osteoinductive potential. It stimulates the host undifferentiated mesenchymal cells to differentiate into osteoblast, which leads to bone formation. DFDBA also acts as a scaffold for osteoinduction. (7) Platelet-rich fibrin (PRF) contains a high concentration of growth factors like PDGF, TGF- $\beta$ , IGF and VEGF and antiinflammatory molecules like IL-1 $\beta$ , IL-4, IL-6 AND TNF- $\alpha$ . These factors enhance the soft and hard tissue healing process, which lead to better bone repair and regeneration. (7,9)

The current study aims to compare dimensional changes in non-augmented transalveolar extraction sockets with those augmented with Platelet-rich fibrin (PRF) or Demineralized Freeze-Dried Bone Allograft (DFDBA). This comparative study had undertaken to compare the efficacy of PRF and DFBA for the evaluation of bone regeneration after surgical/transalveolar extraction. This study will also enable us to

evaluate & compare parameters like rate of bone regeneration, soft tissue healing & symptomatic parameters like post-operative pain and soft tissue healing.

## **2. Methodology**

The study was conducted in the Department of Oral And Maxillofacial Surgery at the College of Dentistry after approval from the institutional ethical committee. The study included the patients scheduled to undergo transalveolar extractions from the outpatient department in the Department of Oral And Maxillofacial Surgery after taking written informed consent from the patients. The patients were recruited based on the following inclusion and exclusion criteria.

### **2.1 Inclusion criteria**

1. Patients with age group from 18 to 50 years.
2. Both genders – Male and Female
3. All the teeth indicated transalveolar extraction with buccal bone preservation.
4. Patient with failed endodontic therapy.
5. All traumatically fractured teeth.

All the cases of surgical extraction require pre-operative CBCT.

### **2.2 Exclusion criteria**

1. Patients with periapical pathology, cyst, tumours.
2. Patients on corticosteroid therapy.
3. Patients with Systemic diseases like diabetes, hyperparathyroidism, chronic renal failures, osteomalacia, paraneoplastic syndromes, infections.
4. Patients with altered calcium and phosphorous metabolism.
5. Patients with pregnancy.
6. History of osteoradionecrosis of the jaw.
7. Patients with a history of radiotherapy.

The study was conducted for 1 year (March 2020 – March 2021) 30 patients indicated for transalveolar extraction reporting to the Dept. of Oral & Maxillofacial Surgery. These patients were equally distributed in three groups with the help of a simple randomization technique (lottery method).

- Group A – 10 transalveolar extraction sockets will be left for routine healing (blood clot)

- Group B –10 transalveolar extraction sockets will be augmented with PRF.
- Group C-10 transalveolar extraction sockets will be augmented with a bone graft.

The Radiographic evaluations of patients were done using IOPA & CBCT before starting the study, and patients' treatment plan was decided. Under all aseptic conditions & precautions, local anaesthesia was administered intraorally. Depending upon the clinical situation, an envelope, triangular or trapezoidal flap was raised. Bone guttering but buccal bone preservation was performed with rotatory instruments like burs & handpieces with copious saline irrigation. Elevators were then used to luxate the root/ tooth followed by removal with appropriate extraction forceps and wound closure with appropriate suturing technique; in patients allocated to group A, the socket was allowed to heal usually either by primary or secondary intention, which is deemed to be our control group. In Group B patients, autologous platelet-rich fibrin (PRF) was placed in the extraction socket, while in Group C patients, demineralized freeze-dried bone graft was incorporated in the extraction socket. Post-operative clinical evaluation was performed at the first week & sixth-month follow-up. The socket's mesiodistal and cervico-apical width through conebeam computed tomography (CBCT) was evaluated preoperatively and at the sixth month follow-up period. Intraoral Periapical Radiographs (IOPA) were required immediate post-operative phase.

Human DFDBA, in size from 200 µm, was obtained from bone banks while PRF was prepared with the help of Chokroun's method, in which 10 ml of blood was drawn intravenously from the antecubital region of the patient's forearm in vacutainers without anticoagulant. The collected blood was centrifuged immediately at the rate of 3000 rpm for 10 minutes. This leads to the formation of three compartments with a firm fibrin clot in the middle of the tube. The clot thus formed is a leukocyte-rich PRF clot. This clot thus formed was then placed in the surgically extracted socket.

The following Clinical and Radiological (CBCT) parameters of patients were evaluated –

### **2.3 Clinical Parameters**

1. Numeric rating scale (NRS) and the Wong-Baker Faces Pain Scale (FPS)
2. Soft tissue healing index. (Landry et al.)

#### *Radiological (CBCT) parameters*

1. mesiodistal width
2. cervico-apical Height ( from alveolar crest)

### **3. RESULT**

The study had included 30 patients and was randomly divided into three groups. The matching groups were matched based on Age, Gender and Tooth number. (Table 1) The groups were compared for clinical parameters for pain with the help of the VAS scale and soft tissue healing index at baseline, 1 week and 6

months. The groups were also compared for Mesio distal width and cervico-apical height ( from alveolar crest) based on CBCT performed at baseline and 6 months.

The mean pain on the VAS scale at baseline was  $4.00 \pm 2.26$  in group A,  $2.80 \pm 2.14$  in group B and  $3.20 \pm 1.68$  in group C. There were no significant differences between the groups with F values 0.76 and p-value 0.47. After 1 week, the mean pain was  $1.60 \pm 1.57$  in group A,  $2.00 \pm 1.53$  in group B and  $1.80 \pm 1.03$  in group C. There were non-significant differences between the groups with F value 0.23 p-value 0.79. After 6 months, the mean pain was  $0.00 \pm 0.00$  in group A,  $0.00 \pm 0.00$  in group B, and  $0.20 \pm 0.60$  in group C. There was a non-significant difference between the groups with F value 1.00 and p-value 0.38. The value of mean pain at the VAS scale showed no significant difference between the groups at all time intervals. (Table 2, Graph 1)

The healing of Soft tissue was compared with index was compared by Soft tissue healing index by Landry et al. using chi-square test. The test result showed a non-significant difference in soft tissue healing between the groups at different time intervals. Therefore all the groups showed an equal amount of soft tissue healing at all periods. (Table 3)

The mean vertical height of bone at baseline was  $8.29 \pm 2.24$  mm in group A,  $8.65 \pm 2.20$  in group B and  $8.49 \pm 2.20$  in group C. There was no significant difference between the groups with F value = 1.15 and pvalue =0.33. After 6 months, the mean vertical height of bone was  $7.59 \pm 0.74$  mm in group A,  $10.95 \pm 0.66$  mm in group B and  $10.53 \pm 0.75$  mm in group C. There was a significant difference between the groups with F value = 3.88 and p-value =0.02. The post hoc Tukey test finds that there was significantly more Vertical height in Group B and Group C in comparison to Group A. (Table 4)

The mean Bucco Lingual width of bone at baseline was  $9.14 \pm 1.16$  mm in group A,  $8.90 \pm 1.14$  in group B and  $9.25 \pm 0.70$  mm in group C. There was no significant difference between the groups with F value 0.21 and p-value 0.80 but after 6 months, the mean Bucco Lingual width of bone was  $8.62 \pm 1.60$  mm in group A,  $9.77 \pm 1.10$  mm in group B and  $9.95 \pm 0.98$  mm in group C. There was a significant difference between the groups with F value 3.27 and p-value 0.04. The post hoc Tukey test finds that there was significantly more Bucco Lingual width in Group B and Group C in comparison to Group A. (Table 4)

Table 1: Comparison of Demographical parameters between the groups

Parameters	Group A	Group B	Group C	Chi square	P value
Male	7	7	5	4.35	.50

<b>Gender</b>	Female	3	3	5		
<b>Age</b>	15 -25 yrs	4	4	3	5.85	.31
<b>Age</b>	25 – 35 yrs	4	3	3		
	35 – 50 yrs	2	3	4		
<b>Age</b>	38 (Left Third Molar)	6	7	6	2.81	.87
<b>Tooth number</b>	48 (Right Third Molar)	4	3	4		

Table 2: Comparison of Vertical Height and mesio-distal width preoperatively and after 6 months between the groups

Parameters	Time	Group A	Group B	Group C	F value	P Value
<b>Height</b>	preoperative	8.29±2.24	8.65±2.20	8.49±2.10	0.45	.64
	6 month	7.59±0.74	10.95±0.66	10.53±0.75	7.78	.001*
<b>width</b>	preoperative	9.14±1.16	8.90±1.14	9.25±0.70	0.21	0.80
	6 month	8.62±1.60	9.77±1.10	9.95±0.98	3.27	0.04*

\* significant, ANOVA test

Graph 1: Comparison of Bone height and width between the groups

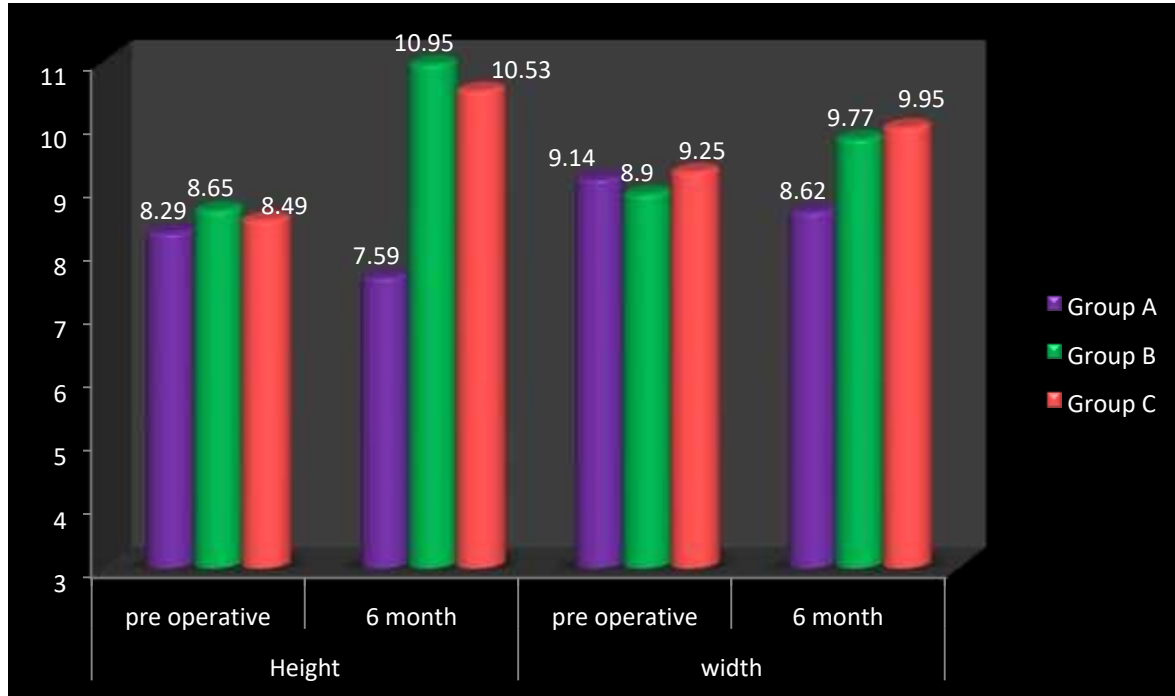


Table 3: Comparison of pain scale between the groups at different time intervals

Time	Group	Mean	Std. Deviation	F value	P-value
Pre operative	Group A	4.00	2.66	.76	.47
	Group B	2.80	2.14		
	Group C	3.20	1.68		
1 week	Group A	1.60	1.57	0.23	.79
	Group B	2.00	1.33		
	Group C	1.60	1.57		
6 months	Group A	.20	.63	1.00	.38
	Group B	.00	.00		
	Group C	.00	.00		

\*significant, ANOVA test

Table 4: Comparison of soft tissue healing between the groups at different time intervals

Time	Group	Excellent	Very Good	Good	Poor	Very Poor	Chisquare	P-value
Pre operative	Group A	0	3	4	3	0	6.38	.60
	Group B	0	1	6	2	1		
	Group C	0	2	6	2	0		

<b>1 week</b>	Group A	0	2	7	1	0	2.25	.69
	Group B	0	3	7	0	0		
	Group C	0	3	7	0	0		
<b>6 months</b>	Group A	10	0	0	0	0	0.00	1.00
	Group B	10	0	0	0	0		
	Group C	10	0	0	0	0		

#### 4. Discussion

The study aimed to evaluate extraction socket healing using Autologous platelet-rich fibrin (PRF) and demineralized freeze-dried bone graft (DFDBA) both clinically and radiographically. The hypothesis was that PRF and DFDBA would accelerate socket wound healing and increase bone deposition after partially accepting tooth extraction. The use of PRF and DFDBA had no significant effect on pain and soft tissue healing parameters. The bone height and mesio-distal width had shown a significant increase in PRF and DFDBA compared to the control group.

Traditionally, different alveolar ridge preservation techniques have been used, most of which include the placement of graft material into extraction sockets for bone augmentation(12,13). These materials include autografts, allografts, Xenografts and alloplastic. According to Kotsakis and Chrepa (14), flap advancement for primary closure in ridge preservation interventions may lead to repositioning the mucogingival junction, displacement of the keratinized mucosa, and ridge resorption.

He and Lin suggested that the incorporation of PRF increases the efficiency of cell proliferation. In addition, platelets in the PRF undergo degranulation, providing a sustained release of growth factors [platelet derived growth factors (PDGF), vascular endothelial growth factor (VEGF), epidermal growth factor (EGF), thrombospondin-1 (TSP-1), transforming growth factor-beta (TGF-b)]. These factors influence angiogenesis, epithelialization, stem cell trapping and immune control (15,16). This provides significant elements for accelerated bone healing in the presence of PRF.

Demineralized freeze-dried bone allograft (DFDBA) have been used in periodontal therapy for 2 decades (8). They have been successfully used to reconstruct intraosseous periodontal defects (17) and furcation defects. (18) Exposure of bone morphogenetic protein (BMP) by demineralization of the allograft material is thought to enhance the osteogenic potential of the graft material. (7)

Demineralized freeze-dried bone allograft (DFDBA) have now been tried as Ridge Preservation material after tooth extraction. Whetman J and Brian Mealey L(19) had found an average new vital bone formation of 47.41% was found after 19 weeks of healing. This result coincides with knowledge of donor variability as the in vivo inductivity score of DFDBA used by Wood and Mealey (20).



Norton and Wilson suggested that the use of grafts for socket preservation increases the treatment cost and the risk of disease transmission (21). However, From a clinical perspective, the use of autologous PRF and DFDBA in the healing sockets (extraction sites) and surgical sites is recommended to improve bone healing and minimize resorption(3).

## **5. Conclusion**

The present study indicates a significant improvement in the regeneration of bone after third molar surgery in cases treated with PRF and DFDBA compared to the control group postoperatively. This increase in the bone height and width signifies the use of PRF and DFDBA certainly as a method of increasing bone regeneration after extraction.

**Conflict of interest:** The authors declared no conflict of interest with this article.

## **References**

1. Cardaropoli G, Araujo M, Lindhe J. Dynamics of bone tissue formation in tooth extraction sites: an experimental study in dogs. *Journal of clinical periodontology*. 2003;30(9):809–18.
2. Araújo MG, Lindhe J. Dimensional ridge alterations following tooth extraction. An experimental study in the dog. *Journal of clinical periodontology*. 2005;32(2):212–8.
3. Alzahrani AA, Murriky A, Shafik S. Influence of platelet rich fibrin on post-extraction socket healing: A clinical and radiographic study. *The Saudi dental journal*. 2017;29(4):149–55.
4. Zhang Y, Wang Y, Shi B, Cheng X. A platelet-derived growth factor releasing chitosan/coral composite scaffold for periodontal tissue engineering. *Biomaterials*. 2007;28(8):1515–22.
5. Rutherford RB, Niekrash CE, Kennedy JE, Charette MF. Platelet-derived and insulin-like growth factors stimulate regeneration of periodontal attachment in monkeys. *Journal of periodontal research*. 1992;27(4):285–90.
6. Dohan DM, Choukroun J, Diss A, Dohan SL, Dohan AJJ, Mouhyi J, et al. Platelet-rich fibrin (PRF): a second-generation platelet concentrate. Part I: technological concepts and evolution. *Oral Surg Oral Med Oral Pathol Oral Radiol Endod*. 2006 Mar;101(3):e37-44.
7. Cammack GV, Nevins M, Clem D 3rd, Hatch JP, Mellonig JT. Histologic evaluation of mineralized and demineralized freeze-dried bone allograft for ridge and sinus augmentations. *Int J Periodontics Restorative Dent*. 2005;25(3):231–7.
8. Schwartz Z, Mellonig JT, Carnes Jr DL, De La Fontaine J, Cochran DL, Dean DD, et al. Ability of commercial demineralized freeze-dried bone allograft to induce new bone formation. *Journal of periodontology*. 1996;67(9):918–26.

9. Gürbüz B, Pıkdöken L, Tunalı M, Urhan M, Küçükodacı Z, Ercan F. Scintigraphic evaluation of osteoblastic activity in extraction sockets treated with platelet-rich fibrin. *Journal of oral and maxillofacial surgery*. 2010;68(5):980–9.
10. Lawson SL, Hogg MM, Moore CG, Anderson WE, Osipoff PS, Runyon MS, et al. Pediatric Pain Assessment in the Emergency Department: Patient and Caregiver Agreement Using the Wong-Baker FACES and the Faces Pain Scale-Revised. *Pediatric emergency care*. 2019;
11. Landry RG. Effectiveness of benzydamine HC1 in the treatment of periodontal post-surgical patients [PhD Thesis]. Faculty of Dentistry, University of Toronto; 1985.
12. Froum S, Cho S-C, Rosenberg E, Rohrer M, Tarnow D. Histological comparison of healing extraction sockets implanted with bioactive glass or demineralized freeze-dried bone allograft: A pilot study. *Journal of periodontology*. 2002;73(1):94–102.
13. Vance GS, Greenwell H, Miller RL, Hill M, Johnston H, Scheetz JP. Comparison of an allograft in an experimental putty carrier and a bovine-derived xenograft used in ridge preservation: a clinical and histologic study in humans. *International Journal of Oral & Maxillofacial Implants*. 2004;19(4).
14. Kotsakis G, Chrepa V, Marcou N, Prasad H, Hinrichs J. Flapless alveolar ridge preservation utilizing the "socket-plug" technique: clinical technique and review of the literature. *Journal of Oral Implantology*. 2014;40(6):690–8.
15. Gürbüz B, Pıkdöken L, Tunalı M, Urhan M, Küçükodacı Z, Ercan F. Scintigraphic evaluation of osteoblastic activity in extraction sockets treated with platelet-rich fibrin. *Journal of oral and maxillofacial surgery*. 2010;68(5):980–9.
16. Mazor Z, Horowitz RA, Del Corso M, Prasad HS, Rohrer MD, Dohan Ehrenfest DM. Sinus floor augmentation with simultaneous implant placement using Choukroun's platelet-rich fibrin as the sole grafting material: a radiologic and histologic study at 6 months. *Journal of periodontology*. 2009;80(12):2056–64.
17. Mellonig JT. The effect of different particle sizes of freeze-dried bone allograft on bone growth. *J Dent Res*. 1984;63(222).
18. Schallhorn RG. Combined osseous composite grafting root conditioning and guided tissue regeneration. *Int J Periodont Rest Dent*. 1988;8(4):13–32.
19. Whetman J, Mealey BL. Effect of healing time on new bone formation after tooth extraction and ridge preservation with demineralized freeze-dried bone allograft: a randomized controlled clinical trial. *Journal of periodontology*. 2016;87(9):1022–9.

20. Wood RA, Mealey BL. Histologic comparison of healing after tooth extraction with ridge preservation using mineralized versus demineralized freeze-dried bone allograft. *Journal of periodontology*. 2012;83(3):329–36.
21. Norton MR, Wilson J. Dental implants placed in extraction sites implanted with bioactive glass: human histology and clinical outcome. *International Journal of Oral & Maxillofacial Implants*. 2002;17(2).