

# Knowledge And Awareness on Forensic Odontology Among Law Professionals

<sup>1</sup>Ashwin Krishna B, <sup>2</sup>Dr. Gheena S, <sup>3</sup>Dr. Sandhya,

<sup>1</sup>Saveetha Dental College and Hospitals, Saveetha Institute of Medical and Technical Sciences (SIMATS), Saveetha University, Chennai – 600077, Tamil Nadu, India

Email ID: [152001067.sdc@saveetha.com](mailto:152001067.sdc@saveetha.com)

<sup>2</sup>Professor, Department of Oral Pathology, Saveetha Dental College and Hospitals, Saveetha Institute of Medical and Technical sciences (SIMATS), Saveetha University, Chennai – 600077, Tamil Nadu, India

Email ID: [gheena@saveetha.com](mailto:gheena@saveetha.com)

<sup>3</sup>Senior lecturer, Department of Dental Anatomy, Saveetha Dental College and Hospitals, Saveetha Institute of Medical and Technical sciences (SIMATS), Saveetha University, Chennai – 600077, Tamil Nadu, India

Email ID: [sandhyas.sdc@saveetha.com](mailto:sandhyas.sdc@saveetha.com)

---

## ABSTRACT

**AIM:** To create awareness among law professionals on the importance of forensic odontology.

## BACKGROUND:

Forensic Odontology has been a crucial scientific factor in medico-legal matters and in the identification of the dead person. Different strategies have been developed to determine age, sex, and nationality of the person, using dental tissues which is helpful in solving crime cases.

## MATERIALS AND METHODS:

Online survey was done through a standard questionnaire and the data is collected and tabulated. The data is further analysed using SPSS statistical software version 23.

## RESULT:

About 71.11% of the law professionals are aware that teeth can serve as a source of DNA. Majority 64.44% of the respondents are aware that sex determination can be done by using bar bodies. Nearly 60% of the law professionals are aware that bite marks are the most common evidence in case of any sexual abuse or child abuse. The majority 31.46% males believed Fingerprinting and 13.48% females felt physical and anthropological examination to be the first step for identification of dead bodies. The differences were statistically not significant (Chi square test, P value = 2.50).

## CONCLUSION:

In this study we observed that DNA fingerprinting is the first step of identification of unclaimed bodies; the bite Mark analysis and lip printing are helpful tools in Forensic odontology. In this study it is evident that the law professionals are moderately aware of the importance of forensic odontology.

## KEY WORDS:

Forensic odontology, civil cases, criminal cases, lip printing, bite marks, Innovative study.

**Running title:** Awareness of forensic odontology among law professionals.

## INTRODUCTION:

In today's time crime rates are a bit high and the identification of victims or criminals is a very difficult process. In this situation dentists play a major role in investigating the crime, through a special department known as Forensic odontology(1). Forensic odontology is a branch of medicine that includes handling, examination and providing dental evidence to provide proper justice. Forensic Odontologist assist legal authority by clearly examining the dental evidence(2). Knowledge of forensic dentistry requires a co-ordination of a number of disciplines to establish and in the identification of cases(3).

Dentition of an individual is helpful in identification and comparison as it is unique. Three major areas in forensic or ontology are diagnostic and therapeutic examination of injury in oral tissue teeth, Identification of Individuals in the huge disorder, identification of bite marks occurs during child abuse sexual assault and in personal Defence situations(4). Forensic odontology is the study of dental applications in legal proceedings. The subject covers a numerous variety of topics including mass identification, individual identification, and bite mark analysis(5). The study of odontology in a legal case can be a piece of incriminating evidence or an aspect of wide controversy. The teeth can also be used as weapons under certain circumstances, and may leave information about their identity. Dental professionals have a crucial role to play in keeping accurate dental records and providing information so that legal authorities could recognize assault or abuse(6). Our team has extensive knowledge and research experience that has translate into high quality publications (7),(8),(9),(10),(11),(12),(13),(14),(15),(16),(17),(18),(19),(20),(21),(22),(23),(24),(25),(26). The main aim of the study is to spread awareness among law professionals on the importance of forensic odontology.

#### **MATERIALS AND METHODS:**

A cross-sectional study was conducted among law professionals practicing in South India. Convenience sampling technique was employed. A pre-validated and reliable questionnaire containing 10 questions in English was distributed to the participants (Annexure 1) through an online google form link. The questionnaire contained the question items pertaining to their knowledge, and awareness on forensic odontology. Law professionals from south India had been included in the study. Voluntary consent from the participants had been obtained after explaining the need for the study. Prior approval to carry out the study was obtained from the Institutional Research Committee (IRB) of the authors University. Statistical analysis was performed in the statistical Package for the Social Sciences (SPSS) software version 23.0 (IBM, Chicago, USA). Descriptive statistics were performed to present the frequency distribution of the options of the question items.

#### **RESULTS:**

A total of 90 respondents i.e, 62.2% female and 37.8% male law professionals participated in the study. In this study sample, the majority 31.46% males answered Fingerprinting and 13.48% females answered physical and anthropological examination as the first step for identification of dead bodies (figure 1). Nearly 60% of the respondents are aware that bite marks are the most common evidence in case of any sexual abuse or child abuse (figure 2). About 71.11% of the law professionals are aware that teeth can serve as a source of DNA (figure 3). Nearly 41.91% of the professionals are aware of DNA fingerprinting which is the first step in identification of unclaimed bodies (figure 4). Majority (64.44%) of the respondents are law professionals and they are aware that sex determination can be done by using bar bodies (figure 5). Majority 78.89% of the respondents are professionals and they are aware that enamel, cementum or dentin acts as an important aid for identification of age. Nearly 54.44% of the respondents are cautious about sexual abuse as they contact police in case they find any sign or symptoms regarding child abuse sexual abuse (figure 6). About 63.33% of the professionals are aware that forensic odontology is a part of medicine. Majority 71.11% of the law professionals are aware that the court accepts the statement of a dentist as an expert evidence or witness (figure 7). About 70% of the respondents are professionals and they are aware that loss or fracture of teeth is a grievous injury under IPC 320 class 7(5) . About 63.33% of the law professionals are aware that forensic odontology plays a role in identifying civil malpractices. Nearly 74.44% of the respondents are

law professionals and they are aware that forensic odontology helps in Criminal or victim analysis. Majority 80% of the law professionals are aware that lip print analysis is the new technique and it is a new tool in Forensic odontology as the prints are as unique as that of fingerprints. Majority 27.78% of females and 13.33% of males are aware that DNA fingerprinting is the first step in identification of unclaimed bodies. Males and females answered equally (20%) that bite mark analysis is one of the commonest forms of evidence presented in the court.

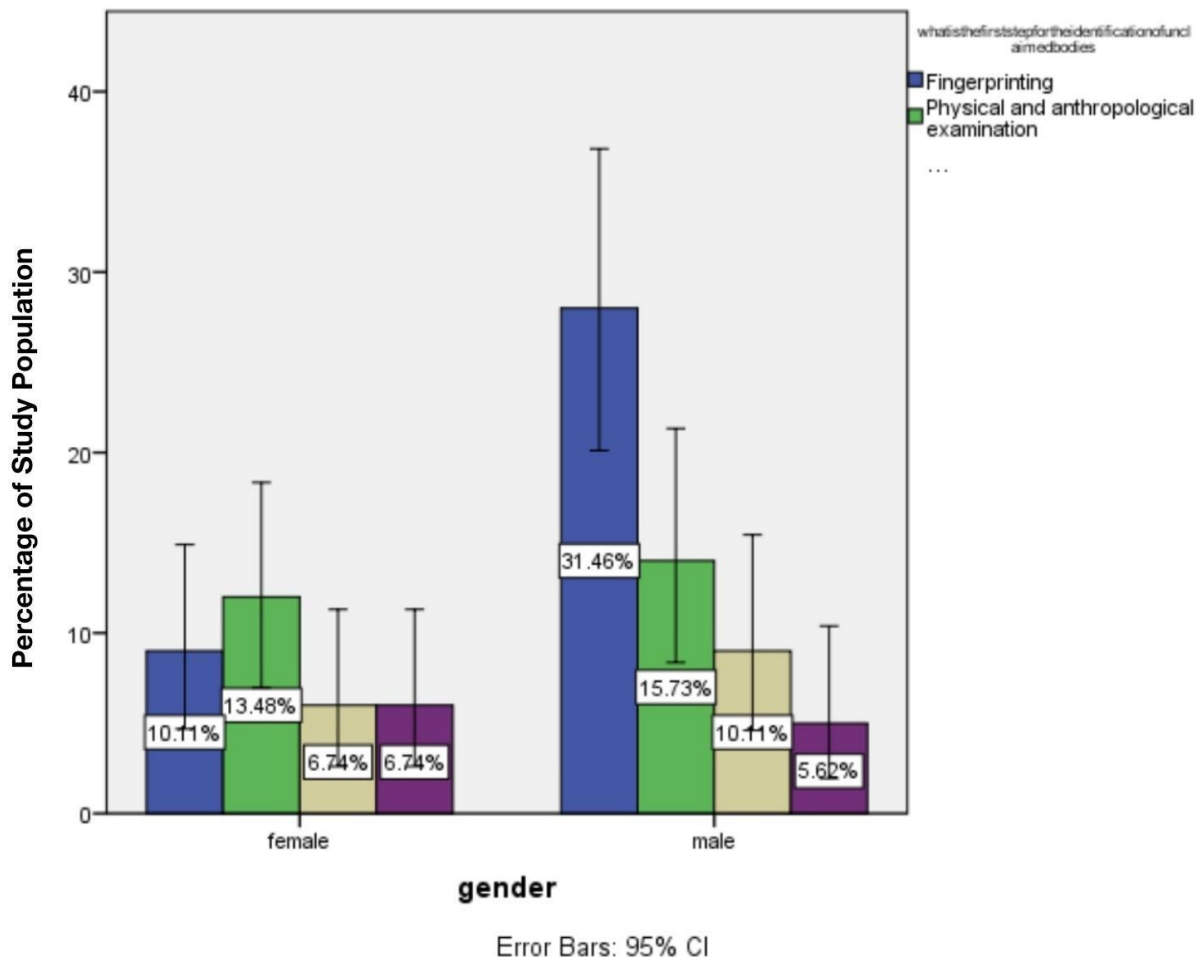


FIGURE 1: The bar graph represents the response of participants regarding the method used as the first step in identification of dead bodies. The x-axis of the graph denotes the gender of the study participants and Y-axis denotes the percentage of responses of participants. Blue represents DNA fingerprinting, green represents physical and anthropological examination, sandal represents serological and genetic DNA comparison and purple represents visual examination. The maximum responses were in favour of DNA fingerprinting with 10.11 % among females and 31.46% among males. The difference was not statistically significant (Chi square test, P value= 2.50(p>0.05)).

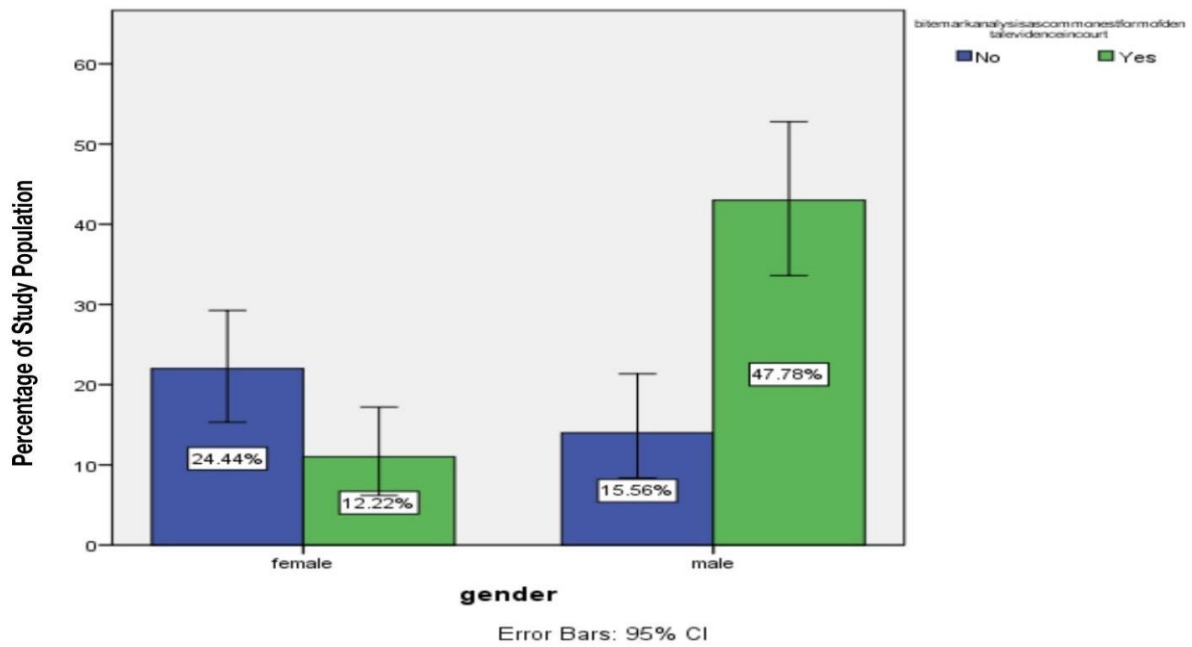


FIGURE 2 : The bar graph represents the awareness of the participants regarding the bite mark analysis as a common form of evidence in forensic odontology. X axis represents the percentage of people answered and Y axis represents gender. 12.22% of females and 47.78% of males were aware and 15.56% of males and 24.44% of females answered no (blue). [Pearson Chi Square value,  $P = 2.921$  ( $p > 0.05$ )]. Hence it is not significant.

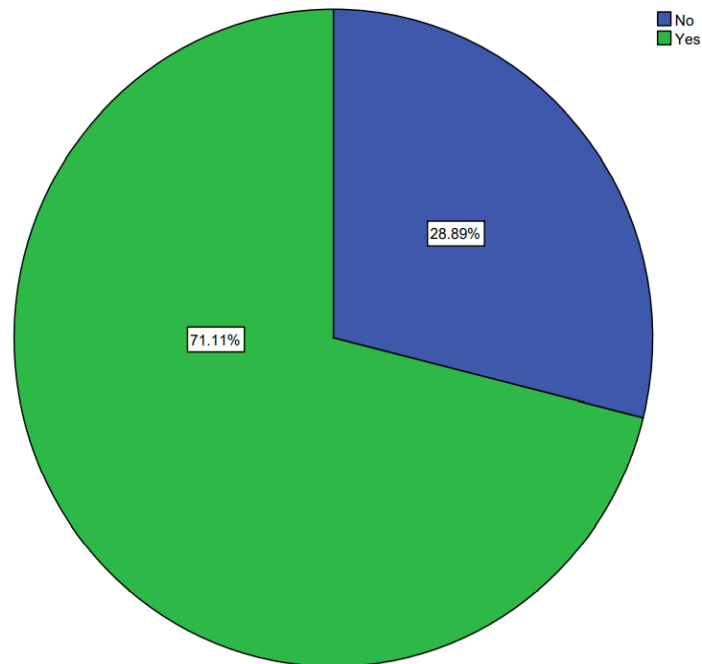


FIGURE 3: The pie chart represents the responses of the participants on the fact that teeth can act as a source of DNA extraction. Green represents Yes and Blue represents No. Among the participants, 71.11% of them were aware of the fact and 28.89% were unaware.

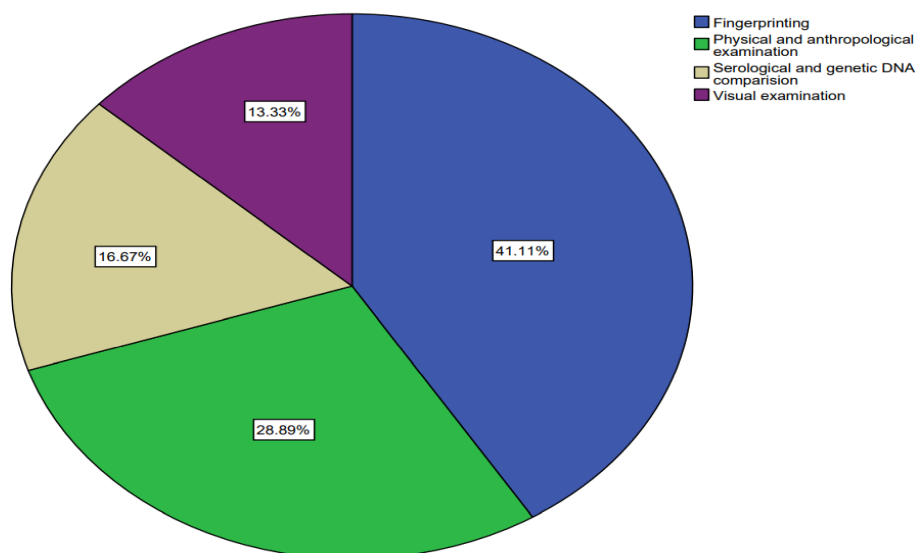


FIGURE 4: This pie chart represents that 41.11% of people responded that DNA fingerprinting is the first step in identifying the unclaimed dead bodies (blue). 28.89% answered that physical and anthropological examination is the 1<sup>st</sup> step (green). 16.67% responded to the serological and genetic DNA comparison as the 1<sup>st</sup> step (sand). 13.33% responded that visual examination is the 1<sup>st</sup> step in identification of unclaimed dead bodies (purple).

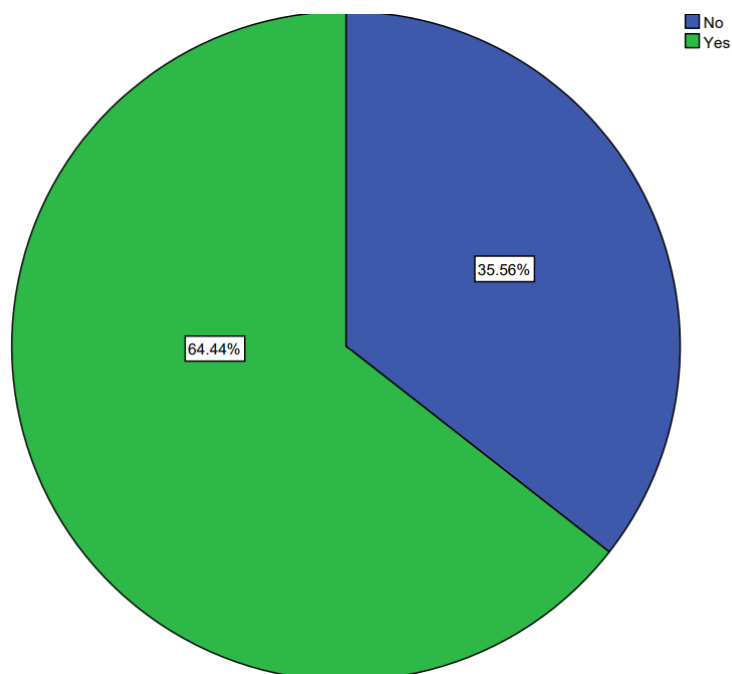


FIGURE 5 : This Pie chart represents the responses given by the participants on asking about their opinion on usage of Barr bodies to the sex determination. Green represents Yes and Blue represents No. Majority 64.44% of the people responded positively and 35.56% of the respondents responded negatively.

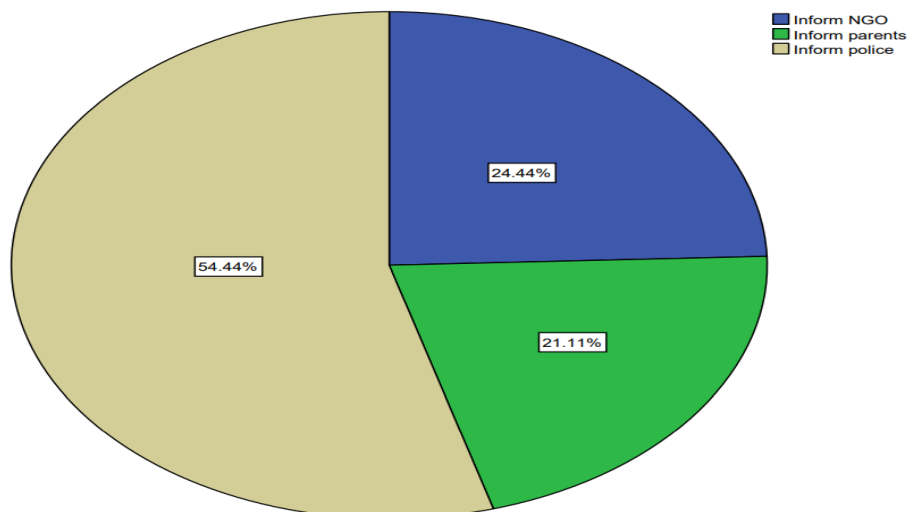


FIGURE 6: This pie chart represents that 54.44% of the respondents answered that they will inform police in case if they find any sign or symptom of child abuse (sandal). 24.44% of the population will inform the NGO (blue). 21.11% of the population will inform parents (green).

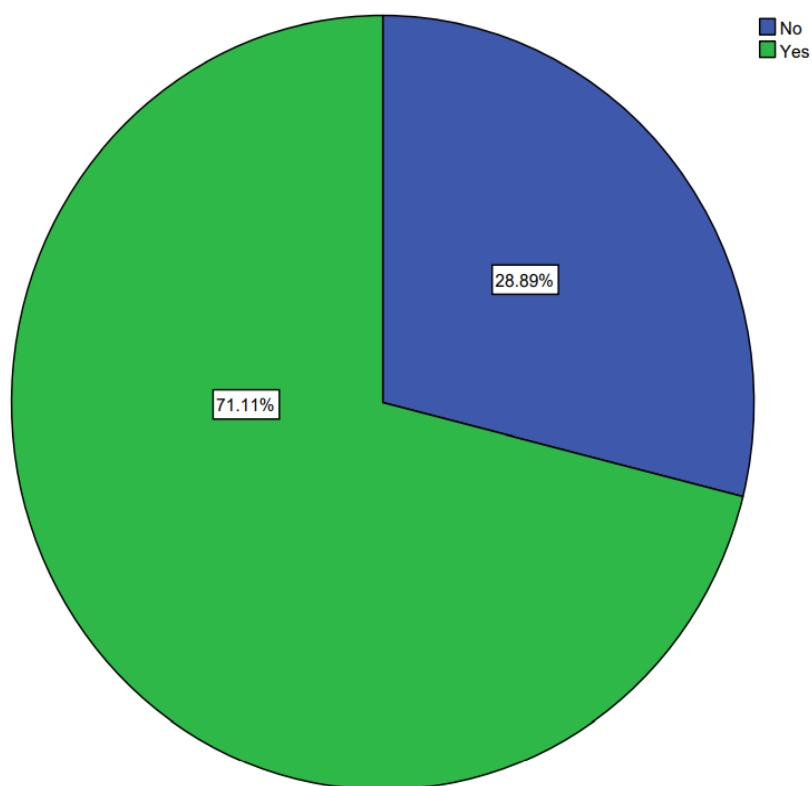


FIGURE 7: This pie chart represents that 71.11% of the population agreed that the court accepts the witness of dentists as an expert witness (green) . 28.89% of the population disagreed with this (blue)

## **DISCUSSION :**

Majority 27.78% of females and 13.33% of males are aware that DNA fingerprinting is the first step in identification of unclaimed bodies. Males and females answered equally (20%) that bite mark analysis is one of the commonest forms of evidence presented in the court. Majority of females 46.67% answered that teeth can act as a source of DNA. but 24.44% of males answered that teeth can be used as a source of DNA. Teeth and bones are sources of DNA available for identification of degraded human remains. The unique composition of teeth and its location in the jawbone provide additional protection to DNA compared to that of bones shaping them, a preferred source of DNA in many cases. Post mortem changes in the composition of teeth, and the location and diagenesis of DNA within them are poorly known (27). About 41.11% of females are more aware than 23.33% males that sex determination can be done using barr bodies. Generally Sex of the individual can be determined based on the morphology of canines. It can also be determined by using X and Y chromosomes in the cells. X chromatin in its inactivated form is present as a mass in the nuclear membrane in females called Barr body as it was first discovered by Barr and Bertem. Females have barr bodies and are called chromatin positive and males are devoid of barr bodies and are said to be chromatin negative. Similar to X chromosome, Y chromosome (F bodies) can also be studied for sex determination of males.(28). Majority 57.78% of females and 21.11% of males are law professionals and are aware that enamel, dentin and cementum can be used as a source for identification of age. Cementum is a connective tissue that encompasses teeth established in gradual layers, bringing about the presence of concentric lines in the cementum, which are known as salter lines, which can be likened with years. Each pair of lines compares to one year of life and it establishes a natural record that can be utilized to appraise the age of an individual Cementum is framed because of a constant interaction all through life and it has been appeared to significantly increase in thickness between the ages of 20 and 60 years With maturing, the pulpal cavity decreases, in view of nonstop testimony of auxiliary dentin. Moreover, postmortem changes in pulp are seen very late, and also pulp remains one of the most protected tissues and therefore could be readily available for examination . Subsequently, its sum can be utilized to assess the age of an individual. Auxiliary dentin statement is ordinary when it isn't affected by dental caries or other physical/substance abuses to the tooth (29). About 35.56% of females and 18.89% inform police in case they find any symptoms of child abuse. Majority of females 46.67% answered that forensic odontology is a part of forensic medicine but 23.33% of males opposed this answer. 51.11% of the females (law professionals) answered that the court accepts the evidence of a dentist as an expert evidence. Majority 57.78% of females are more aware than 22.22% of males that lip print analysis is a new tool for human identification. The example of wrinkles on the lips has singular qualities as fingerprints. The wrinkles and furrows on the labial mucosa (called sulci labiorum) structure a trademark design called lip prints, the investigation of which is alluded to as Cheiloscopy(30).

## **CONCLUSION:**

Forensic odontology is a branch of forensic science. It uses scientific methods as they relate to the teeth and jaw to identify unknown deceased individuals. Because teeth are so strong, odontologists can use them to identify the deceased even when the body has been destroyed. The aim of this survey is to find the level of awareness and value of forensic odontology among the legal professionals. In this study it is evident that the law professionals are moderately aware of the importance of forensic odontology. There is a knowledge gap among some sections of the populace studied which opens the avenue of increasing the awareness by means of educational outreach approaches.

#### **ACKNOWLEDGEMENTS:**

The authors would like to thank all the participants for their valuable support and Saveetha Dental College for their support to conduct the study.

#### **CONFLICT OF INTEREST:**

All the authors declare that there was no conflict of interest in the present study.

#### **AUTHOR CONTRIBUTIONS :**

Ashwin Krishna B: Literature search, data collection, analysis, manuscript drafting .  
Dr. Gheena S, Dr. Sandhya: Data verification, manuscript drafting.

#### **SOURCE OF FUNDING**

The present study was supported by the following agencies,

- Saveetha Dental College and Hospitals,
- Saveetha Institute of Medical and Technical Science,
- Saveetha University and
- Arora Multispeciality Dental Hospital and Implant Center.

#### **REFERENCES:**

1. Fullár A, Kutnyánszky V, Leiner N. Identification of burglars using foil impressioning based on tool marks and DNA evidence. *Forensic Sci Int.* 2020 Nov;316:110524.
2. Trengrove HG. Forensic odontology in disaster victim identification [Internet]. *Forensic Odontology.* 2016. p. 286–335. Available from: <http://dx.doi.org/10.1002/9781118864418.ch9>
3. Abdul NS, Alhazani L, Alruwail R, Aldres S, Asil S. Awareness of forensic odontology among undergraduate, graduate, and postgraduate dental students in Riyadh, Saudi Arabia: A knowledge-, attitude-, and practice-based study. *J Forensic Dent Sci.* 2019 Jan;11(1):35–41.
4. Schrader BA. History and Scope of Forensic Odontology [Internet]. *Forensic Odontology.* 2018. p. 19–23. Available from: <http://dx.doi.org/10.1016/b978-0-12-805198-6.00002-5>
5. Souviron R, Haller L. Bite mark evidence: bite mark analysis is not the same as bite mark comparison or matching or identification [Internet]. Vol. 4, *Journal of Law and the Biosciences.* 2017. p. 617–22. Available from: <http://dx.doi.org/10.1093/jlb/lxx026>
6. Stark MM. Medical Malpractice: Clinical Forensic Medicine [Internet]. *Encyclopedia of Forensic and Legal Medicine.* 2016. p. 384–8. Available from: <http://dx.doi.org/10.1016/b978-0-12-800034-2.00276-7>
7. Princeton B, Santhakumar P, Prathap L. Awareness on Preventive Measures taken by Health Care Professionals Attending COVID-19 Patients among Dental Students. *Eur J Dent.* 2020 Dec;14(S 01):S105–9.
8. Mathew MG, Samuel SR, Soni AJ, Roopa KB. Evaluation of adhesion of *Streptococcus mutans*,



- plaque accumulation on zirconia and stainless steel crowns, and surrounding gingival inflammation in primary molars: randomized controlled trial. *Clin Oral Investig.* 2020 Sep;24(9):3275–80.
9. Sridharan G, Ramani P, Patankar S, Vijayaraghavan R. Evaluation of salivary metabolomics in oral leukoplakia and oral squamous cell carcinoma. *J Oral Pathol Med.* 2019 Apr;48(4):299–306.
  10. R H, Hannah R, Ramani P, Ramanathan A, Jancy MR, Gheena S, et al. CYP2 C9 polymorphism among patients with oral squamous cell carcinoma and its role in altering the metabolism of benzo[a]pyrene [Internet]. Vol. 130, *Oral Surgery, Oral Medicine, Oral Pathology and Oral Radiology.* 2020. p. 306–12. Available from: <http://dx.doi.org/10.1016/j.oooo.2020.06.021>
  11. Antony JVM, Ramani P, Ramasubramanian A, Sukumaran G. Particle size penetration rate and effects of smoke and smokeless tobacco products - An invitro analysis. *Heliyon.* 2021 Mar 1;7(3):e06455.
  12. Sarode SC, Gondivkar S, Sarode GS, Gadbaile A, Yuwanati M. Hybrid oral potentially malignant disorder: A neglected fact in oral submucous fibrosis. *Oral Oncol.* 2021 Jun 16;105390.
  13. Hannah R, Ramani P, WM Tilakaratne, Sukumaran G, Ramasubramanian A, Krishnan RP. Author response for “Critical appraisal of different triggering pathways for the pathobiology of pemphigus vulgaris—A review” [Internet]. Wiley; 2021. Available from: <https://publons.com/publon/47643844>
  14. Chandrasekar R, Chandrasekhar S, Sundari KKS, Ravi P. Development and validation of a formula for objective assessment of cervical vertebral bone age. *Prog Orthod.* 2020 Oct 12;21(1):38.
  15. Subramanyam D, Gurunathan D, Gaayathri R, Vishnu Priya V. Comparative evaluation of salivary malondialdehyde levels as a marker of lipid peroxidation in early childhood caries. *Eur J Dent.* 2018 Jan;12(1):67–70.
  16. Jeevanandan G, Thomas E. Volumetric analysis of hand, reciprocating and rotary instrumentation techniques in primary molars using spiral computed tomography: An in vitro comparative study. *Eur J Dent.* 2018 Jan;12(1):21–6.
  17. Ponnulakshmi R, Shyamaladevi B, Vijayalakshmi P, Selvaraj J. In silico and in vivo analysis to identify the antidiabetic activity of beta sitosterol in adipose tissue of high fat diet and sucrose induced type-2 diabetic experimental rats. *Toxicol Mech Methods.* 2019 May;29(4):276–90.
  18. Sundaram R, Nandhakumar E, Haseena Banu H. Hesperidin, a citrus flavonoid ameliorates hyperglycemia by regulating key enzymes of carbohydrate metabolism in streptozotocin-induced diabetic rats. *Toxicol Mech Methods.* 2019 Nov;29(9):644–53.
  19. Alsawalha M, Rao CV, Al-Subaie AM, Haque SKM, Veeraraghavan VP, Surapaneni KM. Novel mathematical modelling of Saudi Arabian natural diatomite clay. *Mater Res Express.* 2019 Sep 4;6(10):105531.

20. Yu J, Li M, Zhan D, Shi C, Fang L, Ban C, et al. Inhibitory effects of triterpenoid betulin on inflammatory mediators inducible nitric oxide synthase, cyclooxygenase-2, tumor necrosis factor-alpha, interleukin-6, and proliferating cell nuclear antigen in 1, 2-dimethylhydrazine-induced rat colon carcinogenesis. *Pharmacogn Mag.* 2020;16(72):836.
21. Shree KH, Hema Shree K, Ramani P, Herald Sherlin, Sukumaran G, Jeyaraj G, et al. Saliva as a Diagnostic Tool in Oral Squamous Cell Carcinoma – a Systematic Review with Meta Analysis [Internet]. Vol. 25, *Pathology & Oncology Research*. 2019. p. 447–53. Available from: <http://dx.doi.org/10.1007/s12253-019-00588-2>
22. Zafar A, Sherlin HJ, Jayaraj G, Ramani P, Don KR, Santhanam A. Diagnostic utility of touch imprint cytology for intraoperative assessment of surgical margins and sentinel lymph nodes in oral squamous cell carcinoma patients using four different cytological stains. *Diagn Cytopathol.* 2020 Feb;48(2):101–10.
23. Karunakaran M, Murali P, Palaniappan V, Sivapathasundharam B. Expression and distribution pattern of podoplanin in oral submucous fibrosis with varying degrees of dysplasia – an immunohistochemical study [Internet]. Vol. 42, *Journal of Histotechnology*. 2019. p. 80–6. Available from: <http://dx.doi.org/10.1080/01478885.2019.1594543>
24. Sarode SC, Gondivkar S, Gadail A, Sarode GS, Yuwanati M. Oral submucous fibrosis and heterogeneity in outcome measures: a critical viewpoint. *Future Oncol.* 2021 Jun;17(17):2123–6.
25. Raj Preeth D, Saravanan S, Shairam M, Selvakumar N, Selestin Raja I, Dhanasekaran A, et al. Bioactive Zinc(II) complex incorporated PCL/gelatin electrospun nanofiber enhanced bone tissue regeneration. *Eur J Pharm Sci.* 2021 May 1;160:105768.
26. Prithviraj N, Yang GE, Thangavelu L, Yan J. Anticancer Compounds From Starfish Regenerating Tissues and Their Antioxidant Properties on Human Oral Epidermoid Carcinoma KB Cells. In: PANCREAS. LIPPINCOTT WILLIAMS & WILKINS TWO COMMERCE SQ, 2001 MARKET ST, PHILADELPHIA ...; 2020. p. 155–6.
27. Higgins D, Austin JJ. Teeth as a source of DNA for forensic identification of human remains: a review. *Sci Justice.* 2013 Dec;53(4):433–41.
28. Whittaker DK, Llewelyn DR, Jones RW. Sex determination from necrotic pulpal tissue. *Br Dent J.* 1975 Nov 18;139(10):403–5.
29. Gupta P, Kaur H, Shankari G S M, Jawanda MK, Sahi N. Human age estimation from tooth cementum and dentin. *J Clin Diagn Res.* 2014 Apr;8(4):ZC07–10.
30. Dineshshankar J, Ganapathi N, Yoithaprabhunath TR, Maheswaran T, Kumar MS, Aravindhana R. Lip prints: Role in forensic odontology. *J Pharm Bioallied Sci.* 2013 Jun;5(Suppl 1):S95–7.