

Histologic Alterations and Immunohistochemical Expression of Na-K ATPase in Placental Tissue of Patients with Pre-eclampsia

Hawraa Saad Al-Kawaz ^{(1)*}, Mazin J. Mousa ⁽²⁾, Oda M. Yasser ⁽³⁾

⁽¹⁾ Department of Medical Laboratories Techniques, Al-Mustaqbal University College, Babylon, Iraq.

hawraa.saad@mustaqbal-college.edu.iq.

⁽²⁾ College of Pharmacy, University of Babylon, Babylon, P.O. 51002, Iraq. *phar.mazin.jaafar@uobabylon.edu.iq.*⁽³⁾

Department of Chemistry, College of Science, University of Babylon, Babylon, P.O. 51002, Iraq.

Abstract

Background: Pre-eclampsia is the most popular disorder that affects first pregnancies. The clinical manifestations are highly variable, but hypertension and proteinuria are usually seen. Pre-eclampsia is a multisystem illness, but its aetiology is poorly understood. Pre-eclampsia has linked to a variety of system abnormalities, including ion transport disorders in neonatal, maternal, and placental cell lines.

Objective: The aim of the current study is to estimate the expression of placental Na-K ATPase in pre-eclampsia patients compared with normal pregnancies by immunohistochemistry, as well as other histological parameters.

Design and Methods: This was a case-control study consisting of 90 cases that were divided into two groups, 50 normal pregnancies (control), and 40 pre-eclampsia (patients). The current study included histologic examination of placental tissue along with immunohistochemical expression of Na-K ATPase was carried out in all samples.

Results: Histomorphometric changes revealed significant differences for the following parameters: syncytial knots, stromal fibrosis, and the number of capillaries in terminal villi. While the results of immunohistochemical expression of placental Na-K ATPase revealed a significant difference in expression of cytotrophoblasts and decidual cells in pre-eclamptic placental tissue.

Conclusion: This study concluded various placental changes detected by histological and immunohistochemical techniques.

Keywords: Pre-eclampsia, Hypertension, Immunohistochemical, Placenta Tissue.

1. Introduction

Pre-eclampsia (PE) is a disorder of human pregnancy diagnosed by proteinuria more than 300 mg/day and hypertension [1]. It is a serious disorder that may lead to mother and fetal morbidity and death. The condition starts after twenty weeks of pregnancy [2]. Pre-eclampsia is classified as mild or severe based on the severity of hypertension, the amount of proteinuria, and the extent to which other organ systems are impacted [3]. Although the exact cause of pre-eclampsia is unclear, except that the pathogenesis is thought to occur in two stages. The first stage starts in the placenta is a pre-clinical condition characterized by abnormal trophoblastic vascular of uterine arteries, resulting in placental hypoxia. While the second stage is characterized by an abnormal maternal endothelial response, resulting in hypertension, proteinuria, and edema [4,5].

So that, factors that have been likely to play a role in the etiology of pre-eclampsia are included: first: Abnormal Trophoblastic Invasion, the extravillous trophoblast proliferates from an anchoring villous during normal placental implantation. In the inner part of the myometrium, the cytotrophoblast invades the uterine spiral arteries. Invasion of the spiral arteries is associated with tunica media degeneration and fibrinoid material replacement, resulting in loss of resistance and marked dilatation of the spiral artery, as

well as increased intervillous blood flow [6]. In pre-eclamptic patients, the placenta suffers from defective implantation. The disease process is composed of two phases. The first phase is characterized by patchy trophoblast invasion so that the spiral arteries retain their muscular walls which will prevent the development of high-flow, low-impedance uteroplacental circulation [7]. The pre-eclamptic placenta grows high resistance, resulting in reduced flow of blood and inefficient perfusion. These will result in placental ischemia and hypoxia. This most likely results in the formation of reactive oxygen species. When the body's normal endogenous antioxidants are depleted, oxidative stress occurs. This is most likely central to the clinical syndrome of pre-eclampsia [8].

While the second factor included Inflammatory Factors: endothelial cell dysfunction may be caused by an overly activated state of leukocytes in the maternal circulation, according to one theory [9]. Briefly, cytokines like tumor necrosis factor- α (TNF- α) and interleukins (IL) may contribute to the oxidative stress associated with PE [10]. This is distinguished by reactive oxygen species and free radicals, which result in the formation of self-propagating lipid peroxides [11]. These, in turn, produce highly toxic radicals that cause endothelial cell injury, alter nitric oxide production, and disrupt prostaglandin balance. Other effects of oxidative stress include the production of lipid-laden macrophage foam cells, which is seen in atherosclerosis; activation of macrovascular coagulation, which is expressed by thrombocytopenia; and increased capillary permeability, which is manifested by edema and proteinuria [12].

Also, the third factor involves Immunological Changes: there is maternal immune tolerance to parentally derived placental and fetal antigens. PE syndrome is caused by a loss of tolerance or a disruption in its regulation [13]. There are numerous inferential data that point to an immune-mediated disorder. For example, the risk of PE is significantly increased when the formation of blocking antibodies to placental antigenic sites is hampered. In this case, the first pregnancy would be riskier [14]. Some women have elevated serum levels of antiangiogenic factors. One of these factors, soluble FMS-like tyrosine kinase 1 (sFLT-1) [15]. sFLT-1 is an antiangiogenic factor expressed as an alternatively spliced VEGFR-1 variant that lacks both the transmembrane and cytoplasmic domains. sFlt-1 linked to VEGF and PlGF, inhibiting angiogenesis via VEGFR [16]. So, another factor included genetic factors: for daughters of pre-eclampsia mothers, the risk of PE is 20% to 40%; for sisters of pre-eclampsia women, the risk is 11 to 37%; and for twin pregnancies, the risk is 22 to 47 percent [17,23-38]. Finally, the last factor involves nutritional factors: in general, a diet high in antioxidant-rich fruits and vegetables is associated with lower blood pressure [18]. The incidence of PE was most doubled in women whose daily ascorbic acid consumption was less than 85 mg [19]. The aim of the current study is to estimate the expression of placental Na-K ATPase in pre-eclampsia patients compared with normal pregnancies by immunohistochemistry, as well as other histological parameters.

2. Experimental

2.1. Ethics Issues

The current sampling procedure was approved by the Babylon health directorate's research ethics committee. This work was permitted from the scientific committee of maternity and children hospital in Babylon governorate, Hilla city.

2.2. Study Design

This was a case-control study consisting of 90 cases, and these cases were divided into two groups, 50 normal pregnancy (control) and 40 pre-eclampsia (patients).

2.3. Chemicals

All chemical substances were obtained from commercially available sources.

2.4. Collection of Placental Samples

The placenta samples were collected from all pregnant subjects after delivery by using a disposable cup. A small piece of placenta tissue was placed in a cup and preserved normal saline until delivered to the laboratory. Placental samples were sonicated by ultrasonic cleaner for 15min at room temperature for obtaining cell suspension for DNA extraction. After sonication, 10 mL from the normal saline supernatant was transferred to a plain tube. The supernatant was centrifuged for 10 min at 16000 g then, the supernatant was discarded, and the precipitate stored at -20 C for genetic study. Whereas the remaining placental tissue was preserved in 10% formal-saline for histological and immunohistochemically study.

2.5. Preparation of Histological Sections

Placental tissue samples were taken with a thickness of 2 mm. Tissue processing was done according to [20]

2.6. Immunohistochemistry Staining Protocol

The immunohistochemistry detection kit is a reliable and convenient tool to identify specified gene expression on tissues. In this study, the procedure of immunohistochemistry staining was carried out according to a kit from Bio SB, USA [20], and using Na-K ATPase antibody as a marker. This method includes many steps illustrated as following

1. The section with paraffin embedding tissue was cut by microtome at 4 microns.
2. The slides were put in an incubator at 60 °C for overnight.
3. The dewaxing was removed by xylene three times, each for 5 min.
4. The slides were dehydrated by ethanol alcohol, by using different concentrations of 100%, 90%, 70%, 50% each change of concentration incubated for 5 min.
5. The retrieval solution was put in the water bath and when the temperature was 65 °C the slides were put and when temperature 99 °C was left for 20 min.
6. The slides were removed from the retrieval solution and let cold then, washed with buffer solution three times.
7. The slides were made with peroxidase solution for 5 min. then, washed with buffer solution three times.
8. The primary antibody was added for 40 min. then, washed with buffer solution three times.
9. The secondary antibody was permitted to link for 15 min. then, washed with buffer solution three times.

10. The HRP was applied for 15 min. then, washed with buffer solution three times.
11. The DAB was added for 15 min. then, washed with buffer solution 3 times.
12. Counter stain was added on the slides (Harris's Hematoxylin was used to stain the nucleus, and Eosin Y was used to stain cytosol) for 1 min.
13. The slides were washed with D.W. and repeated steps of rehydration and clearing.
14. The cover slide was mounted, then examined by a microscope.

2.6.1. Evaluation of Immunohistochemistry Staining Results

Immunohistochemistry was given intensity and percentage scores, based on the intensity of positive staining and number of cells staining, respectively. A scale of (0-4) was used to measure relative intensity with (0) corresponding to no detectable IHC reaction and (1-4) equivalents to low, moderate, and high, respectively. Positive cells were counted in ten different fields at 1000 X for each sample and the average of positive cells of the ten fields was determined assigning cases to one of the following scores as below

1. **Score 0 (Negative):** No stained cells.
2. **Score 1 (+):** The positive cells (stained) represented 10% of total cells.
3. **Score 2 (++):** The positive cells (stained) represented more than 10% to 30% of total cells.
4. **Score 3 (+++):** The positive cells (stained) represented more than 30% to 50% of total cells.
5. **Score 4 (++++):** The positive cells (stained) represented more than 50% of total cells.

2.6.2. Photography

Photography was done using digital camera ScopelImage 9.0 (MDCE-5C) with high effective and 24-bit true color or higher, resolution 1024 Mb or more.

2.7. Statistical Analysis

The analysis of results was carried out using Statistical Package of the Social Sciences (SPSS®) version 26 to get on the variables as the mean, standard deviation, T-test. A p-value of ≤ 0.05 was considered significant.

3. Results and Discussion

Pre-eclampsia is a multisystem and multifactorial disease that affects both mother and fetus by intrauterine growth restriction and vascular dysfunction [21]. Although there is much ongoing research in the field of pre-eclampsia the definitive cause of this condition is not yet known. Several causes of this syndrome have been postulated, including abnormal formation of the placenta, chemical imbalances, genetic factors, and immunological mechanisms [22].

The results of the histomorphometric in placental tissue are shown in Table (1). The results showed syncytial knots significantly higher in pre-eclampsia patients compared with control group. Also, the results of stromal fibrosis showed significantly higher in pre-eclampsia patient compared with control group. As well as the results of the number of capillaries in terminal villi appeared significantly higher in pre-eclampsia patients compared with control group.

Table (1): Histomorphometric Finding in Placental Tissue for Pre-eclampsia Patients Compared with Normal Pregnancies

No.	Histological Lesion	Control Mean ± SD	Pre-eclampsia Mean ± SD	P-value
	Calcifications	0.23 ± 0.61	0.21 ± 0.67	0.96
	Fibrinoid Necrosis	3.80 ± 1.40	4.1 ± 2.90	0.073
	Number of Capillaries in Terminal Villi	2.30 ± 1.22	4.90 ± 1.54	< 0.001*
	Placental Infarction	0.13 ± 0.34	0.23 ± 0.64	0.427
	Stromal Fibrosis	0.42 ± 0.53	2.02 ± 0.71	0.002*
	Syncytial Knots	21.60 ± 3.10	26.25 ± 5.1	0.013*

*p value < 0.05 was significant

While the results of fibrinoid necrosis showed no significance in the present study between pre-eclampsia patients compared with control group. Also, the results of placental infarction showed no significance in pre-eclampsia patient compared with control group. As well as the results of the calcifications appeared no significance in pre-eclampsia patients compared with control group.

IHC is an invaluable validation tool in biomarker discovery. However, considering the excessive number of existing studies proposing novel IHC biomarkers, markers validated in several clinical cohorts are extremely few, stressing the need to raise quality standards for clinical biomarker studies. Even if results can be reproduced, the transition towards a routinely used marker is complex. For a new factor to become of potential value in the clinic, it has to add an important value compared with other already used factors.

The results of immunohistochemical staining of antibody Na-K ATPase of placental tissue as shown in Tables (2), (3) and Figures (1), (2), (3), (4) and (5) for control and pre-eclampsia patient showed higher percent significantly for cytotrophoblasts at >75% and <50% in pre-eclampsia patient compared with the control group. Also, the results appeared syncytial knots higher present significantly at >50% in pre-eclampsia patients compared with the control group. As well as the results showed decidual cells higher present significantly at 30-50% in pre-eclampsia patients compared with the control group. While the results of spiral arteriolar endothelial cells and villous arteriolar endothelial cells showed no significance in the present study between pre-eclampsia patients compared with control group.

Table (2): Expersion of Na-K ATPase in Cytotrophoblats Cell and Syncytial knots of Plasenta by Immunohistochemical

	Cytotrophoblats			Syncytial knots		
	<50%	50-75%	>75%	<30%	30-50%	>50%
Control	1 (2%)	42 (84%)	4 (8%)	14 (28%)	32 (64%)	4 (4%)
Pre-eclampsia	2 (6.06%)	6 (18.18%)	25 (75.75%)	10 (30.3%)	17 (51.5%)	5 (18.18%)

P-value	<0.001	0.03*	<0.001*	0.75	0.53	<0.001*
---------	--------	-------	---------	------	------	---------

Table (3): Expression of Na-K ATPase in Spiral Arteriolar Endothelial Cells, Villous Arteriolar Endothelial Cells and Decidual Cells of Placenta by Immunohistochemical

	Spiral Arteriolar Endothelial Cells			Villous Arteriolar Endothelial Cells			Decidual Cells		
	<10%	10-30%	>30%	<10%	10-30%	>30%	<30%	30-50%	>50%
Control	13 (26%)	14 (28%)	23 (47%)	16 (32%)	20 (40%)	14 (28%)	31 (62%)	10 (20%)	9 (18%)
Pre-eclampsia	9 (27.27%)	12 (36.36%)	12 (36.36%)	8 (24.24%)	13 (39.39%)	12 (36.36%)	4 (12.12%)	11 (33.33%)	8 (24.24%)
P-value	0.45	0.702	0.38	0.34	0.64	0.81	0.14	<0.001	0.946

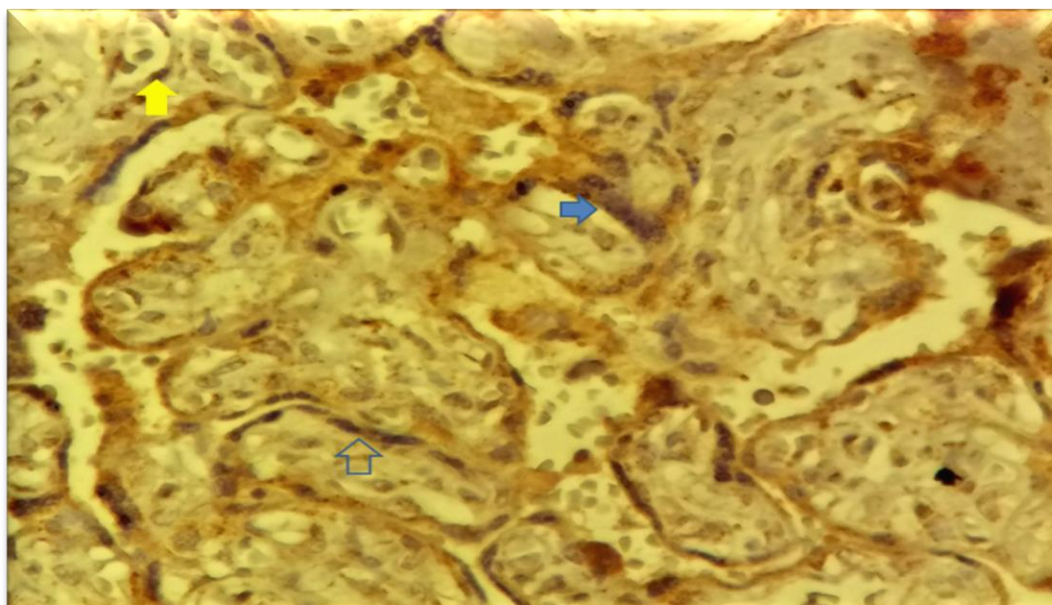


Figure (1): Immunohistochemical Staining of Placental Tissue for Control Showing Positive Staining of Syncytial Knots (Solid Blue Arrow) and Cytotrophoblasts (Empty Blue Arrow), with Staining of Endothelial Cells (Yellow Arrow)

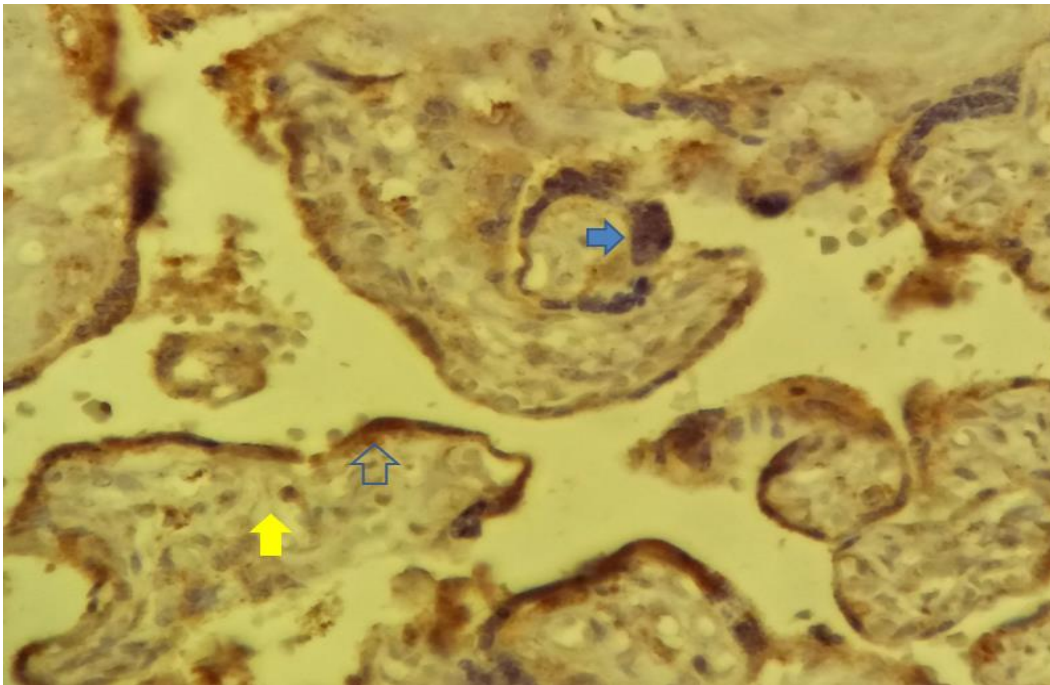


Figure (2): Immunohistochemical Staining of Placental Tissue for Pre-eclampsia Showing Positive Staining of Syncytial Knots (Solid Blue Arrow) and Cytotrophoblats (Empty Blue Arrow), with Staining of Endothelial Cells (Yellow Arrow)

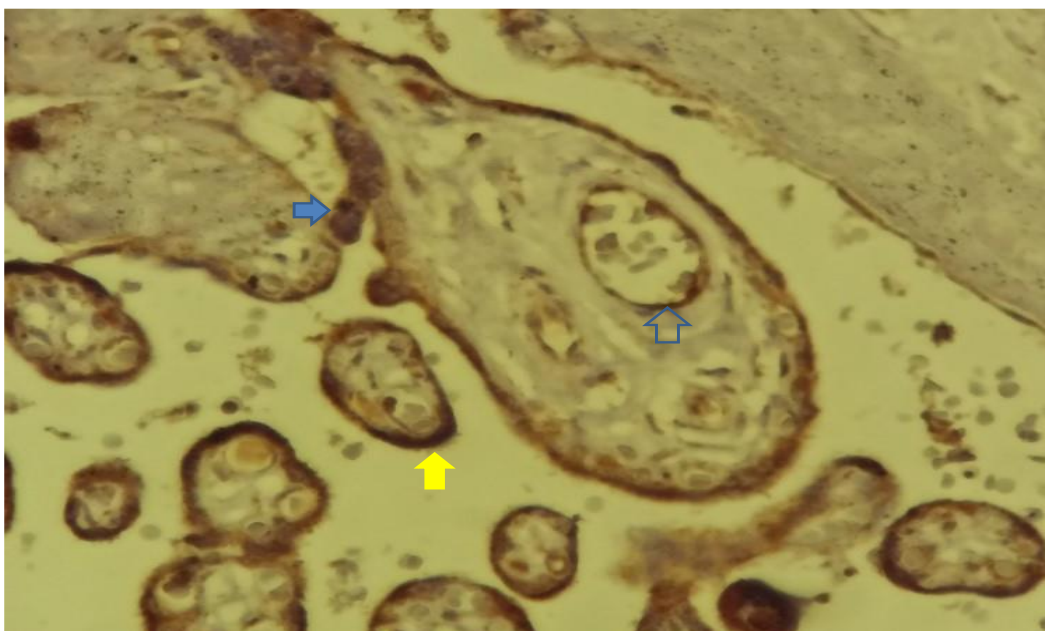


Figure (3): Immunohistochemical Staining of Placental Tissue for Pre-Eclampsia Showing Positive Staining of Syncytial Knots (Solid Blue Arrow) and Cytotrophoblats (Empty Blue Arrow), with Staining of Endothelial Cells (Yellow Arrow)

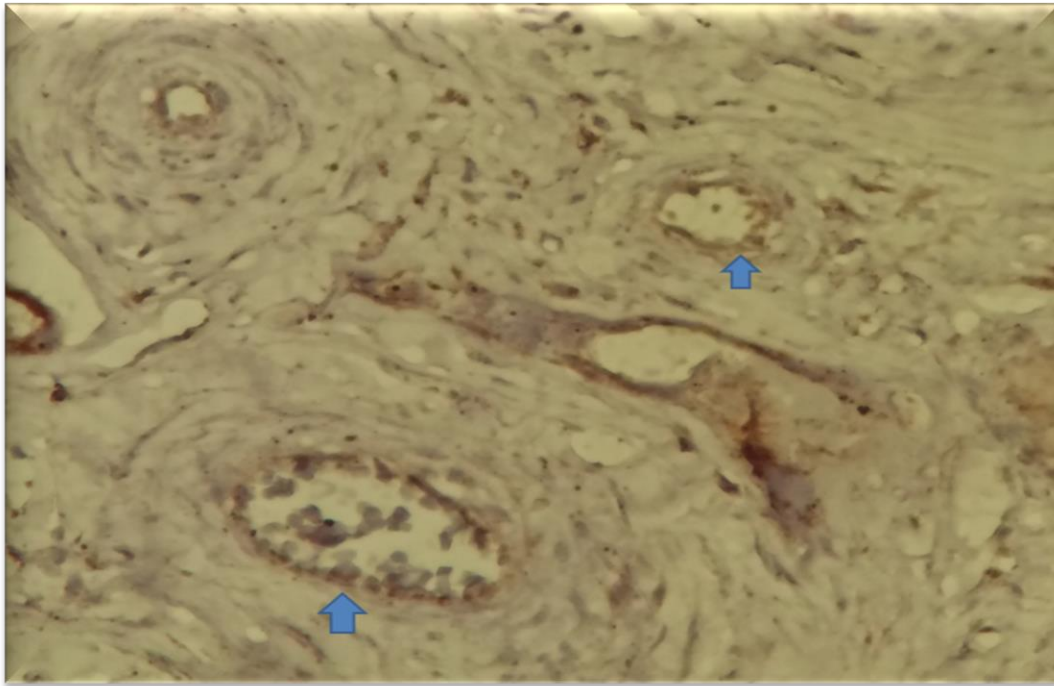


Figure (4): Immunohistochemical Staining of Placental Tissue for Control with Anti Na-K ATPase of Spiral Arterioles Showing Thin Muscular Wall and Positive Endothelial Cell

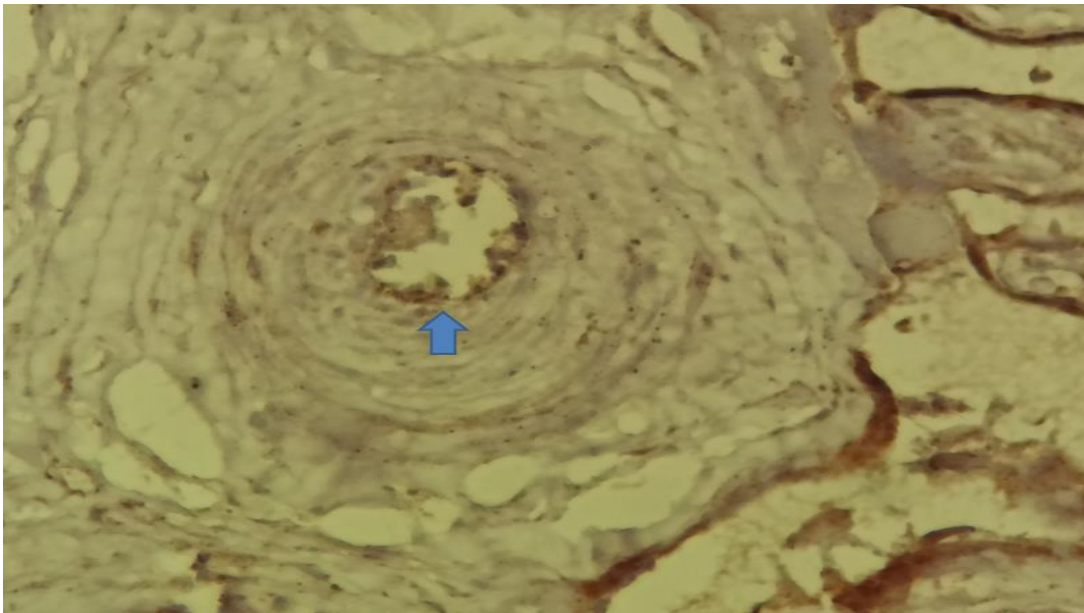


Figure (5): Pre-eclampsia: Immunohistochemical staining with anti-Na-K ATPase of spiral arterioles showing thick arteriosclerosis and positive endothelial staining

4. Conclusions

This study concluded various placental changes detected by histological and immunohistochemical techniques. Histomorphometric changes revealed significant differences for the following parameters: syncytial knots, stromal fibrosis, and the number of capillaries in terminal villi. While the results of immunohistochemical expression of placental Na-K ATPase revealed a significant difference in expression of cytotrophoblasts and decidual cells in pre-eclamptic placental tissue.

5. Acknowledgements

We thank our colleagues at the University of Babylon/College of Science and College of Pharmacy for their technical supporting, comments, and help regarding our study.

6. Conflicts of interest

The authors declare no conflict of interest.

References

1. Bramham K, Poli-de-Figueiredo CE, Seed PT, Briley AL, Poston L, Shennan AH, Chappell LC. Association of proteinuria threshold in pre-eclampsia with maternal and perinatal outcomes: a nested case control cohort of high risk women. *PloS one*. 2013;8(10):e76083.
2. Seely EW, Ecker J. Chronic hypertension in pregnancy. *Circulation*. 2014;129(11):1254-61.
3. Hacker NF, Gambone JC, Hobel CJ. Hacker and Moore's essentials of obstetrics and gynecology. Elsevier Health Sciences; 2015.
4. Borzychowski AM, Sargent IL, Redman CW. Inflammation and pre-eclampsia. In *Seminars in fetal and neonatal medicine*, WB Saunders 2006; 11(5): 309-316.
5. Shanmugalingam R, Hennessy A, Makris A. Aspirin in the prevention of preeclampsia: the conundrum of how, who and when. *Journal of human hypertension*. 2019;33(1):1-9.
6. Carter AM, Enders AC, Pijnenborg R. The role of invasive trophoblast in implantation and placentation of primates. *Philosophical Transactions of the Royal Society B: Biological Sciences*. 2015;370: 1-15.
7. Roberts JM, Escudero C. The placenta in preeclampsia. *Pregnancy Hypertension: An International Journal of Women's Cardiovascular Health*. 2012;2(2):72-83.
8. Testa I, Rabini RA, Danieli G, Tranquilli AL, Cester N, Romanini C, Bertolu E, Mazzanti L. Abnormal membrane cation transport in pregnancy-induced hypertension. *Scandinavian journal of clinical and laboratory investigation*. 1988;48(1):7-13.
9. Faas MM, Schuiling GA, Linton EA, Sargent IL, Redman CW. Activation of peripheral leukocytes in rat pregnancy and experimental preeclampsia. *American journal of obstetrics and gynecology*. 2000;182(2):351-7.
10. Kalantar F, Rajaei S, Heidari AB, Mansouri R, Rashidi N, Izad MH, Mirahmadian M. Serum levels of tumor necrosis factor- α , interleukin-15 and interleukin-10 in patients with pre-eclampsia in

- comparison with normotensive pregnant women. *Iranian journal of nursing and midwifery research*. 2013;18(6):463-6.
11. Shahidi F, Zhong Y. Lipid oxidation and improving the oxidative stability. *Chemical society reviews*. 2010;39(11):4067-79.
 12. Manten GT, van der Hoek YY, Sikkema JM, Voorbij HA, Hameeteman TM, Visser GH, Franx A. The role of lipoprotein (a) in pregnancies complicated by pre-eclampsia. *Medical hypotheses*. 2005;64(1):162-9.
 13. Kenny LC, Kell DB. Immunological tolerance, pregnancy, and preeclampsia: the roles of semen microbes and the father. *Frontiers in medicine*. 2018;4:239.
 14. Labarrere CA. Acute atherosclerosis. A histopathological hallmark of immune aggression?. *Placenta*. 1988;9(1):95-108.
 15. Bdolah Y, Palomaki GE, Yaron Y, Bdolah-Abram T, Goldman M, Levine RJ, Sachs BP, Haddow JE, Karumanchi SA. Circulating angiogenic proteins in trisomy 13. *American journal of obstetrics and gynecology*. 2006;194(1):239-45.
 16. Maynard SE, Min JY, Merchan J, Lim KH, Li J, Mondal S, Libermann TA, Morgan JP, Sellke FW, Stillman IE, Epstein FH. Excess placental soluble fms-like tyrosine kinase 1 (sFlt1) may contribute to endothelial dysfunction, hypertension, and proteinuria in preeclampsia. *The Journal of clinical investigation*. 2003;111(5):649-58.
 17. Nilsson E, Salonen Ros H, Cnattingius S, Lichtenstein P. The importance of genetic and environmental effects for pre-eclampsia and gestational hypertension: a family study. *BJOG: An International Journal of Obstetrics and Gynaecology*. 2004;111(3):200-6.
 18. John JH, Ziebland S, Yudkin P, Roe LS, Neil HA. Effects of fruit and vegetable consumption on plasma antioxidant concentrations and blood pressure: a randomised controlled trial. *The lancet*. 2002;359:1969-74
 19. Zhang C, Williams MA, King IB, Dashow EE, Sorensen TK, Frederick IO, Thompson ML, Luthy DA. Vitamin C and the risk of preeclampsia: results from dietary questionnaire and plasma assay. *Epidemiology*. 2002;409-16.
 20. Bancroft JD, Gamble M, editors. *Theory and practice of histological techniques*. Elsevier health sciences; 2008.
 21. Al-Jameil N, Tabassum H, Al-Mayouf H, Aljohar HI, Alenzi ND, Hijazy SM, Khan FA. Analysis of serum trace elements-copper, manganese and zinc in preeclamptic pregnant women by inductively coupled plasma optical emission spectrometry: a prospective case controlled study in Riyadh, Saudi Arabia. *International journal of clinical and experimental pathology*. 2014;7(5):1900.
 22. Gathiram P, Moodley JJ. Pre-eclampsia: its pathogenesis and pathophysiology: review articles. *Cardiovascular journal of Africa*. 2016;27(2):71-8.
 23. JALIL, A. T., DILFY, S. H., KAREVSKIY, A., & NAJAH, N. (2020). Viral Hepatitis in Dhi-Qar Province: Demographics and Hematological Characteristics of Patients. *International Journal of Pharmaceutical Research*, 12(1). <https://doi.org/10.31838/ijpr/2020.12.01.326>
 24. Jalil, A. T., Kadhum, W. R., Khan, M. U. F., Karevskiy, A., Hanan, Z. K., Suksatan, W., ... & Abdullah, M. M. (2021). Cancer stages and demographical study of HPV16 in gene L2 isolated from cervical

- cancer in Dhi-Qar province, Iraq. *Applied Nanoscience*, 1-7. <https://doi.org/10.1007/s13204-021-01947-9>
25. Widjaja, G., Jalil, A. T., Rahman, H. S., Abdelbasset, W. K., Bokov, D. O., Suksatan, W., ... & Ahmadi, M. (2021). Humoral Immune mechanisms involved in protective and pathological immunity during COVID-19. *Human Immunology*. <https://doi.org/10.1016/j.humimm.2021.06.011>
 26. Moghadasi, S., Elveny, M., Rahman, H. S., Suksatan, W., Jalil, A. T., Abdelbasset, W. K., ... & Jarahian, M. (2021). A paradigm shift in cell-free approach: the emerging role of MSCs-derived exosomes in regenerative medicine. *Journal of Translational Medicine*, 19(1), 1-21. <https://doi.org/10.1186/s12967-021-02980-6>
 27. Saleh, M. M., Jalil, A. T., Abdulkereem, R. A., & Suleiman, A. A. Evaluation of Immunoglobulins, CD4/CD8 T Lymphocyte Ratio and Interleukin-6 in COVID-19 Patients. *TURKISH JOURNAL of IMMUNOLOGY*, 8(3), 129-134. <https://doi.org/10.25002/tji.2020.1347>
 28. Turki Jalil, A., Hussain Dilfy, S., Oudah Meza, S., Aravindhan, S., M Kadhim, M., & M Aljeboree, A. (2021). CuO/ZrO₂ nanocomposites: facile synthesis, characterization and photocatalytic degradation of tetracycline antibiotic. *Journal of Nanostructures*.
 29. Sarjito, Elveny, M., Jalil, A., Davarpanah, A., Alfakeer, M., Awadh Bahajjaj, A. & Ouladsmame, M. (2021). CFD-based simulation to reduce greenhouse gas emissions from industrial plants. *International Journal of Chemical Reactor Engineering*, (), 20210063. <https://doi.org/10.1515/ijcre-2021-0063>
 30. Marofi, F., Rahman, H. S., Al-Obaidi, Z. M. J., Jalil, A. T., Abdelbasset, W. K., Suksatan, W., ... & Jarahian, M. (2021). Novel CAR T therapy is a ray of hope in the treatment of seriously ill AML patients. *Stem Cell Research & Therapy*, 12(1), 1-23. <https://doi.org/10.1186/s13287-021-02420-8>
 31. Jalil, A. T., Shanshool, M. T. ., Dilfy, S. H. ., Saleh, M. M., & Suleiman, A. A. . (2021). HEMATOLOGICAL AND SEROLOGICAL PARAMETERS FOR DETECTION OF COVID-19. *Journal of Microbiology, Biotechnology and Food Sciences*, e4229. <https://doi.org/10.15414/jmbfs.4229>
 32. Vakili-Samiani, S., Jalil, A. T., Abdelbasset, W. K., Yumashev, A. V., Karpishev, V., Jalali, P., ... & Jadidi-Niaragh, F. (2021). Targeting Wee1 kinase as a therapeutic approach in Hematological Malignancies. *DNA repair*, 103203. <https://doi.org/10.1016/j.dnarep.2021.103203>
 33. NGAFWAN, N., RASYID, H., ABOOD, E. S., ABDELBASSET, W. K., AL-SHAWI, S. G., BOKOV, D., & JALIL, A. T. (2021). Study on novel fluorescent carbon nanomaterials in food analysis. *Food Science and Technology*. <https://doi.org/10.1590/fst.37821>
 34. Marofi, F., Abdul-Rasheed, O. F., Rahman, H. S., Budi, H. S., Jalil, A. T., Yumashev, A. V., ... & Jarahian, M. (2021). CAR-NK cell in cancer immunotherapy; A promising frontier. *Cancer Science*, 112(9), 3427. <https://doi.org/10.1111/cas.14993>
 35. Abosaooda, M., Wajdy, J. M., Hussein, E. A., Jalil, A. T., Kadhim, M. M., Abdullah, M. M., ... & Almashhadani, H. A. (2021). Role of vitamin C in the protection of the gum and implants in the human body: theoretical and experimental studies. *International Journal of Corrosion and Scale Inhibition*, 10(3), 1213-1229. <https://dx.doi.org/10.17675/2305-6894-2021-10-3-22>
 36. Jumintono, J., Alkubaisy, S., Yánez Silva, D., Singh, K., Turki Jalil, A., Mutia Syarifah, S., ... & Derkho, M. (2021). Effect of Cystamine on Sperm and Antioxidant Parameters of Ram Semen Stored at 4° C

- for 50 Hours. Archives of Razi Institute, 76(4), 923-931. <https://dx.doi.org/10.22092/ari.2021.355901.1735>
37. Raya, I., Chupradit, S., Kadhim, M. M., Mahmoud, M. Z., Jalil, A. T., Surendar, A., ... & Bochvar, A. N. (2021). Role of Compositional Changes on Thermal, Magnetic and Mechanical Properties of Fe-PC-Based Amorphous Alloys. *Chinese Physics B*. <https://doi.org/10.1088/1674-1056/ac3655>
38. Chupradit, S., Jalil, A. T., Enina, Y., Neganov, D. A., Alhassan, M. S., Aravindhan, S., & Davarpanah, A. (2021). Use of Organic and Copper-Based Nanoparticles on the Turbulator Installment in a Shell Tube Heat Exchanger: A CFD-Based Simulation Approach by Using Nanofluids. *Journal of Nanomaterials*. <https://doi.org/10.1155/2021/3250058>