

Analysis Of Predominant Pattern Of Lip Prints In Males Among Chennai Population- An Observational Study

Prithiksha N¹ , Dr. Reshma Poothakulath Krishnan² , Dr. Sandhya Sundar³

¹Undergraduate student Saveetha Dental College and Hospitals Saveetha Institute of medical and technical sciences Saveetha university, Chennai - 600077

²Senior Lecturer Department of Oral pathology Saveetha Dental College and Hospitals Saveetha Institute of medical and technical sciences Saveetha university, Chennai - 600077

³Department of Dental Anatomy Saveetha Dental College and Hospitals Saveetha Institute of medical and technical sciences Saveetha university, Chennai - 600077

ABSTRACT:

BACKGROUND: Cheiloscopy is a forensic investigation that deals with the examination of the system of furrows on the red or pink part of the human lips. Most of the crime detecting agencies are still unaware of the importance of the lip prints and it is not commonly attempted in the identification of the suspects.

AIM: To analyse the predominant pattern of the lip prints in males among the south indian population.

MATERIALS AND METHODS: The study consisted of 30 students only males aged from 18 to 21 years in the south indian population, India. Lip prints were obtained and visualized with the help of magnifying lenses. These lip prints were classified according to Tsuchihashi classification. The collected data were tabulated and analysed using SPSS Software (Version 5.0).

RESULTS: In the present study, the lip print patterns were analysed using the Tsuchihashi system of classification. The most predominant lip pattern found in our study was Type 1' (50%) followed by Type 2 (21%). When the age of the participant and the type of lip pattern were compared, the most common lip pattern of 19-20 years age group males was found to be type 1'. The difference was not statistically significant (chi square, P value = 0.8).

CONCLUSION: The present study concludes that Type 1' was the most predominant lip print pattern followed by Type 2 lip prints among males in Chennai. Lip prints can be used for gender determination in forensic odontology.

KEYWORDS: Cheiloscropy, Forensic odontology, Criminal issues, Lip prints, innovative technique, novel method

INTRODUCTION:

Cheiloscropy is the method of studying lip prints. Lip Prints vary in morphological pattern and sex determination(1)The study of lip prints termed as 'Cheiloscropy'. (2)This is derived from the Greek words 'CHELIOS' (lips) and 'SKOPEIN'.It is safe to assume that cheiloscropy,(3) in its present stage of development, has become a means of criminalistic identification dealing with lip prints(4). Because they may have the same qualifications as fingerprints,lip prints(5) are considered to be a new important area of use in criminal search and genetic studies (6). There are six types of lip prints namely Type 1,Type 1',Type 2,Type 3,Type 4,Type 5.In these the most predominant type of lip prints is type 1 pattern of lip print. (7)Identification of an individual is a prerequisite for certification of death and for personal, social, and legal reasons.

Lip prints are used in crime investigation, mass disasters and gender determination.(8) Like fingerprints these lip prints are also used in the crime investigation(9).Wrinkles and grooves in the labial mucosa form the lip prints. Fingerprints,MN blood system(10),DNA fingerprinting techniques for the crime investigation this lip prints are also very useful(11).Cheiloscropy is the technique or a method through which lip prints are investigated in the forensic studies.(12,13)Lip prints are new tool in the human identification during the criminal issues.(14)Lip prints will be unique for each and every individuals and it is unique and uniform throughout the lips(9,15). Aim of the study is to analyse the predominant pattern of the lip prints in males among the south indian population.

MATERIALS AND METHODS:


The cross sectional study was done at saveetha dental college, Chennai. 30 males of age group 18-21 were included in the study. To minimize the sampling bias, samples were randomly selected, The experimental protocol for obtaining the lip prints was explained to the study subjects, and informed consent was obtained. The lips of the participants were thoroughly cleaned using wet tissue paper and allowed to dry.

The lips were then outlined using a sharp lip liner pencil. Dark red colored lipstick was applied uniformly. An impression of the lips was made on a cellophane tape and transferred to white bond paper. The impression was analyzed using a magnifying lens. The 50 samples were classified as Type I, Type I', Type II, Type III, Type IV or Type V according to Tsuchihashi's classification (14). Tsuchihashi's

classification of the lip print samples was performed as follows: Type I, clear-cut grooves running vertically across the lips; Type I', straight grooves which disappear half way instead of covering the entire lip; Type II, fork grooves in their course; Type III, intersecting grooves; Type IV, reticulate grooves; Type V, undetermined. The collected data was tabulated and statistically analyzed with the help of the SPSS software version-5.0. For all the tests, a P value of 0.05 or less was considered to be statistically significant. To describe the data descriptive statistics frequency analysis and percentage analysis were used.

RESULTS: The study was composed of 30 males within the age group of 18 to 21 years. The age group 19 was dominant in our study. No two lip prints matched each other, establishing the uniqueness of lip prints in personal identification (Figure 1). The predominant type of lip prints seen in males was Type-1' (Figure 2). The commonest pattern found in our study was Type 1' (50%) and followed by Type 2 (21%). For all the tests, a P value of 0.05 or less was considered as statistically significant. When the age of the participant and the type of lip pattern was compared, the most common lip pattern of 19 and 20 years old males was found to be type I' p value was obtained as 0.8 which was statistically not significant (Figure 3).

Figure 1: Various lip patterns obtained in our study, Type I, clear-cut grooves running vertically across the lips; Type I', straight grooves which disappear half way instead of covering the entire lip; Type II, fork



grooves in their course; Type III, intersecting grooves; Type IV, reticulate grooves; Type V, undetermined.

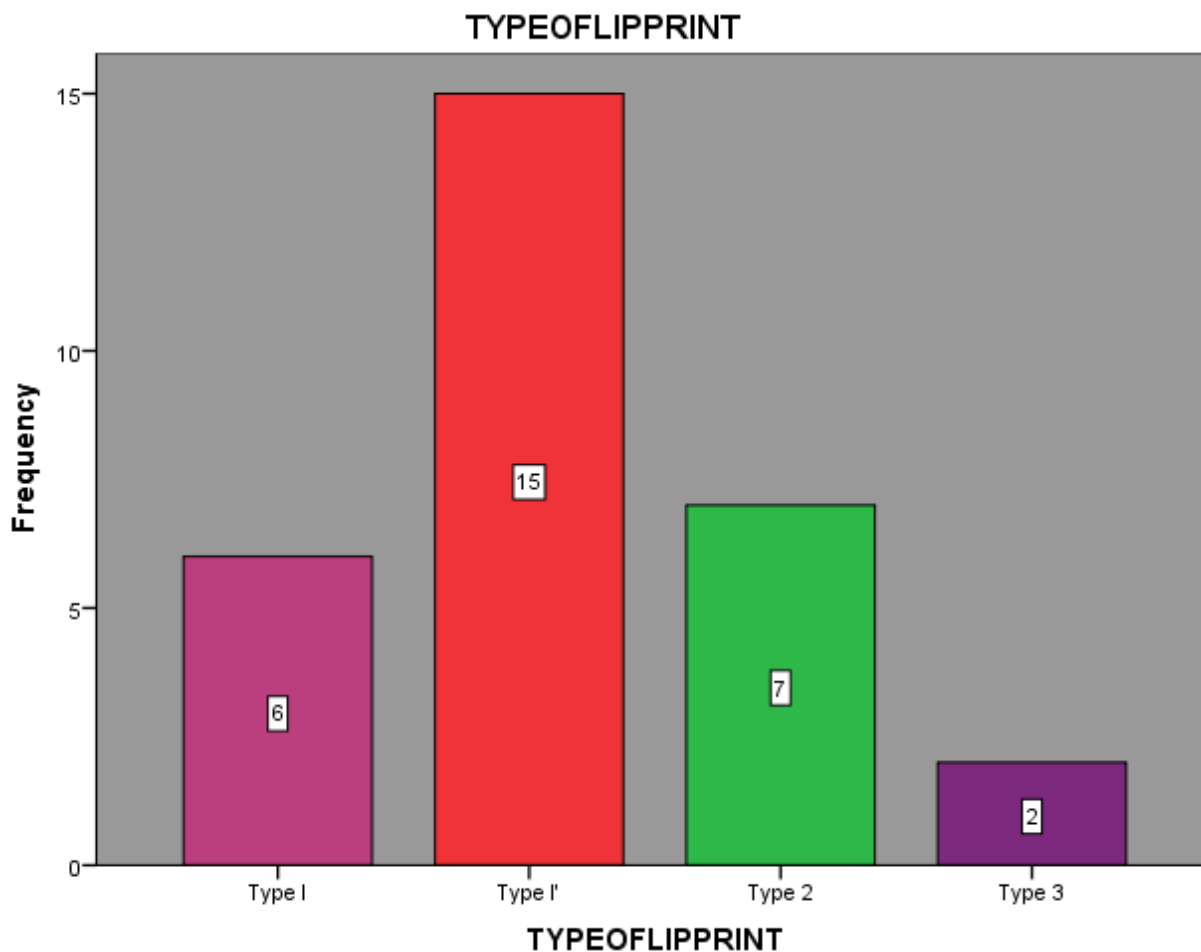


Figure 2: This bar graph represents the type of lip pattern among the males in the Chennai population. x-axis represents the Type of lip prints and y-axis represents the Frequency(%). The pink colour denotes the Type 1 pattern which is a clear cut vertical groove running across the lips. The Red colour denotes the Type 1' pattern which is a partial length groove of type 1. The Green colour denotes the Type 2 pattern, a branched groove. The purple colour denotes the type 3 pattern, an intersected groove. The most predominant Lip print was Type 1' Lip Pattern (50%) followed by Type 2 (36%), Type 1 (34%) and Type 3 (26%). Result obtained was statistically significant (Chi square test with p value = 0.008, statistically significant),

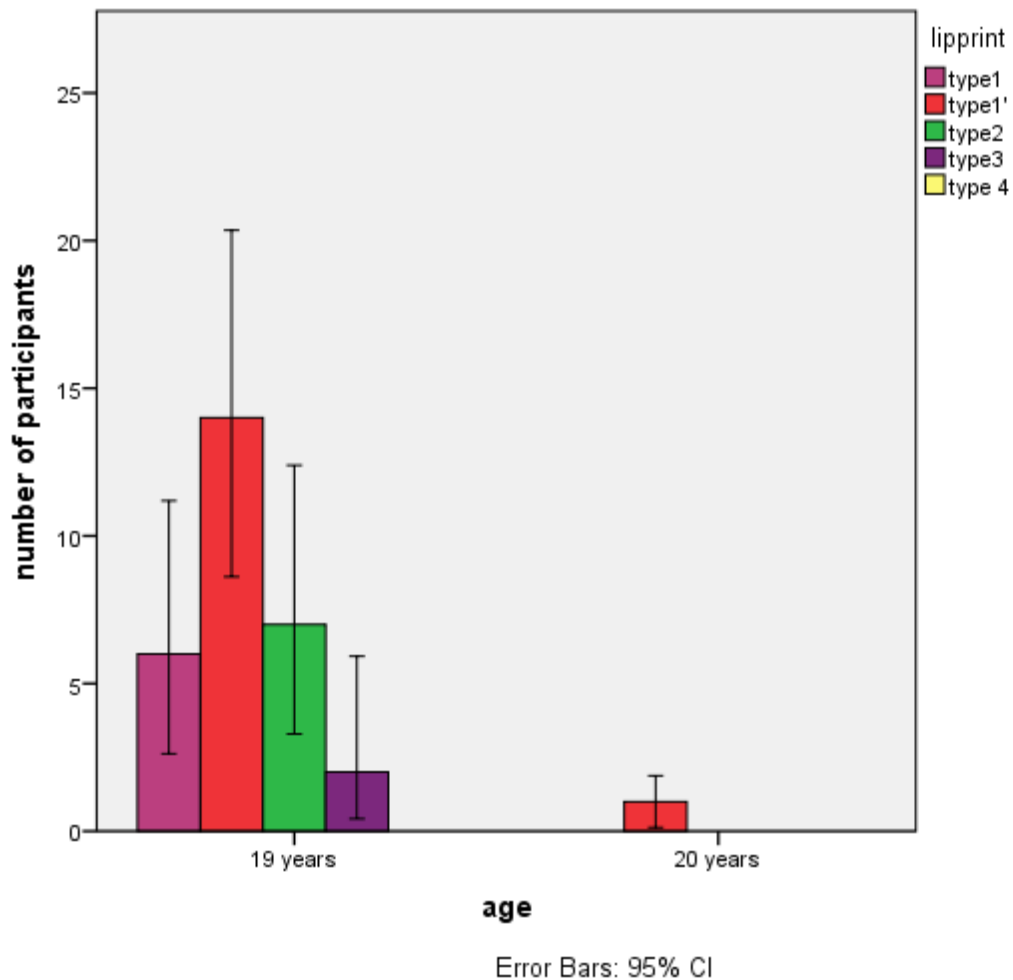


Figure 3: This bar graph represents the comparison of Types of lip patterns and Age of the participants. X-axis represents the Age and the y-axis represents the number of participants. The pink colour denotes the Type 1 pattern which is a clear cut vertical groove running across the lips. The Red colour denotes the Type 1' pattern which is a partial length groove of type 1. The Green colour denotes the Type 2 pattern, a branched groove. The purple colour denotes the type 3 pattern, an intersected groove. Most of the participants were 19 years old. Both 19 and 20 year participants showed Type 1' as the most predominant pattern. This result was statistically not significant (Chi square test showed p value= 0.8, hence statistically not significant)

DISCUSSION

Our study showed that Type 1' were a predominant pattern in males. This was in accordance with Sandhu et al, the author revealed that Type I lip patterns were predominant in both males and females (16). In contradictory to this result, Krishnan RP reported that Type IV pattern was predominant in

males.(17)Cheiloscropy examines the grooves,furrows,wrinkles,valleys of the vermilion zones of the lip(18).The lip prints are formed as early as the sixth week of the Intra uterine lip(19) and remains the same for throughout the life.(20)Latent lip prints can be developed from almost all the inanimate objects such as glass,tape,floor and straw.(20,21)Lips have minor salivary glands and the edges of the lips have sebaceous glands which secrete oil to provide moisture to the lips.(22) Even Though their ability to recover back to the original pattern after injury by trauma(23) or infections the similarities between the siblings and the families and about the gender variations(24)Type 1-A clear cut groove running vertically across the lips,(25) Type 1-Clear cut vertical grooves runs across the lips, Type 1'-Partial length groove of type 1, Type 2-A branched groove, Type 3-An intersected groove, Type 4-A reticular pattern, Type 5-Other patterns.(26) These are the 6 different types of lip prints reported by Tsuchihashi. In our study each individual had a unique lip print and hence lip prints can be used in forensic odontology along with odontometric analysis,bite mark analysis,dental age estimation,rugoscopy,cheiloscropy.

There are few limitations in using lip prints. Biometric identification or simply as the biometrics is the process of the referring the identification of a person based on the behavioural or the physical features which satisfy the uniqueness,permanence and the circumvention.Unlike the fingerprints,the lip prints are influenced by stretch,contraction and the muscle tone of the lip and the oro facial muscle. Lip prints cannot be used in subjects having any gross congenital deformities of lips (eg:cleft lip) and those with any inflammation,allergic to the lipstick and with any kind of disease (27) The Muscle tone decreases with the aging which was considered during the evaluation in the few studies. This should also be taken into consideration while analysing lip prints.

Lip prints analysis is becoming rapidly popular among the researchers and is now used as a valuable component in forensic odontology.Cheiloscropy is a method or a technique used for identifying the lip prints.Lip prints can be a valuable source of evidence in the criminal scenes when there are no fingerprints.(28–30).However, this pilot study tried to identify the predominant pattern of lip prints in males but the interpretations derived from this study are precluded by limited sample size. More extensive and detailed research is required to authenticate our findings. However, continuation of this work to include more subjects, and further validation of results may provide some clues of any correlation of these three parameters in identification in future. Our team has extensive knowledge and research experience that has translated into high quality publications(1–3,5,8–14,16,22,23,25,26,29–32)

CONCLUSION: Type I' lip pattern was common in males of south indian population. Our study has proved that chieloscopy has the potential to identify the sex and identity of the individual, as they unique to every individual, hence can be used for various forensic purposes.

Acknowledgment: The author would like to thank Saveetha Dental College for their support to conduct the study.

Conflict of interest: All the authors declare that there was no conflict of interest in the present study.

Source of funding:

The present study was supported by the following agencies.

- Saveetha Dental College
- Saveetha Institute of Medical and Technical Sciences (SIMATS)
- Saveetha University
- Jyothi gas agency

REFERENCES

1. Prabhu RV, Dinkar A, Prabhu V. Digital method for lip print analysis: A New approach. J Forensic Dent Sci. 2013 Jul;5(2):96–105.
2. Princeton B, Santhakumar P, Prathap L. Awareness on Preventive Measures taken by Health Care Professionals Attending COVID-19 Patients among Dental Students [Internet]. Vol. 14, European Journal of Dentistry. 2020. p. S105–9. Available from: <http://dx.doi.org/10.1055/s-0040-1721296>
3. Mathew MG, Samuel SR, Soni AJ, Roopa KB. Evaluation of adhesion of Streptococcus mutans, plaque accumulation on zirconia and stainless steel crowns, and surrounding gingival inflammation in primary molars: randomized controlled trial [Internet]. Vol. 24, Clinical Oral Investigations. 2020. p. 3275–80. Available from: <http://dx.doi.org/10.1007/s00784-020-03204-9>
4. Sindhu J, Maheswari TNU. Analysis of lip prints in 12 different compartments of lips in fifty female population: An observational study [Internet]. Vol. 1, International Journal of Forensic Odontology. 2016. p. 36. Available from: <http://dx.doi.org/10.4103/2542-5013.195050>
5. Sridharan G, Ramani P, Patankar S, Vijayaraghavan R. Evaluation of salivary metabolomics in oral

- leukoplakia and oral squamous cell carcinoma [Internet]. Vol. 48, Journal of Oral Pathology & Medicine. 2019. p. 299–306. Available from: <http://dx.doi.org/10.1111/jop.12835>
6. Verma Y, Einstein A, Gondhalekar R, Verma AK, George J, Chandra S, et al. A study of lip prints and its reliability as a forensic tool. *Natl J Maxillofac Surg*. 2015 Jan;6(1):25–30.
 7. Website [Internet]. Available from: R H, Hannah R, Ramani P, Ramanathan A, Jancy MR, Gheena S, et al. CYP2 C9 polymorphism among patients with oral squamous cell carcinoma and its role in altering the metabolism of benzo[a]pyrene [Internet]. Vol. 130, Oral Surgery, Oral Medicine, Oral Pathology and Oral Radiology. 2020. p. 306–12. Available from: <http://dx.doi.org/10.1016/j.oooo.2020.06.021>
 8. Antony JVM, Vini Mary Antony J, Ramani P, Ramasubramanian A, Sukumaran G. Particle size, penetration rate and effects of smoke and smokeless tobacco products – an invitro analysis [Internet]. Vol. 7, Heliyon. 2021. p. e06455. Available from: <http://dx.doi.org/10.1016/j.heliyon.2021.e06455>
 9. Sarode SC, Gondivkar S, Sarode GS, Gadbail A, Yuwanati M. Hybrid oral potentially malignant disorder: A neglected fact in oral submucous fibrosis [Internet]. *Oral Oncology*. 2021. p. 105390. Available from: <http://dx.doi.org/10.1016/j.oraloncology.2021.105390>
 10. Sundaram R, Nandhakumar E, Haseena Banu H. Hesperidin, a citrus flavonoid ameliorates hyperglycemia by regulating key enzymes of carbohydrate metabolism in streptozotocin-induced diabetic rats [Internet]. Vol. 29, Toxicology Mechanisms and Methods. 2019. p. 644–53. Available from: <http://dx.doi.org/10.1080/15376516.2019.1646370>
 11. Chandrasekar R, Chandrasekhar S, Shantha Sundari KK, Ravi P. Development and validation of a formula for objective assessment of cervical vertebral bone age [Internet]. Vol. 21, Progress in Orthodontics. 2020. Available from: <http://dx.doi.org/10.1186/s40510-020-00338-0>
 12. Subramanyam D, Gurunathan D, Gaayathri R, Vishnu Priya V. Comparative evaluation of salivary malondialdehyde levels as a marker of lipid peroxidation in early childhood caries [Internet]. Vol. 12, European Journal of Dentistry. 2018. p. 067–70. Available from: http://dx.doi.org/10.4103/ejd.ejd_266_17

13. Jeevanandan G, Thomas E. Volumetric analysis of hand, reciprocating and rotary instrumentation techniques in primary molars using spiral computed tomography: An in vitro comparative study [Internet]. Vol. 12, European Journal of Dentistry. 2018. p. 021–6. Available from: http://dx.doi.org/10.4103/ejd.ejd_247_17
14. Ponnulakshmi R, Shyamaladevi B, Vijayalakshmi P, Selvaraj J. In silicoandin vivoanalysis to identify the antidiabetic activity of beta sitosterol in adipose tissue of high fat diet and sucrose induced type-2 diabetic experimental rats [Internet]. Vol. 29, Toxicology Mechanisms and Methods. 2019. p. 276–90. Available from: <http://dx.doi.org/10.1080/15376516.2018.1545815>
15. Website [Internet]. Available from: Hannah R, Ramani P, WM Tilakaratne, Sukumaran G, Ramasubramanian A, Krishnan RP. Author response for “Critical appraisal of different triggering pathways for the pathobiology of pemphigus vulgaris—A review” [Internet]. Wiley; 2021. Available from: <https://publons.com/publon/47643844>
16. Sandhu SV, Bansal H, Monga P, Bhandari R. Study of lip print pattern in a Punjabi population. J Forensic Dent Sci. 2012 Jan;4(1):24–8.
17. Krishnan RP, Thangavelu R, Rathnavelu V, Narasimhan M. Gender determination: Role of lip prints, finger prints and mandibular canine index. Exp Ther Med. 2016 Jun;11(6):2329–32.
18. Tang X, Yu J, Li M, Zhan D, Shi C, Fang L, et al. Inhibitory effects of triterpenoid betulin on inflammatory mediators inducible nitric oxide synthase, cyclooxygenase-2, tumor necrosis factor-alpha, interleukin-6, and proliferating cell nuclear antigen in 1,2-dimethylhydrazine-induced rat colon carcinogenesis [Internet]. Vol. 16, Pharmacognosy Magazine. 2020. p. 841. Available from: http://dx.doi.org/10.4103/pm.pm_516_19
19. Website [Internet]. Available from: Shree KH, Hema Shree K, Ramani P, Herald Sherlin, Sukumaran G, Jeyaraj G, et al. Saliva as a Diagnostic Tool in Oral Squamous Cell Carcinoma – a Systematic Review with Meta Analysis [Internet]. Vol. 25, Pathology & Oncology Research. 2019. p. 447–53. Available from: <http://dx.doi.org/10.1007/s12253-019-00588-2>
20. Zafar A, Herald J. Sherlin, Jayaraj G, Ramani P, Don KR, Santhanam A. Diagnostic utility of touch imprint cytology for intraoperative assessment of surgical margins and sentinel lymph nodes in oral squamous cell carcinoma patients using four different cytological stains [Internet]. Vol. 48,

- Diagnostic Cytopathology. 2020. p. 101–10. Available from: <http://dx.doi.org/10.1002/dc.24329>
21. Website [Internet]. Available from: Karunagaran M, Murali P, Palaniappan V, Sivapathasundharam B. Expression and distribution pattern of podoplanin in oral submucous fibrosis with varying degrees of dysplasia – an immunohistochemical study [Internet]. Vol. 42, Journal of Histotechnology. 2019. p. 80–6. Available from: <http://dx.doi.org/10.1080/01478885.2019.1594543>
 22. Koneru A, Surekha R, Nellithady GS, Vanishree M, Ramesh D, Patil RS. Comparison of lip prints in two different populations of India: Reflections based on a preliminary examination. J Forensic Dent Sci. 2013 Jan;5(1):11–5.
 23. Sarode SC, Gondivkar S, Gadbail A, Sarode GS, Yuwanati M. Oral submucous fibrosis and heterogeneity in outcome measures: a critical viewpoint [Internet]. Vol. 17, Future Oncology. 2021. p. 2123–6. Available from: <http://dx.doi.org/10.2217/fon-2021-0287>
 24. Gupta S, Gupta K, Gupta O. A study of morphological patterns of lip prints in relation to gender of North Indian population. J Oral Biol Craniofac Res. 2011 Oct;1(1):12–6.
 25. Raj Preeth D, Saravanan S, Shairam M, Selvakumar N, Selestin Raja I, Dhanasekaran A, et al. Bioactive Zinc(II) complex incorporated PCL/gelatin electrospun nanofiber enhanced bone tissue regeneration. Eur J Pharm Sci. 2021 May 1;160:105768.
 26. Goodier J. Lippincott Williams & Wilkins Atlas of Anatomy 2009 78 Patrick W. Tank and Thomas R. Gest. Lippincott Williams & Wilkins Atlas of Anatomy. Philadelphia, PA: Lippincott Williams & Wilkins 2008. xv 432 pp., ISBN: 978 0 7817 8505 1 £38 \$72.95 [Internet]. Vol. 23, Reference Reviews. 2009. p. 38–9. Available from: <http://dx.doi.org/10.1108/09504120910935318>
 27. Drainer I. Congenital cleft deformities in rivers state of nigeria: Is there any association with environmental pollution? [Internet]. Vol. 25, Journal of Pediatric Surgery. 1990. p. 1002. Available from: [http://dx.doi.org/10.1016/0022-3468\(90\)90259-c](http://dx.doi.org/10.1016/0022-3468(90)90259-c)
 28. Vignesh R, Sharmin DD. A comparative evaluation between cheiloscopy patterns and canine relationship in primary dentition. J Forensic Dent Sci. 2018 May;10(2):84–7.
 29. Vignesh R, Rekha CV, Annamalai S, Norouzi P, Sharmin D. A Comparative Evaluation between

Cheiloscopy Patterns and Terminal Planes in Primary Dentition. *Contemp Clin Dent.* 2017 Oct;8(4):522–5.

30. Ravindra V, Rekha CV, Annamalai S, Sharmin DD, Norouzi-Baghkomeh P. A comparative evaluation between cheiloscopy patterns and the permanent molar relationships to predict the future malocclusions. *J Clin Exp Dent.* 2019 Jun;11(6):e553–7.
31. Dineshshankar J, Ganapathi N, Yoithappabhunath TR, Maheswaran T, Kumar MS, Aravindhana R. Lip prints: Role in forensic odontology. *J Pharm Bioallied Sci.* 2013 Jun;5(Suppl 1):S95–7.
32. Alsawalha M, Rao CV, Al-Subaie AM, Haque SKM, Veeraraghavan VP, Surapaneni KM. Novel mathematical modelling of Saudi Arabian natural diatomite clay [Internet]. Vol. 6, *Materials Research Express.* 2019. p. 105531. Available from: <http://dx.doi.org/10.1088/2053-1591/ab2f9b>