

A Prospective Observational Study to Evaluate the Incidence and Etiology of Facial Papules in Middle-Aged Female Patients Attending Dermatology OPD in a Tertiary Care Hospital

¹Dr. Surya K.P, ²Dr. Jayakar Thomas

¹Resident, Department of Dermatology, Chettinad Hospital and Research Institute, Kelambakkam, Chennai

²Professor & Head, Department of Dermatology, Chettinad Hospital and Research Institute, Kelambakkam, Chennai

Introduction

Face is an important area of concern in aspects of health and disease. Facial appearance of an individual provides primary identity to a person. Any lesions on the face provoke more anxiety and seeks early medical need.

Facial papules are a common finding in dermatology OPD's, wherein few are symptomatic while a vast majority of them are asymptomatic. Papules being an elevated solid lesion of skin less than 1 cm in diameter must be also evaluated based on shape, colour, umbilication, distribution, configuration and presence of tenderness. Facial papules may be the presenting feature of several conditions, including inflammatory, photosensitive, infective and granulomatous disorders as well as benign and malignant neoplasms. The various differentials for papular facial disorders at the given age group will include rosacea, discoid lupus erythematosus, granulosisrubranasi, granulomatous perioral and facial dermatitis, lichenoid dermatitis, acne agminata, sarcoidosis, Jessner's lymphocytic infiltrate, papular solar elastosis and rarely, polymorphous light eruption. The differentiation between these entities requires clinical, histopathological and laboratory evaluation.

Treatment options will include medical and surgical interventions. Medical management involves topical therapy and systemic drugs based on the aetiology. This includes keratolytics, retinoids, antifungals, antibiotics, vitamin D analogues and antimetotics. Surgical methods include radiofrequency ablation, cryotherapy, lasers, etc. Most of the cases are asymptomatic and the symptomatic cases seek medical attention mainly due to cosmetic concern.

The objective of the study is to evaluate the incidence of different causes of facial papules in female patients attending Dermatology OPD in Chettinad hospital and research institute and to estimate their frequencies, duration, clinical significance and their effect on quality of life.

Materials and Methods

Women above 30 years attending the skin OPD at Chettinad hospital and research institute are subjected to a detailed history taking and dermatological examination. If diagnosed to have facial papules; a photographic documentation is done¹. Further enquiry and examination is done to analyse the aetiological factors responsible for the occurrence of the facial papule. The recruited patients consenting for the study were thus subjected to full history taking, general dermatological examination and photographic documentation. Data entry was done on MS Excel and data analysis done in SPSS 22 version.

Exclusion criteria

- Female patients below the age of 30 and above 60 years.
- Male patients .

Inclusion Criteria

All female patients between the age of 30-60 years.

Study Design

Cross sectional observational study.

Study Area

The study was conducted at Dermatology Outpatient Department, Chettinad hospital and research institute

Study Population

Female patients aged 30-60 attending skin OPD, who are clinically diagnosed with facial papules.

Study Sample

The study consisted of 50 patients.

Type of Sampling

Consecutive sampling method was implemented.

Prior to the start of the study, each patient was given a written informed consent and the study was approved by the ethical and research committee

Results

The most common cause of facial papules in our study was compound nevus(32%),next common being dermatoses papulosanigra(26%).The other causes of facial papules were tineafaceii(10%),actinic keratoses(8%), milia(6%), seborrheic keratoses (4%) , acne (4%),molluscumcontagiosum(2%), syringoma(2%), trichoepithelioma(2%) and neurofibromatosis(2%).

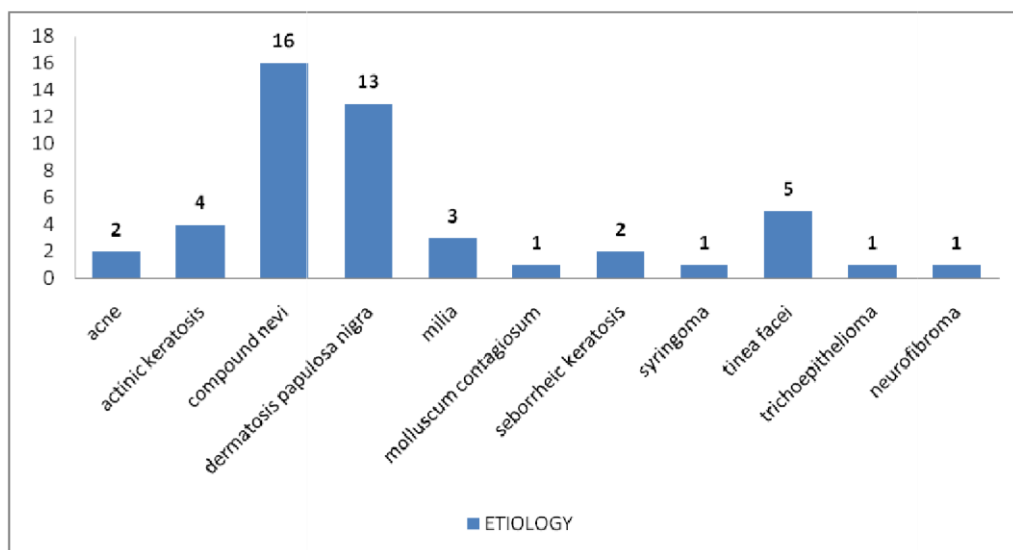


Figure 1: Etiology of Facial Papules

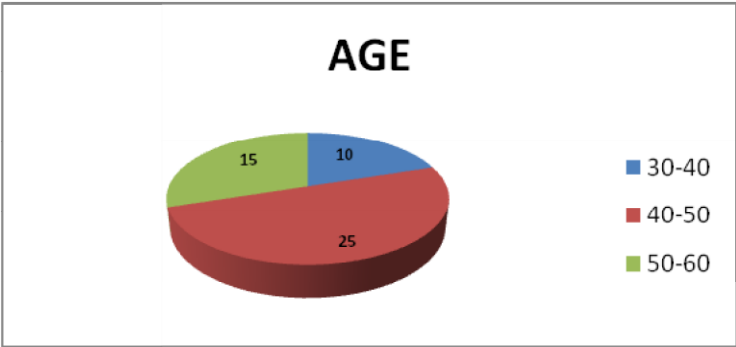


Figure 2: Prevalence of Facial Papules in Different Age Groups

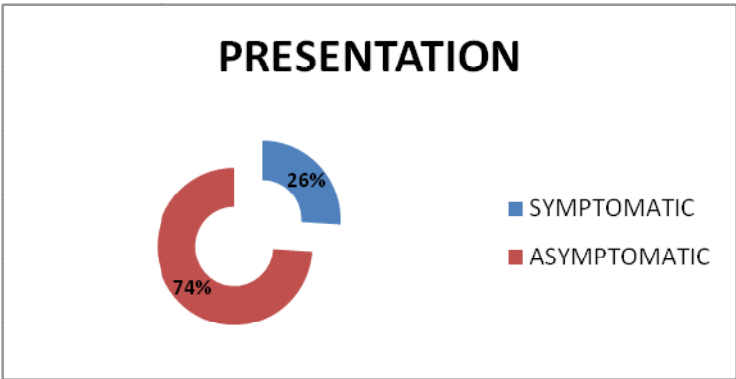
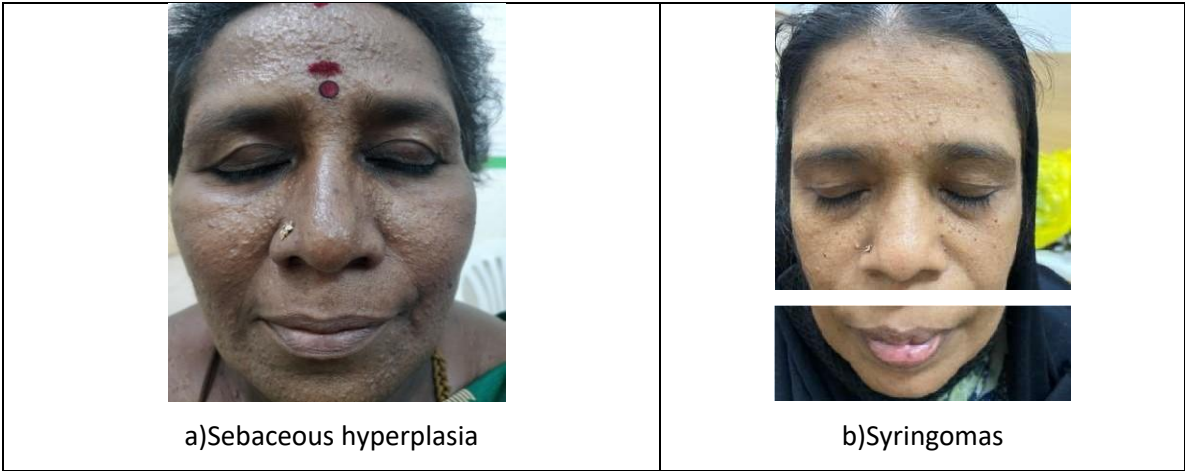
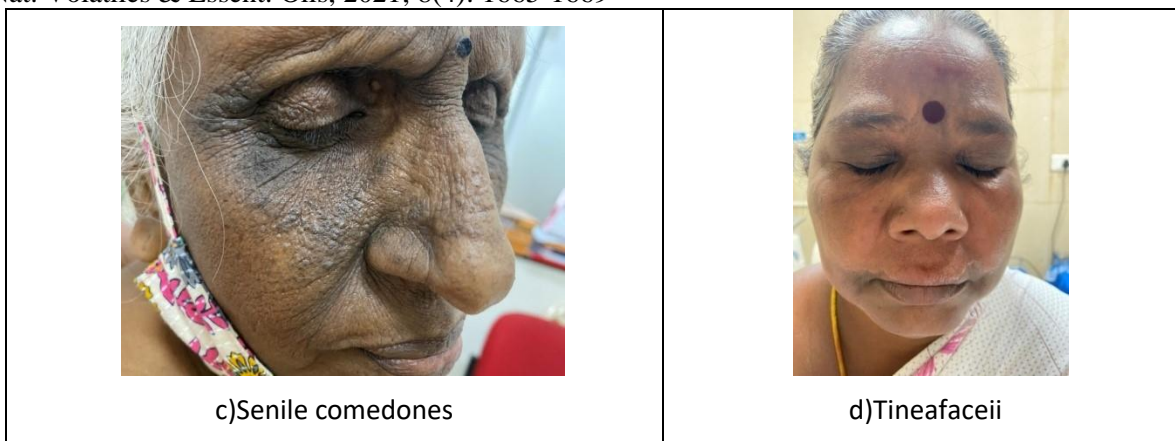

Figure 3: Patients with Facial Papules as Main Concern





Discussion

Our study result showed that compound nevi and dermatoses papulosanigra remains the common cause of facial papules in the women between 30 – 40years². In our study, the prevalence of Acne was 4%(n = 2); Actinic keratoses 8% (n = 4); compound naevi 32% (n=16); Dermatoses papulosanigra 26% (n = 13); milia 6% (n=3); molluscum contagiosum 2% (n=1); Seborrheic keratoses 4% (n=2); Syringoma 2% (n=1); Tinea faciei 10% (n = 5); Trichoepithelioma 2% (n=1); neurofibromatosis 2% (n = 1). Out of the 50 patients who were evaluated 26% (n = 13) came with facial papules as their presenting complaint / main concern for the visit. On most cases, around 74% (n=37) it was diagnosed as an incidental finding³. Among the patients seeking medical attention, age group 30-40 years had the maximum incidence and the most remains cosmetic disfigurement.

Similar study conducted by Thomas VP et al. claimed compound naevi to be the most common incidental finding in women above 60years along with syringoma which happens to correlate with our study finding⁴.

Conclusion

This study was conducted to assess the various dermatoses involving the face and their incidence rate in females, compared to other skin disorders, early identification and characterization of facial dermatoses poses a huge challenge on the dermatologists due to its varied presentations. Most of the studies conducted earlier illustrate the individual dermatoses of face. Our study provides insight into the common facial dermatoses that are encountered on a day-to-day practice^{5,6,7}.

Funding: No funding sources

Conflict of interest: None declared

Ethical approval: The study was approved by the Institutional Ethics Committee

References

1. Jackson R. Definitions in dermatology: a dissertation on some of the terms used to describe the living gross pathology of the human skin. ClinExpDermatol. 1978;3(3):241-7.
2. Schwartz RA. Multiple persistent keratoacanthomas. Oncol. 1979;36(6):281-5.
3. Angioma C. Common benign skin tumours. Am Fam Physician. 2003;67(4):729-38.
4. Callen JP, Bickers DR, Moy RL. Actinic keratoses. J Am AcadDermatol. 1997;36(4):650-3.
5. Alam M, Ratner D. Cutaneous squamous-cell carcinoma. New England J Med. 2001;344(13):975-83.
6. Dekio S, Jidoi J, Imaoka C. Lupus miliaris disseminatus faciei-report of a case in an elderly woman. ClinExpDermatol. 1991;16(4):295-6.

Nat. Volatiles & Essent. Oils, 2021; 8(4): 1665-1669

7. Robert C, Kupper TS. Inflammatory skin diseases, T cells, and immune surveillance. New England J Med. 1999; 341(24):1817-28.