

Role of Dual Energy Computed Tomography (DECT) in evaluation of renal stones

Mohammed Hanafy Fouad AbdelMageed¹, Omar Hussein Omar², Nivine AbdelMoneim Chalabi³ and Mona Gamalludin Alsayed Alkaphoury⁴.

¹ MSc, Radiology departement, Faculty of medicine - Ainshams univeristy, 11591, Cairo, Egypt

² Professor of radiodiagnosis, radiology departement, Faculty of medicine - Ainshams univeristy, 11591, Cairo, Egypt³ Assistant professor of radiodiagnosis, radiology departement, Faculty of medicine - Ainshams univeristy, 11591, Cairo, Egypt.

⁴ Lecturer of radiodiagnosis, radiology departement, Faculty of medicine - Ainshams univeristy, 11591, Cairo, Egypt..

Abstract

Renal stones remain a typical clinical problem that affects about 10–14% of the population. There are different chemical compounds forming renal stones. Characterization of stone's chemical composition plays an important role in choosing the appropriate management. There are several techniques for stone analysis. Herein, we want to evaluate if stone's composition can be analyzed using dual energy CT.

Keywords: DECT, Dual Energy & Renal Stones.

Introduction :

Renal calculi with variable chemical compositions continue to represent a typical medical challenge that affects about 10–14% of the population (Curhan, 2007).

Unenhanced computed tomography is employed to judge urinary calculi in terms of presence, size and location of stones. DECT offers additional analysis of renal calculi chemical composition (Boll et al., 2009; Grosjean et al., 2008) .

In terms of physical aspect, three concepts of DECT are available; the first concept is through applying two X-ray tubes that work simultaneously (known as **dual source** imaging). The second concept employs a **dual-layer multi-detector**, One layer absorbs most of the low-energy spectrum and the other layer absorbs higher energy photons. The third concept relies on having a single X-ray source that does **fast switching** between two kilovoltages (80 and 140 kVp) at intervals of 0.5 ms during single gantry rotation to come up with high & low energy X-ray spectra (Seidensticker & Hofmann, 2008).

Studies report that DECT has a high sensitivity & specificity in analysis of renal stones chemical composition (Manglaviti et al., 2011).

Dual energy CT is reported to own the ability to differentiate uric acid from non-uric acid renal calculi (Primak et al., 2007).

Analyzing renal stone's composition helps the clinician to precisely choose the suitable treatment plan; such as those composed of uric acid, may be treated medically and shall not require surgery (Williams et al., 2003).

On the other hand, DECT limitations related to its relatively high irradiation is reported. However, variable techniques are employed to diminish radiation exposure dose (Ascenti et al., 2010).

It is expected for DECT to be the main imaging modality for evaluation of patients with suspected urinary calculi (Akand et al., 2016; Li, Zhao, Liu & Yu, 2013).

This study aims to evaluate the role of DECT in renal stones characterization.

Patients and Methods:

This prospective study involved 30 patients with urinary tract stones, at the radiology department of the International Medical Center "IMC" (JCI Accredited) in Egypt. Stone's composition by DECT as well as stone analysis after stone extraction were performed. Statistical analysis for the results was done and agreement between dual-energy CT & laboratory stone analysis has been estimated using Cohen's Kappa coefficient.

Results:

20 males and 10 females with known renal stones were examined with a total number of 37 renal stones; no age or sex predilection, patients aged from (16) to (79) years. From all examined stones, DECT analyzed the chemical composition of stones as 8 uric acid, 24 Ca oxalate and 5 cystine stones. DECT could identify all uric acid stones. DECT analyzed 2 stones as Ca oxalate and they were found to be Ca phosphate by crystallography. DECT also was not able to identify mixed compositions in 2 stones which were diagnosed as Ca oxalate and cystine stones. Statistical analysis has shown a reliable agreement between DECT and crystallography with a (p-value) of >0.001 (highly significant).

Conclusion:

Identification of renal stones chemical composition affects the selection of treatment options. Renal stones must be obtained in vitro in order to undergo laboratory chemical analysis. While renal stones are in vivo, DECT was found as an effective and reliable method in predictive analysis of their chemical composition.

Materials and methods :

➤ **Patients:**

This prospective cohort study was performed at the Radiology department of the International Medical Centre "IMC" (JCI accredited), Cairo, Egypt, throughout the period from August 2018 to March 2020. The study involved 30 patients (10 females and 20 males) with known renal stones. Patients aged from (16) to (79) years with a mean age (47.5) years.

Informed written consents have been obtained from all participants in the study after full explanation of the benefits and risks of the procedure. Confidentiality & privacy of all patient data were guaranteed. All data were monitored and used for scientific purpose only.

Inclusion criteria :

included: patients previously diagnosed with renal stones larger than 3 mm. No age or sex predilection.

Exclusion criteria :

included: contraindications to radiation e.g., pregnancy.

➤ **Methodology:**

In the study, all the patients have been subjected to:

History.

Full history taking including:

- Personal history included age, sex and special habits as smoking& alcoholism.
- History of the present illness.
- Past history with special concern on known urolithiasis.

1. Clinical examination.

2. Radiological examination.

Computed Tomography is done:

○ **CT machine:** all patients were scanned with multidetector CT scanner, Aquilion ONE™ 640/ GENESIS Edition, Toshiba, Japan.

○ **Patient preparation:**

- No fasting is required before the exam.
- Patients are advised to drink a good amount of water 1-2 hours before the scan and to maintain a full bladder.

○ **Image acquisition:**

- Position: supine position with the arms were put above the head after its fixation then patient was asked to hold breath at various times during the examination.

▪ Technical scan parameters:

Field of view: patient's body size; scanogram, covering the body area from the xiphisternum cranially to the symphysis pubis caudally; tube voltage, 100-120 kVp; tube current, 150 mA with automatic exposure control; slice thickness, 1 mm; slice interval, 0; gantry rotation time, 0.5 sec. Axial cuts are scanned, coronal and sagittal planes are then reconstructed. For each patient, we evaluated the number, location and maximum dimensions of renal calculi. CT density has been also measured through a region of interest "ROI" occupying less than 50% of stone's surface area.

- DECT examination was then performed by using a single-source dual energy that does fast switching between two kilovoltages. Technical scan parameters for DECT scan: tube voltage, 80 kVp

and 135 kVp; reference tube current, 115 mA and 350 mA with automatic exposure control; field of view, patient's body size; slice thickness, 0.5 mm; gantry rotation time, 0.5 sec.

○ **Post processing technique:**

Images acquired with the dual energy modality were processed using dedicated software of the CT machine for the evaluation of stone's chemical composition. After selection of both low-energy and high-energy image volumes, stones were numbered in both low-energy and high-energy images. Then, end result was presented after the software calculated attenuation ratios of stones and displayed it as a point on the graph, colorized in red or blue colors according to color map stone's composition.

○ **Result display:**

- Stone's number, site, measurements and density in single energy (in HU).
- Measured attenuation values in single energy CT and DE (in HU).
- Calculated attenuation ratios (low energy HU/ high energy HU).
- Colored stone on the color map according to stone's chemical composition.

3. Laboratory stone analysis:

All data were reviewed in comparison with the results of laboratory stone analysis (crystallography) after extraction or passage of stones.

4. Data collection and statistical analysis:

Categorical and continuous variables were expressed and results were set in tables and figures using Microsoft Excel™ 2016. A Similitude between DECT and laboratory stone analysis (crystallography) has been calculated using Cohen's Kappa coefficient (k).

Results :

- **Demographic data:** This study involved 30 patients, 10 females and 20 males. The ages ranged from 16 to 79 years. Sex and age distribution is figured below **(Table 1)**.

Table (1): Sex and Age of studied patients.

Age in years	Sex				Total	
	Male		Female			
	No.	%	No.	%	No.	%
<30	1	3.3	1	3.3	2	6.6
30-<40	6	20	1	3.3	7	23.3
40-<50	5	16.6	2	6.6	7	23.3

50-<60	4	13.3	3	10	7	23.3
60<70	3	10	2	6.6	5	16.6
>70	1	3.3	1	3.3	2	6.6
Total	20	66.6	10	33.3	30	100

▪ **Presenting symptoms:**

▪ Loin pain has been noted in 17 patients, hematuria in 5 patients, hematuria associated with loin pain in 3 patients. Another 3 patients complained of loin pain associated with nausea and vomiting. Loin pain with fever has been appreciated in just 1 patient. Also, only one patient has been asymptomatic. The percentage of each clinical presentation is represented in **(Figure 2)**.

▪ **Single energy CT examination:**

▪ Non-contrast single energy computed tomography has been performed for all patients. 25 patients had a single stone and 5 patients had multiple stones; the whole number of stones in the examined 30 patients was 37 stones. The dimensions of stones varied from 5 to 36 mm with a mean of 15 mm. Single energy CT density extended from 405 HU to 1926 HU with a mean of 1124 HU. Eighteen stones were located at the lower calyx, 4 stones at the upper calyx, 3 stones at the middle calyx, 7 stones were detected at the renal pelvis and 5 stones were stag-horn stones. These findings are figured and tabled in **(Figure 1)** and **(Table 2)**.

Figure (1): Shows Sizes of stones in examined patients.

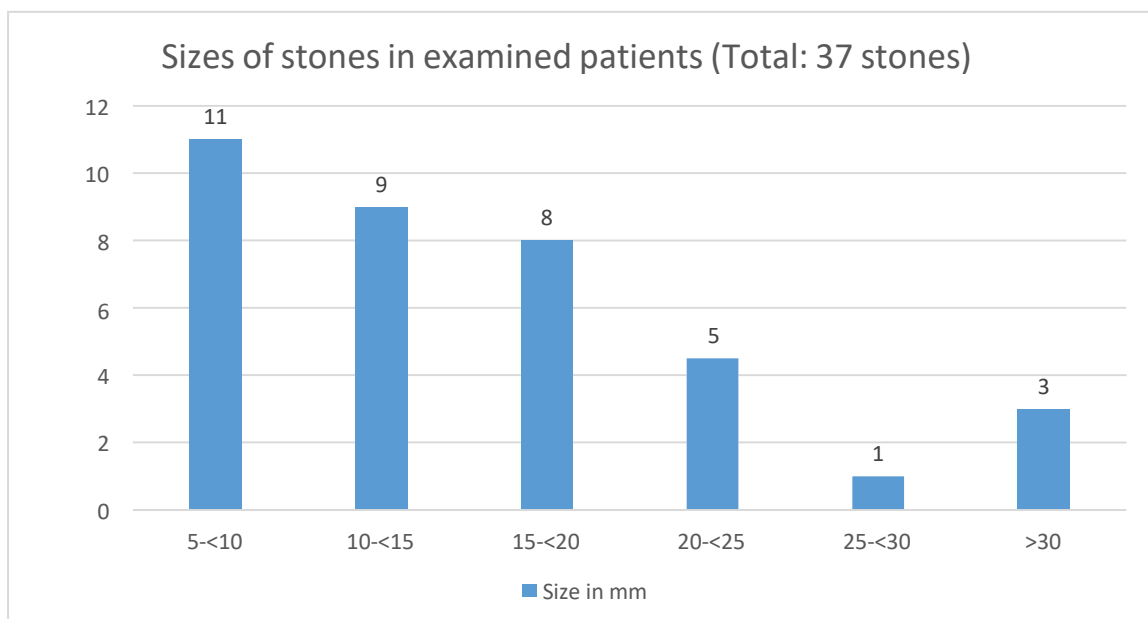


Figure (2): Graph showing clinical presentations of the studied cases.

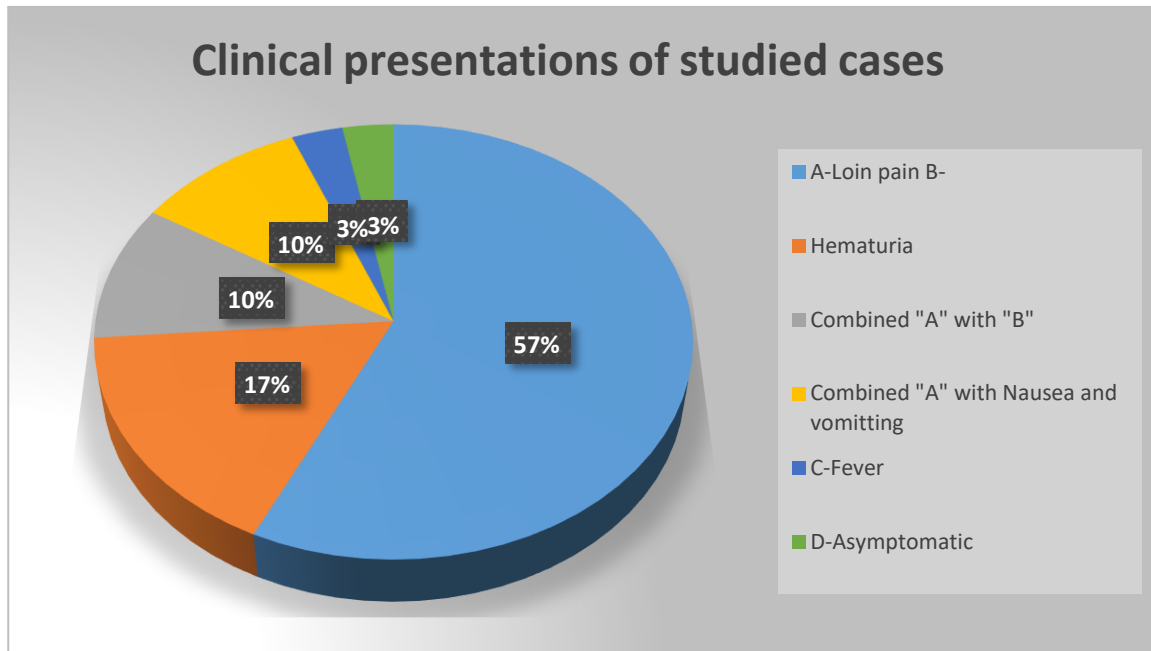


Table (2): Shows sites of stones in examined patients.

Site of stone	Right	Left	Total	Percentage
Upper calyx	1	3	4	10.8
Middle calyx	2	1	3	8.2
Lower calyx	7	11	18	48.6
Pelvis	1	6	7	18.9
Staghorn	2	3	5	13.5
Total	13	24	37	100

- **Dual energy CT examination:**
- Dual energy CT examinations have been performed by using a single-source dual energy that is fast switching between two kilovoltages (80 kVp and 135 kVp). DECT analyzed chemical composition of stones as 8 uric acid, 24 Ca oxalate and 5 cystine stones. DECT correctly recognized uric acid stones. Because of having only software criteria for uric acid, Ca oxide & Cystine stones with no available criteria to detect other chemical compositions including Ca phosphate and struvite stones; in the current study, DECT analyzed 2 stones as Ca oxalate and they were found to be Ca phosphate by crystallography. Also, DECT didn't identify mixed compositions in 2 stones which were identified as Ca oxalate and cystine stones. Aforementioned findings are tabled in **(Tables 3, 4)**.

Table (3): Different stone types predicted by DECT.

	Number of stones	Percentage
Ca Oxalate	24	64.8
Uric acid	8	21.6
Cystine	5	13.6
Total	37	100

Table (4): Agreement between DECT and crystallography.

DECT	Crystallography					X2 (P-value)
	Calcium Oxalate	Calcium Phosphate	Cystine	Mixed	Uric Acid	
Calcium Oxalate	21	2	0	1	0	69.529 (>0.001**)
	(100%)	(100%)		(50%)	0	
Cystine	0	0	4	1	0	
			(100%)	(50%)		
Uric Acid	0	0	0	0	8	
					(100%)	
Kappa agreement (P-value)	0.899 (>0.001**)					

** : Highly significant

Kappa statistic needs a two-way table in which the variables are of the same type to be calculated; so calcium phosphate and calcium oxide of crystallography were combined together and further compared with calcium oxide of DECT.

Data collection: DECT recognized the chemical composition of uric acid stones ranging (405-530) HU for low-energy and (457-573) HU for high-energy with attenuation ratio of (0.8-1). Cystine stones ranging (762- 1200) HU for low-energy and (696-1002) HU for high-energy with attenuation ratio (1-1.2). Calcium oxalate stones ranging (1249-2151) HU for low-energy and (710-1561) HU for high-energy with attenuation ratio of (1.27-2.2). These values are detailed in **(Table 5)**.

Table (5): Detailed data of DECT stone characterization.

No.	Single energyHU	Low-energyHU	High-energyHU	Attenuation ratio	DECT stonetype
1.	505	475	535	0.88	Uric Acid
2.	413	410	457	0.89	Uric Acid
3.	405	467	520	0.89	Uric Acid

4.	439	425	468	0.90	Uric Acid
5.	461	439	475	0.92	Uric Acid
6.	536	530	573	0.92	Uric Acid
7.	489	458	492	0.93	Uric Acid
8.	408	405	435	0.93	Uric Acid
9.	704	762	696	1.09	Cystine
10	962	964	864	1.11	Cystine
11	853	927	780	1.18	Cystine
12	1057	1200	1002	1.19	Cystine
13	917	1035	849	1.21	Cystine
14	1100	1249	978	1.27	Calcium Oxide
15	1286	1390	1081	1.28	Calcium Oxide
16	1183	1314	1019	1.28	Calcium Oxide
17	1456	1678	1298	1.29	Calcium Oxide
18	1442	1777	1366	1.30	Calcium Oxide
19	1577	1866	1432	1.30	Calcium Oxide
20	1495	1682	1272	1.32	Calcium Oxide
21	1799	1994	1500	1.32	Calcium Oxide
22	1202	1560	1173	1.32	Calcium Oxide
23	1169	1370	1027	1.33	Calcium Oxide
24	1554	1643	1228	1.33	Calcium Oxide
25	1178	1483	1104	1.34	Calcium Oxide
26	1407	1695	1257	1.34	Calcium Oxide
27	1620	1789	1312	1.36	Calcium Oxide
28	1585	1835	1344	1.36	Calcium Oxide
29	1634	1872	1361	1.37	Calcium Oxide
30	1926	2151	1561	1.37	Calcium Oxide
31	1306	1734	1256	1.38	Calcium Oxide
32	1384	1777	1282	1.38	Calcium Oxide
33	1249	1660	1180	1.40	Calcium Oxide
34	1116	1603	1069	1.49	Calcium Oxide
35	1466	1927	1231	1.56	Calcium Oxide
36	1241	1591	913	1.74	Calcium Oxide
37	1070	1571	710	2.21	Calcium Oxide

▪ **Management data:**

▪ Patients underwent various treatment options according to stone's site, size and chemical composition. In our study, 6 stones responded to medical treatment, 15 stones responded to Extracorporeal Shock Wave Lithotomy (ESWL), 13 stones underwent Percutaneous Nephrolithotomy (PCNL) and 3 stones needed open surgery (**Table 6**).

Table (6): Number of stones underwent various management options.

Management options	Number of stones	Percentage
Medical treatment	6	16.2
ESWL	15	40.6
PCNL	13	35.1
Open surgery	3	8.1
Total	37	100

▪ **Management data interpretation:**

▪ Only 1 patient had a stone of ≤ 5 mm in size, which was identified as uric acid stone, so it responded to medical treatment. Twenty-one stones ($5 - \leq 15$ mm); 4 of them were uric acid stones, 3 has been treated medically and one stone needed PCNL due to associated larger stone in duplex calyceal system, 2 cystine stones were managed by medical treatment and 15 stones were Ca oxalate; of which 13 were managed by ESWL and 2 required PCNL after unsuccessful ESWL. Six stones were ($16 - \leq 20$ mm); 2 of them were uric acid that didn't respond to medical treatment and required PCNL, 4 were Ca oxalate; of them 3 were managed using ESWL and one required PCNL. Nine stones ≥ 20 mm; 6 of them have undergone PCNL and 3 were removed surgically regardless their chemical natures (**Table 7**).

Table (7): Different management regarding size and chemical composition of stones.

Stone size	Number of stones	Composition	Management
≤ 5 mm	1	Uric acid	Medical
5 - ≤ 15 mm	3	Uric acid	Medical
	1	Uric acid	PCNL
	2	Cystine	Medical
	13	Ca Oxalate	ESWL
	2	Ca Oxalate	PCNL
16- ≤ 20 mm	2	Uric acid	PCNL
	3	Ca Oxalate	ESWL
	1	Ca Oxalate	PCNL
≥ 20 mm	6	Various	PCNL
	3	Various	Open Surgery
Total	37		

Discussion :

Characterization of urinary calculi has a serious impact on their management. CT has been the investigation of choice for diagnosis of urinary stones, but couldn't analyze stone's chemical composition. On the other hand, DECT technology helps with identification of the chemical composition of renal stones and consequently selection of the appropriate treatment plan (Ferrandino et al., 2010; Sanavi et al., 2013).

In our study; male to female ratio was 2:1, this ratio goes along with the study published by (Knoll et al., 2011), they reported that renal stones were more in males with male to female ratio of (2.4:1). Yet, this

disagrees with another study from Egypt by (Dawoud, Dewan, Zaki and Sabae, 2017); in aforementioned study, renal stones showed a greater frequency in females (55%) than males (45%).

Our study involved 30 patients, patients aged from 16 to 79 with a mean of 50 years and the peak age group was 40-50 years (5 cases; 16.6 %). This accepts what (PEARLE et al., 2005) reported; they evaluated two groups going through SWL and URS with the mean ages were (52.5 ± 12.3) and (49.3 ± 14.2) in both groups, respectively. Yet, These results contrasts to age groups decided by other studies such as (Dawoud, Dewan, Zaki and Sabae, 2017); they concluded that the age group 30-40 were the most affected with the peak of 33 years.

A defect at the current study is the small population, this may be referred to the difficulties we faced in the laboratory stone analysis because of its high cost and unavailability in our institute.

In the current study, 19 patients (64%) complained of loin pain, 7 patients (23%) had hematuria, 3 patients (10%) had nausea and vomiting & one patient (3%) expressed combined loin pain and fever. These clinical manifestations match with many studies; one of which is (Dawoud, Dewan, Zaki and Sabae, 2017), they reported that loin pain was the most common clinical manifestation.

In the present study, twenty-five patients had a single stone and 5 patients had multiple stones, the total number of stones in the 30 examined patients was 37 stones. The sizes of calculi measured from 5 to 36 mm with a mean of 15 mm. Single energy CT density varied from 405 HU to 1926 HU with a mean of 1124 HU.. These findings agreed with (Chaytor, Rajbabu, Jones and McKnight, 2016); they found kidney stones are much more common (84.7 %) than ureteric stones, a single stone was found in 79% of cases. They found that sizes of stones range from 3-48 mm with a mean of 8.8 mm, this shall be explained by the difference in number of examined patients; they investigated 106 patients, in comparison to only 30 patients in the current study.

In the present study, DECT analyzed chemical composition of stones as 8 uric acid stones, 24 Ca oxalate stones, and 5 cystine stones. DECT accurately diagnosed all uric acid stones. These findings agreed with studies by (Chaytor et al., 2016; Dawoud, Dewan, Zaki and Sabae, 2017; Stolzmann et al., 2008), they reported that DECT was able to differentiate uric acid stones from non-uric acid stones using attenuation ratio analysis.

In the present study; DECT failed to identify 2 Ca phosphate stones compared to crystallography, it also failed to identify mixed compositions in 2 stones which were diagnosed as Ca oxalate and cystine stones by crystallography. These findings accept the study done by (Manglaviti et al., 2011); they reported that DECT couldn't identify chemical composition of 4 stones that were analyzed to be mixed uric acid and Ca oxalate by crystallography while DECT diagnosed them as cystine and Ca oxalate.

In the current study; only one patient had a stone of <5 mm in size, which was uric acid stone, so it responded to medical treatment. Twenty-one stones ($6 - \leq 15$ mm); 4 of them were uric acid stones, 3 responded to medical treatment and one stone needed PCNL due to another larger stone in duplex calyceal system, 2 cystine stones responded to medical treatment and 15 stones were Ca oxalate of which 13 underwent ESWL and 2 needed PCNL after failure of ESWL. 6 stones were ($16 - \leq 20$ mm); 2 of them were uric acid failed medical treatment and needed PCNL, 4 were Ca oxalate, of them 3 responded to ESWL and one needed PCNL. Nine stones >20 mm; 6 of them underwent PCNL and 3 needed open surgery regardless the chemical composition. These findings regarding the management of renal stones according to site, size and medical compositions agreed with multiple studies such as (Habashy et al., 2016); they reported that differentiating uric acid from calcium stones has resulted in changing the management plans in the majority

of their uric acid stone cases and avoiding surgery in 12 patients (80%). Overall, 48 patients needed a DECT scan for diagnosis and successful dissolution treatment of a uric acid stone. However, the impact of chemical composition pre-analysis is still controversial, in a study published by (Thomas et al., 2009); calculus composition did not have an impact on the patient's clinical pathway, since in their institution, whenever possible, the urology department extracted all stones by PNL or ureterorenoscopy.

Conclusion :

- DECT was found as a reliable method in evaluation of renal stones prior to their management.
- In addition to providing basic information such as number of stones, their sites, measurements, surfaces as well as CT densities, DECT provides satisfactory information regarding stone's chemical composition.
- Identification of renal stone's chemical composition will help with choosing the appropriate treatment plan, diminishing the usage of unnecessary invasive or semi-invasive options and improving the outcome of medical treatment.
- DECT is expected to replace the classic single energy CT as the main imaging modality for evaluation of renal stones.

Recommendations :

We recommend that; further studies should be done to calculate attenuation ratio of other stones such as Calcium Phosphate, so DECT can be used to identify such stones in the future.

Acknowledgments :

There are no acknowledgments.

Competing interests

The authors declare that they have no competing interests.

Abbreviations :

DECT, Dual Energy Computed Tomography; kVp, Peak kilovoltage; Ca, Calcium; ESRD, End Stage Renal Disease; HU, Hounsfield Unit; ROI , region of interest; kV, kilovoltage; ESWL, Extracorporeal Shock Wave Lithotomy; PCNL, Percutaneous Nephrolithotomy; URS, Ureteroscopy.

References :

- Akand, M., Koplay, M., Islamoglu, N., Gul, M., Kilic, O., & Erdogdu, M. (2016). Role of dual-source dual-energy computed tomography versus X-ray crystallography in prediction of the stone composition: a retrospective non-randomized pilot study. *International Urology And Nephrology*, 48(9), 1413-1420.
- Ascenti, G., Siragusa, C., Racchiusa, S., Ielo, I., Privitera, G., Midili, F., & Mazziotti, S. (2010). Stone-targeted dual-energy CT: A new diagnostic approach to urinary calculosis. *American Journal Of Roentgenology*, 195(4), 953-958.
- Boll, D., Patil, N., Paulson, E., Merkle, E., Simmons, W., Pierre, S., & Preminger, G. (2009). Renal stone assessment with dual-Energy Multidetector CT and advanced postprocessing

- techniques: Improved characterization of renal stone composition—Pilot study. *Radiology*, 250(3), 813-820.
- Chaytor, R., Rajbabu, K., Jones, P. and McKnight, L., 2016. Determining the composition of urinary tract calculi using stone-targeted dual-energy CT: evaluation of a low-dose scanning protocol in a clinical environment. *The British Journal of Radiology*, 89(1067), p.20160408.
- Curhan, G. (2007). Epidemiology of stone disease. *Urologic Clinics Of North America*, 34(3), 287-293.
- Dawoud, M., Dewan, K., Zaki, S. and Sabae, M., 2017. Role of dual energy computed tomography in management of different renal stones. *The Egyptian Journal of Radiology and Nuclear Medicine*, 48(3), pp.717-727.
- Ferrandino, M., Pierre, S., Simmons, W., Paulson, E., Albala, D., & Preminger, G. (2010). First Prize (Tie): Dual-Energy computed tomography with advanced postimage acquisition data processing: Improved determination of urinary stone composition. *Journal Of Endourology*, 24(3), 347-354.
- Grosjean, R., Sauer, B., Guerra, R., Daudon, M., Blum, A., Felblinger, J., & Hubert, J. (2008). Characterization of human renal stones with MDCT: advantage of dual energy and limitations due to respiratory motion. *American Journal Of Roentgenology*, 190(3), 720-728. doi: 10.2214/ajr.07.2466
- Habashy, D., Xia, R., Ridley, W., Chan, L. and Ridley, L., 2016. Impact of dual energy characterization of urinary calculus on management. *Journal of Medical Imaging and Radiation Oncology*, 60(5), pp.624-631.
- Knoll, T., Schubert, A., Fahlenkamp, D., Leusmann, D., Wendt-Nordahl, G. and Schubert, G., 2011. Urolithiasis through the Ages: Data on more than 200,000 urinary stone analyses. *Journal of Urology*, 185(4), pp.1304-1311.
- Li, X., Zhao, R., Liu, B., & Yu, Y. (2013). Determination of urinary stone composition using dual-energy spectral CT: Initial in vitro analysis. *Clinical Radiology*, 68(7), e370-e377.
- Manglaviti, G., Tresoldi, S., Guerrer, C., Di Leo, G., Montanari, E., Sardanelli, F., & Cornalba, G. (2011). In vivo Evaluation of the chemical composition of urinary stones using dual-energy CT. *American Journal Of Roentgenology*, 197(1), W76-W83.
- Pearle, M., Lingeman, J., Leveillee, R., Kuo, R., Preminger, G., Nadler, R., Macaluso, J., Monga, M., Kumar, U., Dushinski, J., Albala, D., Wolf, J., Assimos, D., Fabrizio, M., Munch, L., Nakada, S., Auge, B., Honey, J., Ogan, K., Pattaras, J., McDougall, E., Averch, T., Turk, T., Pietrow, P. and Watkins, S., 2005. Prospective, randomized trial comparing shock wave lithotripsy and ureteroscopy for lower pole caliceal calculi 1 cm or less. *Journal of Urology*, 173(6), pp.2005-2009.
- Primak, A., Fletcher, J., Vrtiska, T., Dzyubak, O., Lieske, J., & Jackson, M. et al. (2007). Noninvasive differentiation of uric acid versus non-uric acid kidney stones using dual-energy CT. *Academic Radiology*, 14(12), 1441-1447.
- Sanavi, C., Werquin, C., Fekir, A., Pinson, C., Bugel, H. and Dacher, J., 2013. Urinary stones: The contribution of dual energy CT and material decomposition. *Diagnostic and Interventional*

Imaging, 94(11), pp.1165-1168.

Seidensticker, P., & Hofmann, L. (2008). *Dual source CT imaging*. Heidelberg, Berlin: Springer.

Stolzmann, P., Scheffel, H., Rentsch, K., Schertler, T., Frauenfelder, T., Leschka, S., Sulser, T., Marincek, B. and Alkadhi, H., 2008. Dual-energy computed tomography for the differentiation of uric acid stones: ex vivo performance evaluation. *Urological Research*, 36(3-4), pp.133-138.

Thomas, C., Patschan, O., Ketelsen, D., Tsiflikas, I., Reimann, A., Brodoefel, H., Buchgeister, M., Nagele, U., Stenzl, A., Claussen, C., Kopp, A., Heuschmid, M. and Schlemmer, H., 2009. Dual-energy CT for the characterization of urinary calculi: In vitro and in vivo evaluation of a low-dose scanning protocol. *European Radiology*, 19(6), pp.1553-1559.

Williams, J., Saw, K., Paterson, R., Hatt, E., McAteer, J., & Lingeman, J. (2003). Variability of renal stone fragility in shock wave lithotripsy. *Urology*, 61(6), 1092-1096.