

An Atypical Case Of Tuberculous Otitis Media: The Importance Of Early Definite Diagnostic Surgery.

Van Thi Khanh Nguyen¹ , Chinh Hoang Quoc Chinh¹ , Anh Hong Le^{1*} , Ngoc Xuan Le¹ , Minh Thanh Nguyen²

¹ National Otolaryngology Hospital of Vietnam, Hanoi, Vietnam

² Hanoi Medical University, Hanoi, Vietnam

*Corresponding author: Anh Hong Le

**The authors declare the equally contribution in the presented research. There are no conflicts of interests in the presented study.

Abstract

Background: Tuberculosis can't be named a disease from the past. It is pity, but it remains actual and can be named a pandemic disease for some countries of the world. So, the diagnosis, especially of the untypical and rare cases, is still actual without taking care of the century history of the disease.

Objective: To report of an atypical case tuberculous otitis media flowing. To emphasize including tuberculous otitis media in the differential diagnosis and the importance of early surgery definite diagnostic.

Method: Case report and related reports review.

Results: Clinicians should always consider tuberculous otitis media in chronic otitis media differential diagnosis. It is especially actual in case of the absence of the effect to usual therapy. Should be taken into account the possibility of the tuberculous otitis media flowing when the facial paralysis, sensorineural or mixed hearing loss are fixed. One more predictor is pulmonary tuberculosis or a family history of tuberculosis. When the clinical and subclinical signs are not enough for a definite diagnosis, it is necessary to do exploratory surgery to obtain a definite diagnostic specimen. It helps early diagnosing and avoiding complications.

Conclusion: Tuberculous otitis media is a rare disease, clinical manifestations are atypical, easily confused with other diseases. So, it is necessary to taking into account the tuberculous otitis media when differential diagnosis and surgery for early diagnosis.

Keywords: Tuberculous otitis media (TOM), chronic otitis media (COM), definite diagnostic surgery.

1. Introduction

Tuberculosis (TB) infection remains a major health problem in developing countries, where more than 8 million new cases of TB are diagnosed every year [1]. Pulmonary tuberculosis is the most common clinical presentation, while 15-20% of cases are extrapulmonary or disseminated. The most common sites of extrapulmonary tuberculosis are lymph nodes (48.9%), pleura (25.5%), bones

(22.7%), genital urinary system (5.7%) and meninges (5 %). In extrapulmonary tuberculosis, tuberculous otitis media is extremely rare, accounting for only about 0.05-0.9% of chronic infections of the middle ear [2].

The pathogenesis of tuberculosis in the middle ear remains controversial. 3 mechanisms are explaining middle ear tuberculosis infection: tuberculosis bacteria enter the middle ear through blood, sputum inhalation through the Eustachian tube or by direct transmission through the outer ear canal and tympanic membrane perforation [3].

The classic presentations of tuberculous otitis media (TOM) are painless chronic otorrhea, multiple perforations of the tympanic membrane, pale granulation, hearing loss, facial paralysis [4]. However, current studies show that the clinical signs of tuberculosis are highly variable and atypical as the literature describes. When a patient suspected of having tuberculosis, a lung evaluation is needed because of a high proportion (up to 93%) of patients with pulmonary tuberculosis present with tuberculosis [5].

CT scan is the most valuable imaging method in the diagnosis of TB. The soft tissue attenuation in the entire middle ear cavity, preservation of the mastoid air cells without sclerotic change, and soft tissue extension to the external auditory canal (EAC) or mucosal thickening of the bony EAC had statistical significance between the TOM group and the chronic otitis media (COM) group with or without cholesteatoma. Erosion of the ossicles and scutum was statistically significant between the TOM group and the COM group [6]. A Korean study about the CT scan on 23 patients with TOM. Six patients (26.1%) revealed bony destruction that involved the cortex of either the external auditory canal or the outer cortex of the mastoid bone. One patient (4,3%) demonstrated marked bony destruction that involved the skull base, as well as the mastoid bone, and which demonstrated the features of tuberculous osteomyelitis that involved the skull base [7]. The characteristics in CT Scan images partly help physicians think about and diagnose TB early.

However, all of the above methods can not make a definite diagnosis of TB. According to the European guidelines for tuberculosis, the gold standard for the diagnosis and determination of TB is still microbiological, culture, drug-sensitive and histopathological tests of middle ear specimens [8]. The definitive diagnosis of tuberculosis is usually only achieved after surgical removal of specimens for histopathology, microbiological culture or specific tests (PCR, gene Xpert). As Yang-Sun's study in Korea on TOM, of the 53 patients studied, only 11 patients were diagnosed with tuberculosis without surgery, the remaining 42 patients were diagnosed after surgery to collect specimens [7].

The main treatment for TOM is anti-tuberculosis medicine with four combination antibiotics:

isoniazid, rifampicin, pyrazinamide và ethambutol [9]. Anti-tuberculous medicines are effective in most TOM patients. The course of medication should last for at least 9 months and surgical intervention should be coordinated with internal medicine when complications occur.

Delays in the diagnosis and treatment of tuberculous otitis media can lead to serious complications such as labyrinthine fistula, labyrinthitis, central nervous system infection or hearing loss and permanent facial paralysis.

Therefore, an understanding of clinical manifestations and diagnostic imaging of TOM is necessary to guide early diagnosis of tuberculosis, early surgical interventions to collect specimens when the diagnosis is unclear to help diagnose TOM from which early treatment to prevent serious complications.

The clinical case we present below is atypical, TOM with meningitis complications are diagnosed early by surgery, emphasizing the role of surgical exploration for early diagnosis of specimens.

2. Case Presentation

A 9-year-old girl presented with a headache when she was admitted to hospital on January 19th, 2019. She had 2 weeks history of otalgia, otorrhoea in the left ear, fever 37,5 oC, 1-week history of intermittent headache on the left side. She was diagnosed as usual COM, and treated with 3 courses of antibiotics. After that ear discharge condition had been stopped, but headache can not be solved. She had no previous history of TB or chronic otorrhoea.

On evaluation when admission, she is conscious. She had a mild fever, doesn't have facial paralysis, meningeal syndrome nor sign of increased intracranial pressure.

On endoscopy, there is a perforation in the anterior inferior quadrant of the left tympanic membrane. The right tympanic membrane presented normally. The left posterior auricular region is not swollen, not painful, and doesn't have a fistula (Fig. 1). Normal nose and throat without pus.

In laboratory values, the patient had a high amount of white blood cells 14,05 G/l, the other index was normal, chest X-ray was normal. The audiogram showed a mixed hearing loss on the left ear (Fig. 2).

On the CT scan image, it showed the soft tissue attenuation in the entire middle ear cavity and the mastoid air cells without sclerotic change (Fig. 3). Erosion of the ossicles is not presented. She demonstrated marked bony destruction that involved the petrous apex, the mastoid air cells, superior semicircular canal, vestibule. Thick meninges nearby were showed.

MRI findings are not specific with soft-tissue attenuation lesion in the entire middle ear cavity, bony destruction in petrous apex, thick meninges, no brain abscess.

With the information obtained, we thought that patient had subacute otitis media, can not exclude malignant causes. The patient was initially diagnosed with acute mastoid otitis, not excluding the temporal bone tumor, has been initially treated with IV antibiotics, anti-inflammatory medicines. After 3 days of treatment, she still has a headache and fever, especially when stopping IV Solu-medrol.

Although many colleagues agreed that this is a condition of usual acute mastoid otitis, should continue internal medical treatment, but we still decided to carry out exploratory surgery, to diagnose early for the patient.

January 24, 2019, after admission 5 days. The patient underwent exploratory surgery (Fig. 4). Intraoperative lesions are thick TM, TM perforation. Intraoperatively, the mastoid and the middle ear appeared entirely occupied by granulomatous material, Erosion of the long process of incus, intact stapy. At first, we suspected this is a temporal tumor, a biopsy was performed to do pathology (Fig. 5).

3 days postoperatively, the patient still has a headache and starts to have left facial paralysis grade III (The House–Brackmann score). Pathological findings are typical TB inflammation, 3 days postoperatively.

Right after that, the patient was referred to National Lung and Tuberculosis Hospital to treat TOM. On the first day in a new hospital, the patient starts to have clear symptoms of meningitis and encephalitis such as high fever, severe headache, neck stiffness, nausea and vomiting, Kernig's sign, mild paralysis, fecal incontinence, urinary incontinence. A prompt lumbar puncture was performed, CSF laboratory studies results were 350 cells/ mm³, Neutro 43%, lympho: 5%, Pandy (+) and bacterial culture positive with tuberculosis. Then she had a positive result in QuantiFERON-TB blood test.

The patient was started on a 12-months course of anti-tuberculosis treatment (ATT) 2SRHZE/10 RH. After 20 days of treatment, she recovered and was discharged from hospital with a normal condition: consciousness, no fever, no headache, no facial paralysis.

Endoscopic image after 7 months of treatment, the TM presented normal, and the audiogram show almost normal (Fig. 6).

3. Discussion

TOM was first reported in 1853, and the organism was first identified in an ear discharge in 1883. TOM is extremely rare, only 0.05% of COM so most clinicians often far down in the list of possible differential diagnoses.

The classic presentation of TB otitis media is painless chronic otorrhea, multiple perforations of the tympanic membrane, unilateral conductive hearing loss in the early stages, then progress to

either a mixed or sensorineural deficit. Several sources also include peripheral facial nerve paralysis among the classic symptoms. The other clinical findings include nasal congestion or sinusitis, periauricular lymphadenitis, tinnitus, and granulation tissue in the ear canal or middle ear cleft [4].

However, the actual manifestation of tuberculosis varies much more, A significant proportion of the patients do experience otalgia as opposed to the classic painless presentation. It has also been noted that otorrhea may be highly variable, being acute or chronic, constant or intermittent, light or profuse, and either serous or purulent. A single perforation in the TM appears to be more common than the previously reported multiple defects, although there is some evidence that multiple perforations may form early in the course and coalesce into larger defects.¹⁶

Granulation tissue usually is present in the ear canal, but is more frequently pale than beefy red [10]. Currently, many reports in the world, as well as Vietnam, show that the number of tuberculosis patients with closed eardrums is increasing. According to a report by Doan Thi Hong Hoa in 2016, the proportion of TOM patients with closed eardrum was 33% [11].

From the above case, we can see that the patient was admitted to the hospital mainly because of earache, severe headache and inflammatory manifestations such as purulent discharge, eardrum with 1 perforation, mild fever, increased white blood cell count, similar with a usual COM. But the patient did not respond to regular antibiotic treatments, including intravenous antibiotics, and the audiogram showed a mixed hearing loss, indicating that the lesion had spread to the inner ear, and the headache was very bad. From this information, we thought about other typical causes of inflammation, such as tuberculosis, syphilis, or malignancies such as lymphoma or Langerhans' cell histiocytosis.

On the CT Scan image, it showed the soft tissue attenuation in the entire middle ear cavity and the mastoid air cells without sclerotic change. Erosion of the ossicles is not presented. She demonstrated marked bony destruction that involved the petrous apex, the mastoid air cells, superior semicircular canal, vestibule. Thick meninges nearby were showed. Not similar to typical signs of TOM on CT Scan. In fact, this patients' CT Scan image leads clinicians to think about malignant causes.

TOM is extremely rare, only 0.05% of COM and is becoming less common after antituberculosis drugs are used [2], so most clinicians often far down in the list of possible differential diagnoses. The fact that TOM presents a variety of symptoms and it had similar symptoms and signs with usual COM so its differential diagnosis from non-TB COM may be quite difficult.

Moreover, getting middle ear pus for testing is quite difficult, low positive rate due to low sample amount, the patient has previously received antibiotic ear drops, or other superinfection bacteria, tuberculosis culture media are also not easy to make so the result is usually negative, result in delay the correct diagnosis [12-13].

Delayed diagnosis and treatment can lead to serious complications such as permanent facial paralysis or hearing loss, labyrinthitis, intracranial complications such as meningitis, encephalitis, brain abscess [14].

Histopathological examination is the most effective diagnostic tool for TOM. Histopathologic examination shows nonspecific changes consistent with chronic inflammation, but may also reveal more specific signs such as massive lymphocyte infiltration and granulation tissue with multinucleated giant cells, central caseation, or epithelioid cells [12-14].

Therefore, clinicians need to orient TB diagnosis early and do exploratory surgery to obtain a definite diagnostic specimen, which helps to diagnose early and avoid complications.

In this case, the patient has been treated with multiple antibiotics, now there is no longer purulent discharge, identify that the ear culture cannot be performed and clinically, the patient presents with acute headaches with suspected malignant lesions. After 5 days of hospitalization, medical treatment did not respond, the patient had been done exploratory surgery to obtain a definite diagnostic specimen.

3 days after surgery, the results of the histopathological examination are typical signs of tuberculosis and after that the patient has used tuberculosis treatment shortly, prevent meningitis complications timely.

From the actual above case, we found that although, TOM is extremely rare, but the clinicians must always include this disease in the differential diagnosis. Especially, in the differential diagnosis with: patients with otitis media do not respond to usual therapy, are accompanied by facial paralysis, dizziness, sensorineural or mixed hearing loss, painless otorrhea, pale granulation, COM with intact tympanic membrane, history of pulmonary tuberculosis or family history of tuberculosis.

The role of surgery in TOM treatment remains controversial. Some authors believe that surgery is not indicated when there are no complications or no evidence of ossicular chain erosion [15]. On the other hand, according to research by Kwon in 2010, higher rates of the dry ear are achieved when surgery preceded chemotherapy [16]. In 2000, Varty et al demonstrated that the combination of surgery and medical therapy improves prognosis [17]. As recommended by international guidelines: when TOM diagnosis is not accidental, surgery should be considered as first-line treatment [18-19]. Surgery remains mandatory in two cases: for a diagnostic purpose when the clinical suspicion is high and bacteriological and PCR analysis of ear discharge fails to identify the TB, and to complete treatment when chemotherapy is not sufficient, in order to eradicate the infectious process from the mastoid and middle ear.

In our opinion, when the definite diagnosis is not clear, whatever pathological suspicion, inflammation or tumors, benign or malignant, it is necessary to do exploratory surgery soon to obtain

a specimen, to do histopathological or microbiological examination which helps to diagnose early, initial treat early and avoid complications.

4. Conclusion

Clinicians must always include TOM in the differential diagnosis with COM especially patients with otitis media do not respond to usual therapy, are accompanied by facial paralysis, dizziness, sensorineural or mixed hearing loss, painless otorrhea, pale granulation, COM with intact tympanic membrane, history of pulmonary tuberculosis or family history of tuberculosis.

When the clinical and subclinical signs are not enough for a definite diagnosis, it is necessary to do exploratory surgery.

References

1. Corbett EL, Watt CJ, Walker N, et al. The growing burden of tuberculosis: global trends and interactions with the HIV epidemic. *Arch Intern Med.* 2003;163(9):1009-1021.
2. Vaamonde P, Castro C, García-Soto N, et al. Tuberculous otitis media: a significant diagnostic challenge. *Otolaryngology-Head and Neck Surgery.* 2004;130(6):759-766.
3. Awan MS, Salahuddin I. Tuberculous otitis media: two case reports and literature review. *Ear Nose Throat J.* 2002;81(11):792-794.
4. Skolnik PR, Nadol JB, Jr, Baker AS. Tuberculosis of the middle ear: a review of the literature with an instructive case report. *Rev Infect Dis.* 1986;8(3):403-410.
5. Kirsch CM, Wehner JH, Jensen WA, et al. Tuberculous otitis media. *South Med J.* 1995;88(3):363-366.
6. Rho MH, Kim DW, Kim SS, et al. Tuberculous otomastoiditis on high-resolution temporal bone CT: comparison with nontuberculous otomastoiditis with and without cholesteatoma. *AJNR Am J Neuroradiol.* 2007;28(3):493-496.
7. Cho YS, Lee HS, Kim SW, et al. Tuberculous otitis media: a clinical and radiologic analysis of 52 patients. *Laryngoscope.* 2006;116(6):921-927.
8. Migliori GB, Zellweger JP, Abubakar I, et al. European union standards for tuberculosis care. *Eur Respir J.* 2012;39(4):807-819.
9. Hoca N, Ogretensoy M, Dayioglu D, et al. Tuberculous otitis media—a case report. *Turkish Respir J.* 2008;9(1):48-50.
10. Wallner LJ. Tuberculous otitis media. *Laryngoscope.* 1953;63(11):1058-1077.

11. Hoa Doan Thi Hong. TOM: Clinical manifestations and advance in diagnosis. Vietnam Conference of Otolaryngology. 2016.
12. Yaniv E. Tuberculous otitis: an underdiagnosed disease. *Am. J Otolaryng.* 1987;8(6):356-360.
13. Sebastian SK, Singhal A, Sharma A, Doloi P. Tuberculous otitis media—series of 10 cases. *J Otology.* 2020;15(3):95-98.
14. Nishiike S, Irifune M, Osaki Y, et al. Tuberculous otitis media: clinical aspects of 12 cases. *Annals Otology, Rhinol & Laryngol.* 2003;112(11):935-938.
15. Saunders NC, Albert DM. Tuberculous mastoiditis: when is surgery indicated? *Int J Pediatr Otorhinolaryngol.* 2003;65(1):59-63.
16. Kwon M, Choi SH, Chung JW. Roles of an anti-tuberculosis medication and surgery in patients with tuberculous otitis media. *Acta Otolaryngol.* 2010;130(6):679-686.
17. Varty S, Vaidya D, Parasram K, et al. Tuberculous otitis media-are we missing it ? *Indian J Otolaryngol Head Neck Surg.* 2000;52(2):143-146.
18. Blumberg HM, Burman WJ, Chaisson RE, et al. American Thoracic Society/Centers for Disease Control and Prevention/Infectious Diseases Society of America: treatment of tuberculosis. *Am J Respir Crit Care Med.* 2003;167(4):603-662.
19. Nahid P, Dorman SE, Alipanah N, et al. Official American thoracic society/centers for disease control and prevention/infectious diseases society of America clinical practice guidelines: treatment of drug-susceptible tuberculosis. *Clinical Infectious Diseases.* 2016;63(7):e147-e195.

Firures

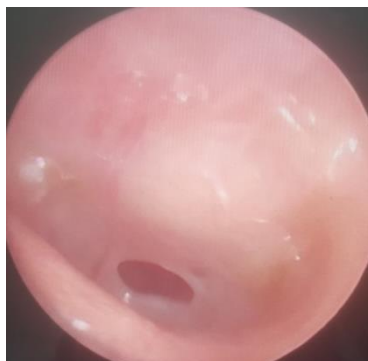


Figure 1. Endoscopic image of the left tympanic membrane

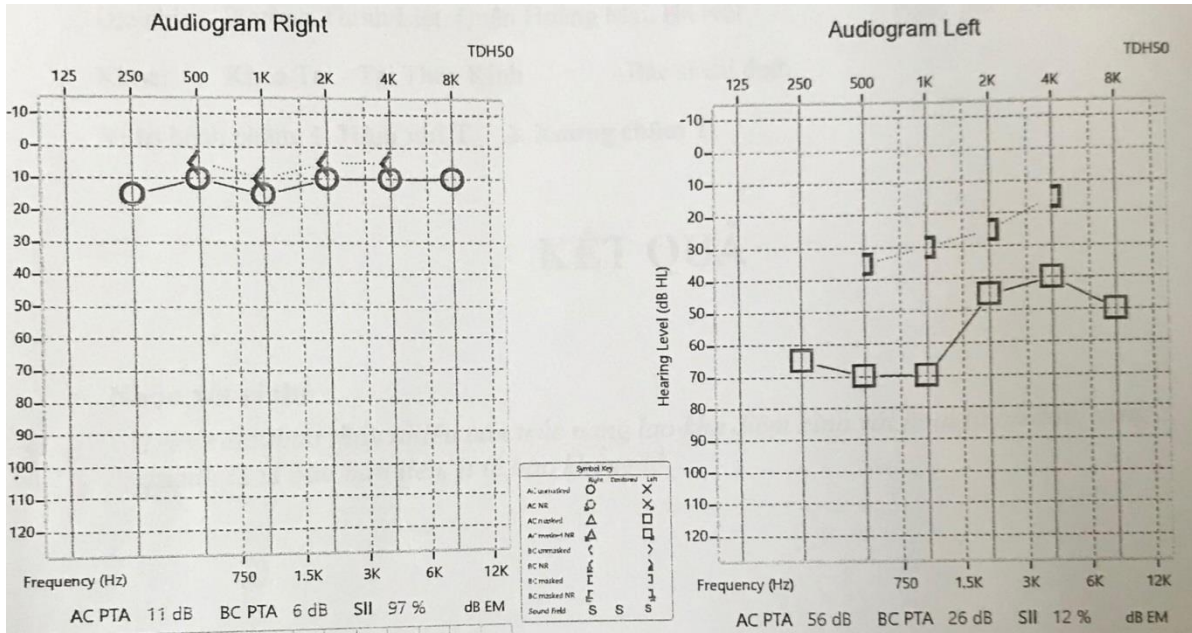


Figure 2. Audiogram showed a mixed hearing loss on the left ear

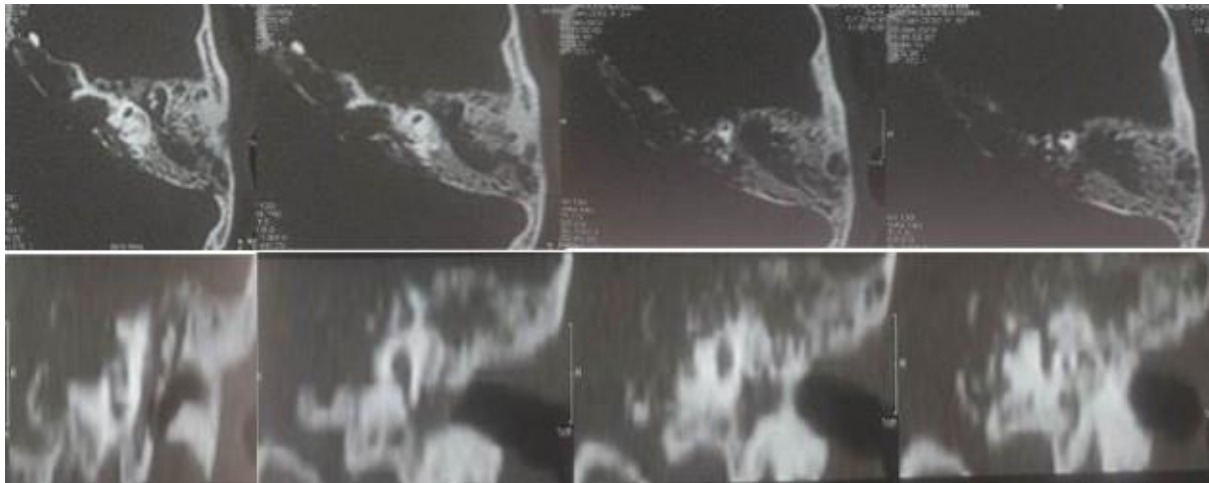
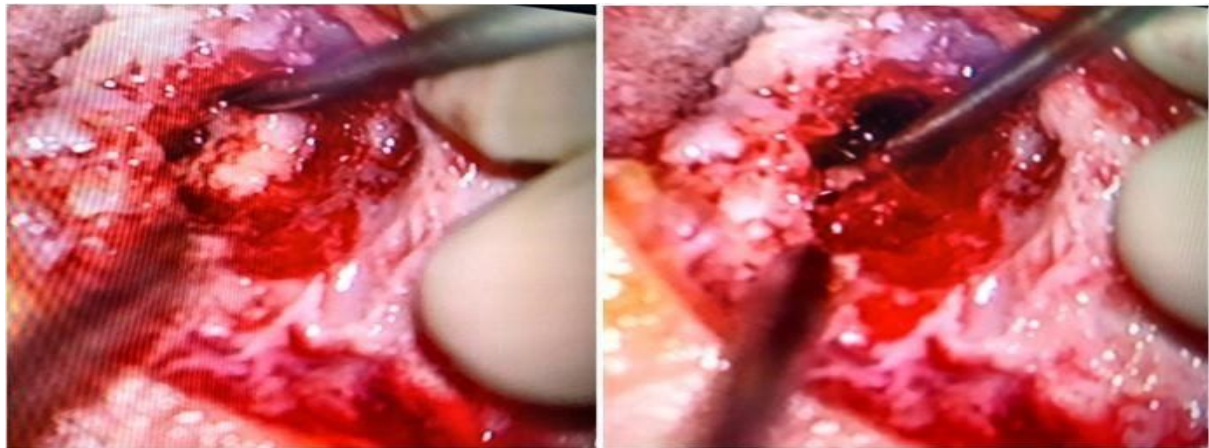

Figure 3. Computed Tomography Scan images

Figure 4. Intraoperative lesions



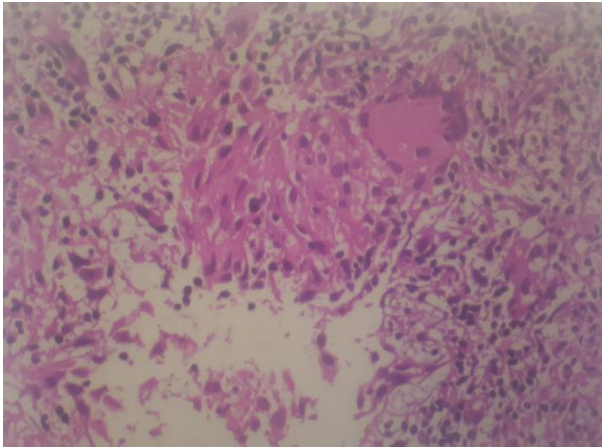


Figure 5. Histopathological examination

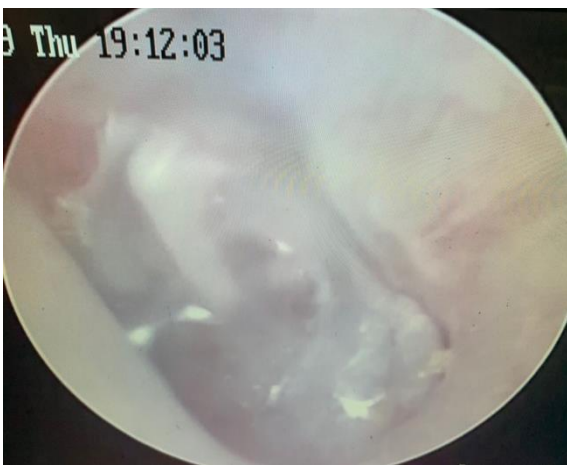

Figure 6. Endoscopic image after 7 months of treatment

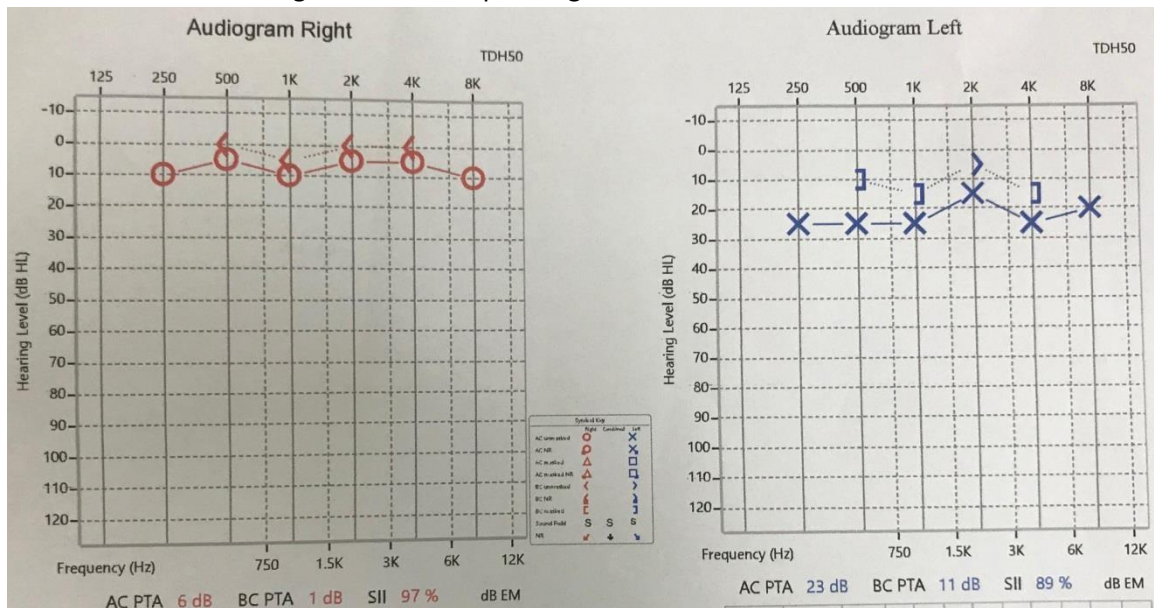


Figure 7. Audiogram after 7 months of treatment