

Abdominal Tb With Suspected Hollow Organ Perforation

Tri Putra Rahmad Ramadani Rambe¹ and M.Hidayat Surya Atmaja^{2*}

¹Radiology Specialization Programme, Department of Radiology, Faculty of Medicine, Airlangga University, Dr. Soetomo Hospital, Surabaya, Indonesia

²Department of Radiology, Faculty of Medicine, Airlangga University, Dr. Soetomo Hospital, Surabaya, Indonesia

Abstract

Tuberculosis is a disease caused by a bacterium called *Mycobacterium tuberculosis* which can affect the lungs and extrapulmonary tissues. According to the 2019 WHO TB report, the number of active TB cases reached 10 million people, with a death toll of 1.4 million people. To date, TB is still considered a global health burden, especially in developing countries such as Indonesia, which includes this bacterial disease in its national treatment program. In addition to pulmonary TB, there is also extrapulmonary TB which can attack various organs in the body. With the ability of tuberculosis bacteria to attack various organs, this extrapulmonary TB often causes several unusual symptoms. These atypical symptoms make it challenging to diagnose extrapulmonary TB; thus, this bacterial disease has relatively high morbidity and mortality rate. Abdominal TB is epidemiologically one of the comorbidities in 15% - 25% of pulmonary TB cases, and the abdomen is the sixth most frequently affected organ outside the lungs. Establishing the diagnosis of abdominal TB is quite challenging because it requires several modalities. The modalities that can provide important information to establish the diagnosis of abdominal TB include X-Ray, abdominal CT scan, and colonoscopy. This case report will discuss a case of abdominal TB with complications of peritonitis and is expected to provide an overview of the symptoms, diagnosis, and management of abdominal TB accompanied by peritonitis.

Keyword: Abdominal Tuberculosis, *Mycobacterium tuberculosis*, Multidrug Resistance, Peritonitis

Introduction

Establishing the diagnosis of abdominal TB is quite challenging because it requires several modalities. The modalities that can provide important information to establish the diagnosis of abdominal TB include X-Ray, abdominal CT scan, and colonoscopy. This case report will discuss a case of abdominal TB with complications of peritonitis and is expected to provide an overview of the symptoms, diagnosis, and management of abdominal TB accompanied by peritonitis.

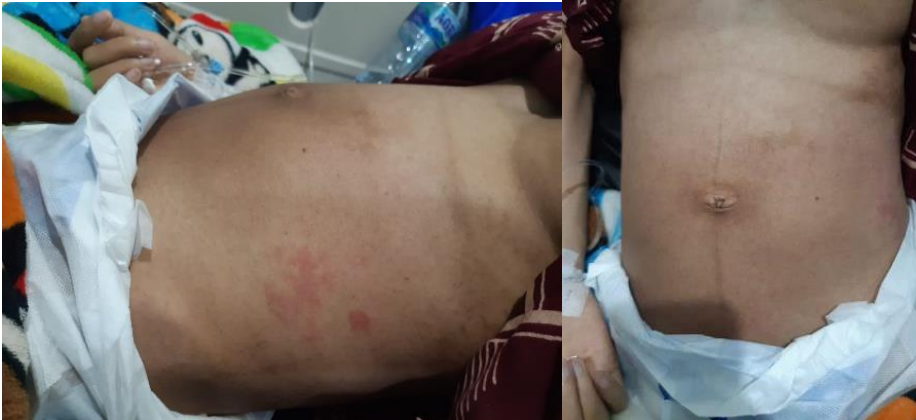Case Presentation

A 28-year-old female patient was admitted to the Emergency Department of Dr. Soetomo Hospital complaining of abdominal pain at night for one day. The location of the initial abdominal pain is not clear, but the patient then complained of dominant pain in the upper left, fever (-), vomiting once in the emergency department.

The patient previously had a history of multidrug-resistant pulmonary TB and had been outpatient since four days before the hospital admission. The administration of the drugs was stopped three days before the hospital admission because the patient complained of nausea while taking the drugs. The abdominal pain has been felt by the patient for approximately 15 days before the hospital admission and was examined at the Dr. Ramelan Navy Hospital and the patient was suspected of intestinal tuberculosis.

The physical examination of the patient's abdomen indicated abdominal tenderness and metallic sound (+) and liver dullness (+).

Figure 1. The clinical condition of the patient's abdomen



Laboratory Examination:

Parameters	Results
Leukocytes	12,800
Hb	11.8
PLT	756,000
SGOT/SGPT	19/48
GDA	161

BGA (3/12/2021)	Results
PH	7.5
PCO2	31
PO2	105
HCO3	24.2
BE	1

Radiological Examination:

Figure 2. X-ray of the chest on 3/12/2021 with the impression of active pulmonary TB

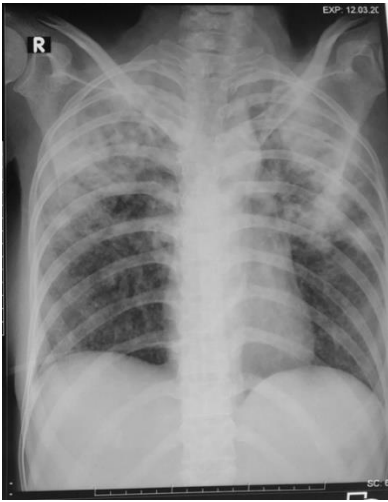

Figure 3. BOF and LLD x-ray on 3/12/2021 with the impression of a pneumoperitoneum and small bowel dilatation

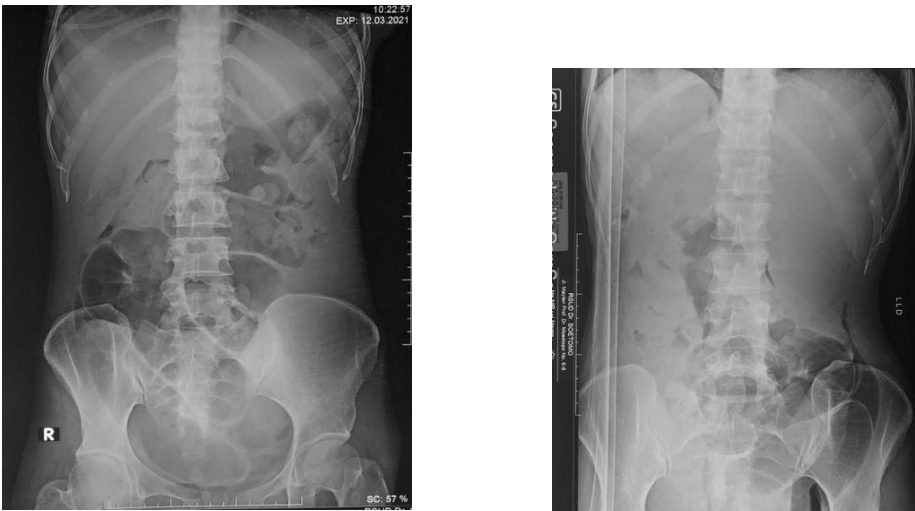
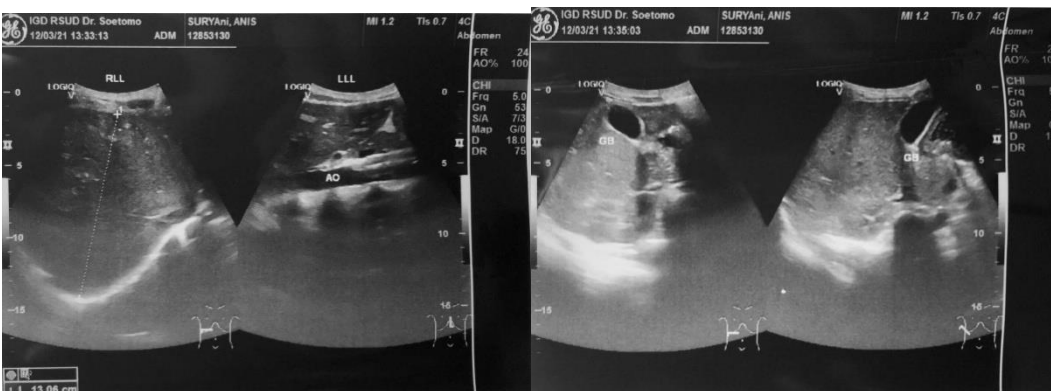
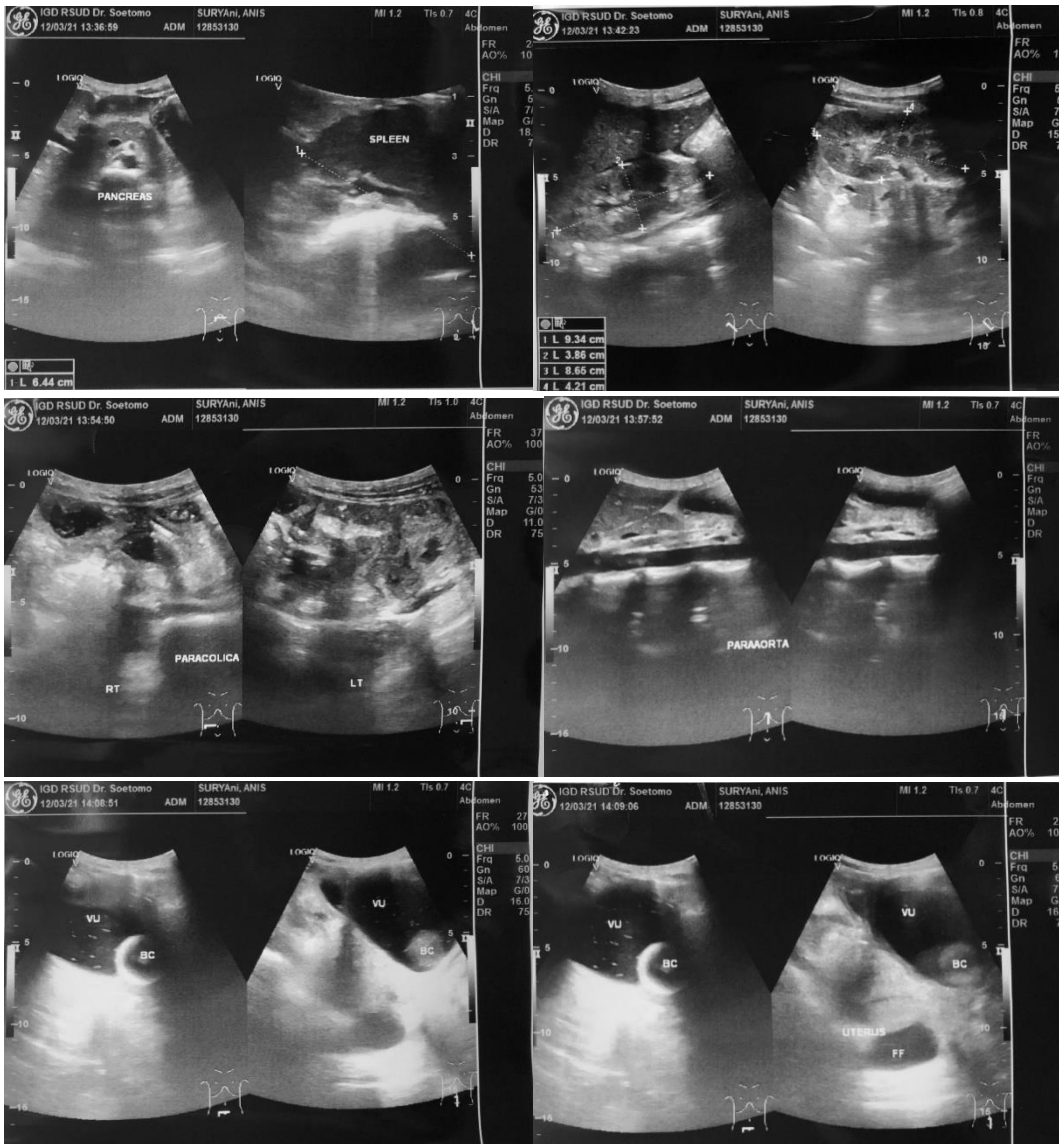
Figure 4. Upper lower abdominal ultrasound

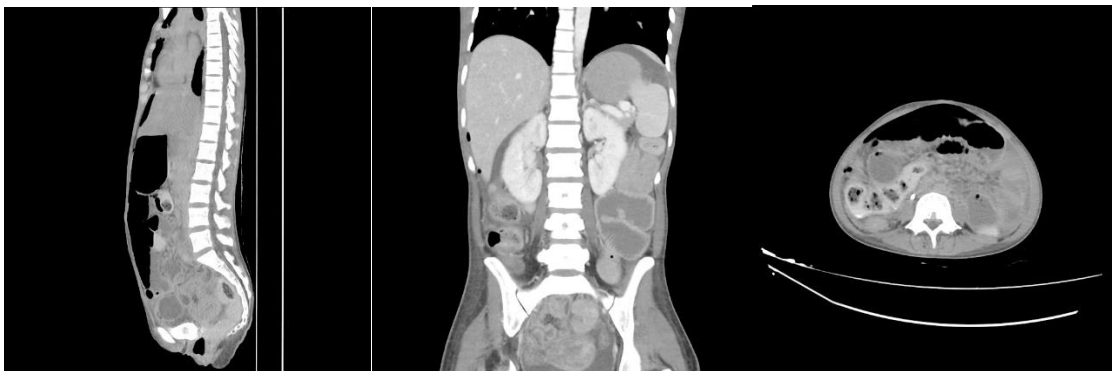

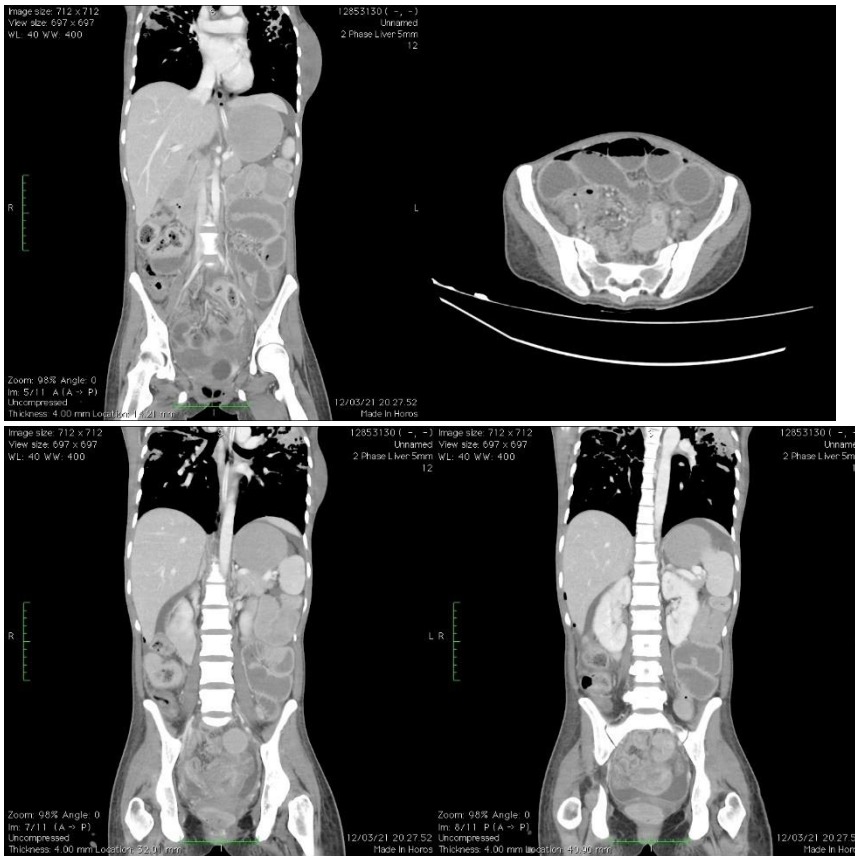


Impression:

- The presence of the appendix is not clearly visualized, transducer tenderness (+), retrocecal appendicitis cannot be ruled out.
- Minimal ascites in the abdominal cavity and in the rectouterine pouch
- Bowel wall thickening

Figure 5. Abdominal CT Scan with and without contrast:





Abdominal CT Scan with and without contrast:

Impression:

- Pneumoperitoneum suspected ec perforated appendicitis
- Small bowel obstruction et causa peritonitis TB DD/: adhesive perforated appendicitis
- Hepatomegaly
- Ascites
- Pulmonary TB with varicose bronchiectasis and military pattern

The patient was treated in the pulmonary high care unit. After external drainage was performed, the patient's physical examination showed the general condition: Weak

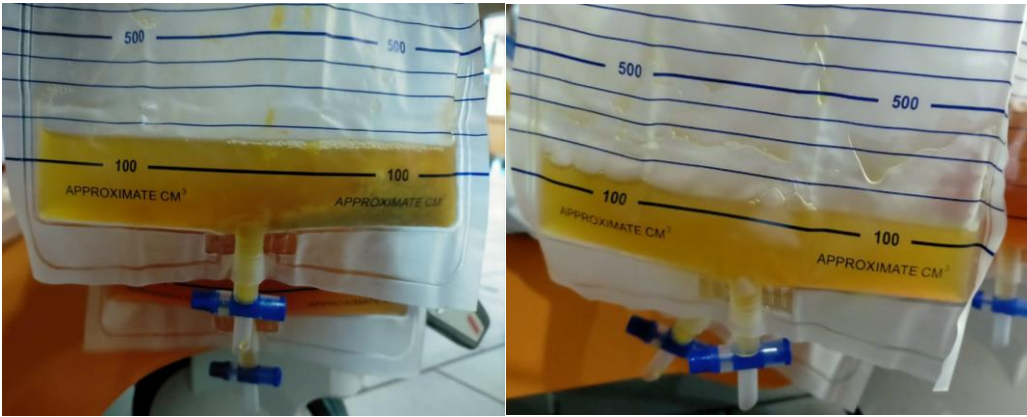
- HR : 98 times/minute
- RR : 28 times/minute
- Temperature: 36 degrees centigrade
- Saturation: 97% O2 Mask
- The abdominal examination indicated bowel sounds (+) and no increase in abdominal circumference

The patient was then tested for geneXpert TB with the following results:

GeneXpert Feces:	MTB detected and resistance R
GeneXpert peritoneal fluid:	MTB Not detected

The patient was then treated with anti-tuberculosis drugs. The patient returned home recovering and underwent routine check-ups to the pulmonary polyclinic

Figure 6. The external drainage indicated peritoneal fluid mixed with pus 300 ml



Discussion

Peritoneal tuberculosis is an inflammation of the parietal or visceral peritoneum caused by a bacterium called *Mycobacterium tuberculosis*. This disease affects the entire peritoneum, gastrointestinal system organs, mesentery, and internal genital organs.

This disease rarely stands alone and is usually a continuation of the tuberculosis process elsewhere, especially from pulmonary tuberculosis, but it is often found when it is diagnosed that the pulmonary tuberculosis process is no longer present. It might happen when the pulmonary TB had been healed first while the spread was still ongoing.

The peritoneum can be infected by tuberculosis in several ways:

- a. Through hematogenous spread, mainly from the lungs;
- b. Through the infected bowel wall;
- c. From the mesenteric lymph nodes; and
- d. Through an infected fallopian tube.

In most cases, peritoneal tuberculosis occurs not as a result of continuous spread, but often due to reactivation of a latent process that occurs in the peritoneum acquired through the hematogenous spread of a previous primary process (latent infection “Dorman infection”).

Tuberculosis lesions, as is well known, can be suppressed and healed. The infection is still in the latent phase when it can stay latent for life, but the infection can develop into tuberculosis at any time. If these intracellular organisms begin to multiply rapidly, it may lead to three forms of tuberculous peritonitis:

1. Exudative form

This form is also known as the wet form or the profuse form of ascites, with prominent symptoms of an enlarged and fluid-filled abdomen (ascites). Adhesion is rarely found in this form. Tubercles are often found in small yellowish-white miliary nodules, appear scattered in the peritoneum or the body organs inside the peritoneal cavity. In addition to the small particles, the larger tubercles are up to the size of a peanut. Around the tubercles, there is a reaction of the peritoneal tissue in the form of vascular congestion. Exudates can form quite a lot, covering the tubercle and peritoneum and changing the abdominal wall, which becomes tense. Ascitic fluid sometimes mixes with blood and looks reddish, so malignancy is possible. Omentum can be affected so that there is thickening and it is palpable like a tumor lump.

2. Adhesive form

Also referred to as dry or plastic form in which less liquid is formed. Adhesion is more common in this form. Extensive adhesions between the bowel and peritoneum often generate a tumor-like appearance, sometimes forming a fistula due to the presence of adhesions. Sometimes a fistula is formed due to adhesions of the bowel wall and parietal peritoneum, creating a necrosis process. This form often causes obstructive ileus and generates larger tubercles.

3. Mixed form

Also called a cyst, this swelling occurs through the process of exudation together with adhesion so that fluid forms in the pockets of the adhesions. Some authors consider that this division is more focused on the level of disease, in which the exudative form occurs first and then followed by an adhesive form (2). Histopathology of peritoneal biopsy tissue will show tuberculous granulation tissue consisting of epithelial cells and Langhans cells, and shock is generally found (2,9).

Conclusion

It can be concluded that the establishment of abdominal TB requires a variety of imaging. CT scan has been proven to be superior to other modalities (USG, and plain abdominal radiographs). Fast therapy enforcement can assist in providing fast and appropriate therapy, and it is expected to increase the patient's recovery rate.

Acknowledgments

No author received financial or material support for the research and the work. No author has a financial or proprietary interest related to the research.

Disclosure

None of the authors have a conflict of interest to declare in relation to this work.

References

1. Abu-Zidan, F.M., & Sheek-Hussein, M. (2019). Diagnosis of abdominal tuberculosis: lessons learned over 30 years: pectoral assay. *World J Emerg Surg*, 14, 33.
2. Cavalli, Z., (2016). Clinical Presentation, Diagnosis, and Bacterial Epidemiology of Peritoneal Tuberculosis in Two University Hospitals in France. *Infectious Diseases and Therapy*, 5(2), 193–199.
3. Debi, U., Ravisankar, V., Prasad, K.K., Sinha, S. K., Sharma, A. K. (2014). Abdominal tuberculosis of the gastrointestinal tract: revisited. *World J Gastroenterol*, 20(40), 14831-14840.
4. Dong, P., (2015). Intraperitoneal tuberculous abscess: Computed tomography features. *World journal of radiology*, 7(9), 286–93.
5. Farhadian, S., Shenoi, S. V., & Villanueva, M.S., (2014). A 33-year-old haitian immigrant with 7 months of abdominal pain and progressive distension. *BMJ Case Reports*, 1–4.
6. Kim, H.K. (2017). A Case of Tuberculous Peritonitis Presenting as Small Bowel Obstruction. *Korean J Gastroenterol*, 69(5), 308–311.
7. Na-ChiangMai, W., Pojchamarnwiputh, S., Lertprasertsuke, N., Chitapanarux, T. (2008). CT findings of tuberculous peritonitis. *Singapore Med J*, 49(6), 488-91.
8. Shivde, R., Patel, K., Mittal, S., Prasla, S. (2016). Ultrasound findings in abdominal tuberculosis: Usual and unusual Appearances. *National Journal of Medical and Allied Sciences*, 5(2), 64-69.
9. Sanai, F.M., & Bzeizi, K.I. (2005). Systematic review: Tuberculous peritonitis – Presenting features, diagnostic strategies and treatment. *Alimentary Pharmacology and Therapeutics*, 22(8), 685–700.
10. Sharma, M. P., Bhatia, V. (2004). Abdominal tuberculosis. *Indian J Med Res*, 120(4), 305-15.
11. Skopin, M. S., Batyrov, F. A., Kornilova, Z.Kh. (2007). The prevalence of abdominal tuberculosis and the specific features of its detection. *Probl Tuberk Bolezn Legk*, 1, 22-6.

12. Srivastava, U. et al., 2014. Tuberculous peritonitis. *Radiology Case Reports*, 9(3), p.971.
13. Varona Porres, D. et al., 2017. Radiological findings of unilateral tuberculous lung destruction. *Insights into Imaging*, 8(2), pp.271–277.
14. Wariyapperuma, U.M.,&Jayasundera, C.I.W. (2015). Peritoneal tuberculosis presenting with portal vein thrombosis and transudative Ascites - a diagnostic dilemma: Case report. *BMC Infectious Diseases*, 15(1), 1–4.
15. Weledji, E.P., Pokam, B.T. (2017). Abdominal tuberculosis: Is there a role for surgery?. *World J Gastrointest Surg.* 9(8), 174-181.