

## Effects Of Montelukast On Imiquimod-Induced Model Of Psoriasis In Mice

Atheer Majid Rashid Al-juhaishi<sup>1</sup> ; Adeb Ahmed Kadhim Al-Zubaidy<sup>2</sup> ; Jinan Mohammed Mohsan Al-Mousawy<sup>3</sup>

<sup>1</sup>Assistant Professor in Department of Clinical Pharmacy, College of Pharmacy/University of Karbala, Iraq.

<sup>2</sup>Professor in Department of Pharmacology, College of Medicine /Al-Nahrain University, Iraq.

<sup>3</sup>Lecturer in Department of Pharmaceutics, College of Pharmacy/University of Karbala, Iraq.

---

### Abstract:

Psoriasis is a chronic autoimmune-mediated skin disease characterized by abnormal increase in proliferation and uncontrolled differentiation of the epidermal keratinocytes, with a rapid turnover rate of the epidermal cell. Montelukast is a leukotriene receptor antagonist and had secondary anti-inflammatory properties made it able to target many immune cells (like eosinophils, monocytes, and corticosteroid insensitive neutrophils proposing) and an inhibitory effect on inflammatory cytokines. The present study aimed to evaluate the potential activity of topical Montelukast against imiquimod- induced psoriasiform skin inflammation in mice. A total of 30 Swiss albino mice were allocated randomly into 5 groups (of 6 mice each) and shaved on back. Base gel was topically applied on 1<sup>st</sup> and Imiquimod (5%) gel was topically applied on the remaining 4 groups daily for 6 days. The 3<sup>rd</sup>, 4<sup>th</sup> and 5<sup>th</sup> groups with imiquimod-induced psoriasiform skin inflammation were treated topically with clobetasol ointment, montelukast (5%) gel, montelukast (1%) gel daily for next 6 days. At end, the animals were sacrificed and skin was taken for measuring certain inflammatory biomarkers levels and for histopathological study. Montelukast could significantly attenuate the severity of psoriatic lesion score and decrease the inflammatory cytokines namely TNF  $\alpha$ , IL-17, and IL-23. In conclusion, the present results suggested that topically applied montelukast gel exhibited significant anti-psoriatic and anti-inflammatory activities in imiquimod-induced psoriasiform skin inflammation in mice.

---

### Introduction:

Psoriasis is a chronic autoimmune-mediated skin disease characterized by abnormal increase in proliferation and uncontrolled differentiation of the epidermal keratinocytes, with a rapid turnover rate of the epidermal cell. This disease has no cure and available therapy only to relieve symptoms. It can occur at any age especially in the age between 50–69 years<sup>1</sup>. The feature of psoriatic lesions generally consists of symmetrical, red papules which are wrapped with white or silver scale and sharply demarcated that occur particularly over the extensor surfaces and scalp<sup>2</sup>. The extension and acuteness of psoriasis change widely from period to period and between individuals. Morphological variants are

common. Both genetic and environmental influences have a critical role in the etiology and pathogenesis of psoriasis<sup>3</sup>. After some inciting episode, whether it was infectious or traumatic, activation of innate immune cells like plasmacytoid dendritic cells in the epidermis which released proinflammatory cytokines such as IFN- $\alpha$  and TNF  $\alpha$ . Then, these cytokines stimulated myeloid dendritic cells to produce IL-23 and IL-12 via activated Janus kinase (JAK)-signal transducer and activator of transcription (STAT) pathway. In lymphoid tissue, epidermal antigen presenting cells like Langerhans cell presented target antigen and activated Naïve T cells via released IL-12 and IL-23 which were essential to differentiation of T-cells into Th1, cytotoxic T cell (Tc1) or Th17 cells. Consequently, activated T-cells migrated to the skin where they stimulate the production of a range of cytokines and factors, which interact to produce changes within the resident epidermal and dermal cells<sup>4</sup>. Topical application of imiquimod (IMQ) is reported as a novel mouse model for psoriasiform skin inflammation by inducing acanthosis, parakeratosis, and a mixed inflammatory infiltrate which are mediated via the IL-23/IL-17 axis. Imiquimod activated IL-23 producing Langerhans cells and thereby activated IL17 and IL22 producing Th17 cells, are functionally involved in the pathogenesis of human-like psoriasis. These lesions showed increased epidermal proliferation, abnormal differentiation, epidermal accumulation of inflammatory cells and neoangiogenesis<sup>5</sup>. Montelukast is a leukotriene (LT) receptor antagonist family of medication; it acts by blocking the action of LTD<sub>4</sub> in the lung resulting in reduced inflammation and bronchodilation. It is used for management of a number of conditions like asthma, exercise induced bronchospasm, allergic rhinitis, and urticaria<sup>6</sup>. The present study aimed to evaluate the potential activity of topical Montelukast gel against Imiquimod-induced psoriasiform skin inflammation in mice.

#### **Materials and methods:**

Montelukast sodium (purity 99.8%) was purchased from pioneer medicine factory/Iraq. Imiquimod (5% )cream (Aldra) of MEDA Company was took up from community pharmacies. Chemicals used in the present study for preparation of Montelukast gel were purchased from different standard firms. Montelukast (1% & 0.5%) were formulated according process mentioned by Pharmacopeia, 2013 with no skin irritation after applied on the skin of volunteers and good uniformity content of  $93.75\% \pm 0.72$  for 0.5% strength and  $98\% \pm 1.15$  for 1% strength<sup>7</sup>.

A total of 30 apparently healthy male adult Swiss albino mice (24-33 g, 11- 15 weeks) were obtained from the animal houses of College of Medicine / Al-Nahrain University and National Center for Drug Control and Research. The animals were housed in polypropylene cages and fed on a standard pellet diet and water ad libitum under standard conditions ( $22 \pm 3^{\circ}\text{C}$ , 50 – 60% relative humidity, and 12 hours light – dark cycles). Prior to start of the experiments, mice were allowed to acclimatize in laboratory circumstances for period of two weeks. The Ethics Committee of Higher Education of College of Medicine / Al-Nahrain University approved the experimental protocol.

Area of about 2 cm<sup>2</sup> on the back of each mouse had been shaved for topical application. The included mice were allocated randomly and equally into 5 groups; these groups were as follows: Group 1 (Control group): base gel was applied daily on the shaved area for six days. Group 2 (Induction group): 62.5 mg of IMQ cream (5%) was applied daily on the shaved area for six days. After psoriasiform skin inflammation being induced (as what happened in group 2) the inflamed area was treated topically for further six

days with daily application of either Clobetasol ointment (0.05%) (Group 3), Montelukast gel (0.5%) (w/v) (Group 4), or montelukast gel (1%) (w/v) (Group 5). During the experiment the clinical signs were noticed and scored with the aid of psoriasis area and severity index (PASI). The skin thickness of the right ear measured in duplicate using a digital micrometer caliper and scored. Erythema and scaling of mouse back shaved skin were scored independently on a scale from 0 to 4 (0: none; 1: slight; 2: moderate; 3: marked; 4: very marked). The level of erythema was scored using a scoring table with red taints (0: No lesion; 1: Slightly pink; 2: Pink; 3: Red; 4: Dark red). The cumulative score (erythema plus scaling plus thickening) served as a measure of the severity of inflammation (scale 0 –12)<sup>8 9</sup>. At the end of the experiment, all the mice were euthanized by ether and the skin samples were obtained for measurement of the biomarkers and for histopathological examination.

### Preparation of Tissue Homogenate

Freshly harvested back skin tissue of 1 gm stored in 9 ml of phosphate buffered saline. Tissues were homogenized by mortar and pestle, then centrifuged by cool centrifuged adjusted to 5000 rpm for 10 minutes. The supernatants were frozen at (-80 °C) for further measurements<sup>1</sup>.

### Measurement of Biomarkers

The concentration of tissue TNF- alpha, IL 17, and IL 23 were measured using ELISA technique (shanghai, china). This assay employs the quantitative sandwich enzyme immunoassay technique<sup>10</sup>.

### Histopathological examination and scoring:

Skin tissues from different groups were preserved in neutral buffer formalin (10%), embedded in paraffin using standard method. The paraffin tissue blocks underwent serially section to obtain consecutive levels, and then stained with hematoxylin and eosin<sup>11</sup>. They were examined under a light microscope and scored using baker's score system to evaluate the pathological alterations on a scale ranging from 0 to 10 as shown in table (1)<sup>12</sup>.

**Table (1): The Baker's scoring system<sup>12</sup>.**

Score	Items	
2	Munro abscess	Keratin
0.5	Hyperkeratosis	
1	Parakeratosis	
0.5	Thinning above papillae	Epidermis
1.5	Lengthening and clubbing of rete ridges	
0.5	Acanthosis	
1	Lack of granular layer	
	Lymphocytic infiltrate	Dermis
0.5	Mild	
1	Moderate	
2	Marked	
0.5	Papillary congestion	

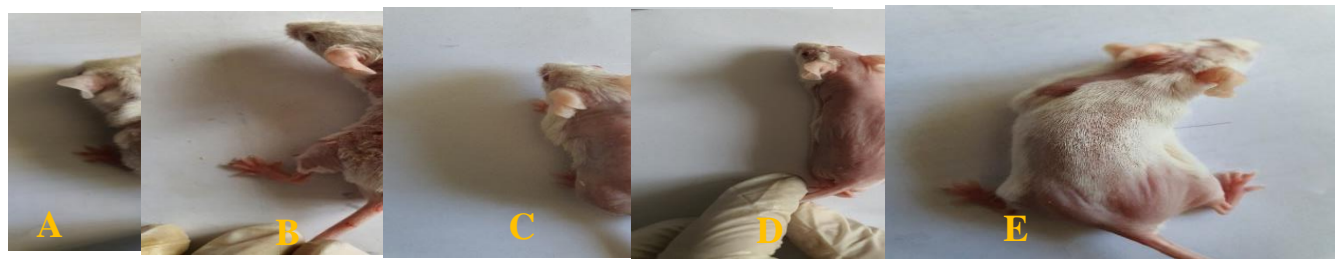### Statistical Analysis

Statistical analysis was performed using Statistical Package for Social Sciences (SPSS 22). Descriptive statistics for the numerical data were formulated as mean and standard error of the mean (Mean  $\pm$  SEM) after triplicate sample analysis especially for pharmaceutical assays. Numerical data were analyzed using either independent t test or one-way analysis of variance (ANOVA) test with post hoc Tukey test. The non-descriptive data measured by using Mann-Whitney U test. The P values less than 0.05 were considered statistically significant<sup>13</sup>.

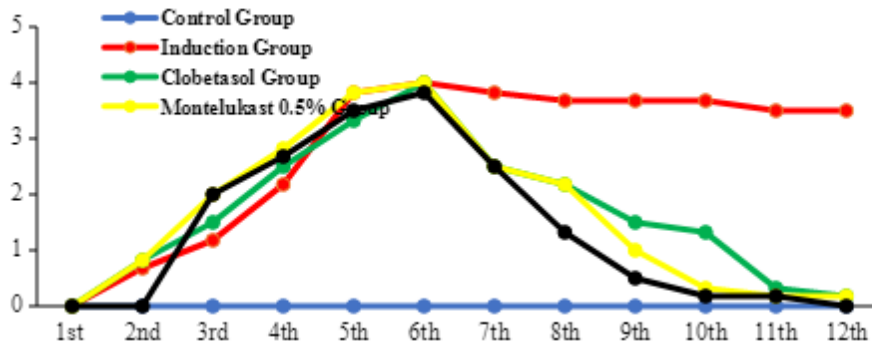
**Results:**

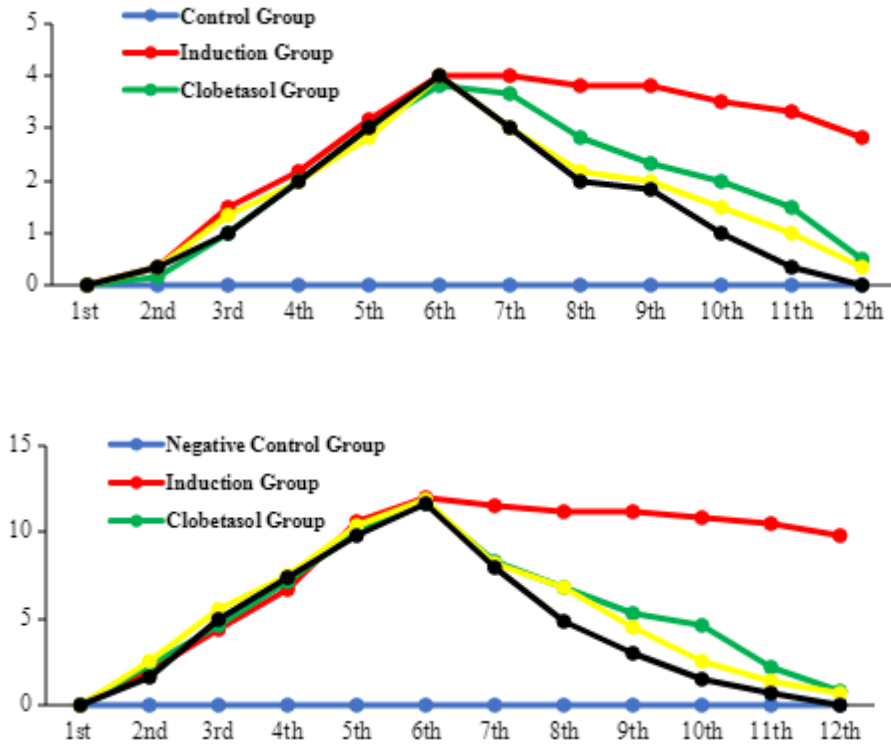
**Effects of tested drugs on Scoring severity of psoriasiform skin inflammation**

The induction group (Group 2) showed a significant increase in psoriatic score severity including erythema, scaling, thickening, and cumulative scores when being compared to negative control group (Group 1) ( $P < 0.05$ ) (Figures 1 & 2). Clobetasol ointment (0.05%) significantly reduced the severity of psoriatic lesion scoring in psoriatic induced mice when being compared with induction group ( $P < 0.05$ ) (Figures 1 & 2). Each of montelukast gels (0.5% & 1%) (Groups 4 & 5 respectively) significantly declined severity of psoriatic skin lesion score induced by imiquimod when being compared with induction group ( $P < 0.05$ ). There were no significant differences among both strengths (0.5% & 1%) of montelukast and clobetasol ointment (0.05%) (Group 3) on scoring severity of psoriatic lesion ( $P < 0.05$ ) (Figures1 & 2).



**Figure (2): Scoring severity of psoriasiform skin inflammation of the experimental groups at end of the experiment. A: Control group (Group 1); B: Induction group (Group 2); C: Clobetasol ointment (0.05%) group (Group 3); D: Montelukast gel (0.5 %) (Group 4); E: Montelukast gel (1 %) (Group 5)**





\*: Significant effect compared to Induction Group at  $P < 0.05$ .

#: There were no significant differences ( $P > 0.05$ ) among montelukast (0.5% & 1%) groups and clobetasol ointment (0.05%) group.

**Figure (1):** The effect of montelukast on scoring severity of psoriasiform skin inflammation through the trial period. A: erythema score; B: Scaling score; C: thickness score; D: cumulative score.

**Effects of tested drugs on levels of tissue biomarkers**

Imiquimod significantly elevated tissue levels of TNF  $\alpha$ , IL17, and IL23 in comparison with control group ( $P < 0.05$ ) as shown in table (2) and Figure (3). Clobetasol significantly lowered the levels of tissue biomarkers in comparison with induction group ( $P < 0.05$ ) as shown in table (2) and Figure (3). Montelukast gels (0.5 & 1%) significantly decreased the levels of tissue biomarkers in comparison with induction group ( $P < 0.05$ ). There was incomparable between montelukast 0.5% and clobetasol, however montelukast 1% had significant reduced inflammatory cytokines in compared with clobetasol group and montelukast 0.5% group at  $P < 0.05$  as shown in table (2) and Figure (3).

**Table (2):** Effects of test drugs on levels of tissue biomarkers

Groups (Mean ± SEM)					Biomarkers (pg/g)
Montelukast gel (1%)	Montelukast gel (0.5%)	Clobetasol ointment (0.05%)	Induction	Control	
666.41±53.92*	856.19±52.43*	1030.17±47	1390.84±59.88	585.5±38.72	TNF α
147.16±7.73*	254.52±12.1*	292.56±8.85	566.01±13.82	122.25±4.85	IL17
66.17±5.87*	84.37±3.81 <sup>§</sup>	87.1±7.31	152.22±5.2	73.01±9.4	IL23

\*: Significant effect (P<0.05) compared to other groups.

§: There were no significant differences among clobetasol group and montelukast 0.5% gel group at P <0.05.

**Figure (3): Effects of Montelukast on the levels of tissue biomarkers.**

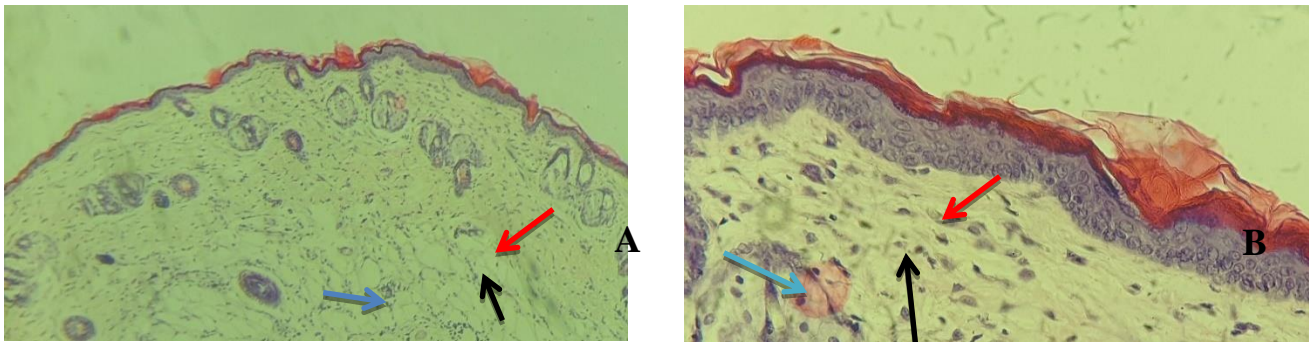
**Effects of the tested drugs on histopathological features of skin**

The histological features of control group differentiated by the spread of keratin layer without Munro abscess and no changes in the thickness of epidermis layer, no rete ridges, and presence of granular layer as shown in figure (4). Imiquimod caused significant histopathological changes characterized by Munro abscess, hyperkeratosis, abnormal thickness of epidermis, thinning above papillae, presence of rete ridges, and lack of granular layer when compared with control group at p < 0.05 as shown in figure (5) and table (3). The histopathological features of clobetasol ointment (0.05%) group characterized by thinning of epidermal thickness and mild infiltration of inflammatory cells as shown in figure (6). Clobetasol had significant restorative effect on psoriatic lesion in compared with induction group at p < 0.05 as shown in tables (3). The histopathological features of montelukast (0.5% & 1%) groups characterized by normal spread of keratin and epidermal thickness as shown in figures (7 & 8); besides, there were no significant differences among montelukast (0.5%), Montelukast (1%), and clobetasol ointment (0.05%) groups at P <0.05 as shown in tables (3).

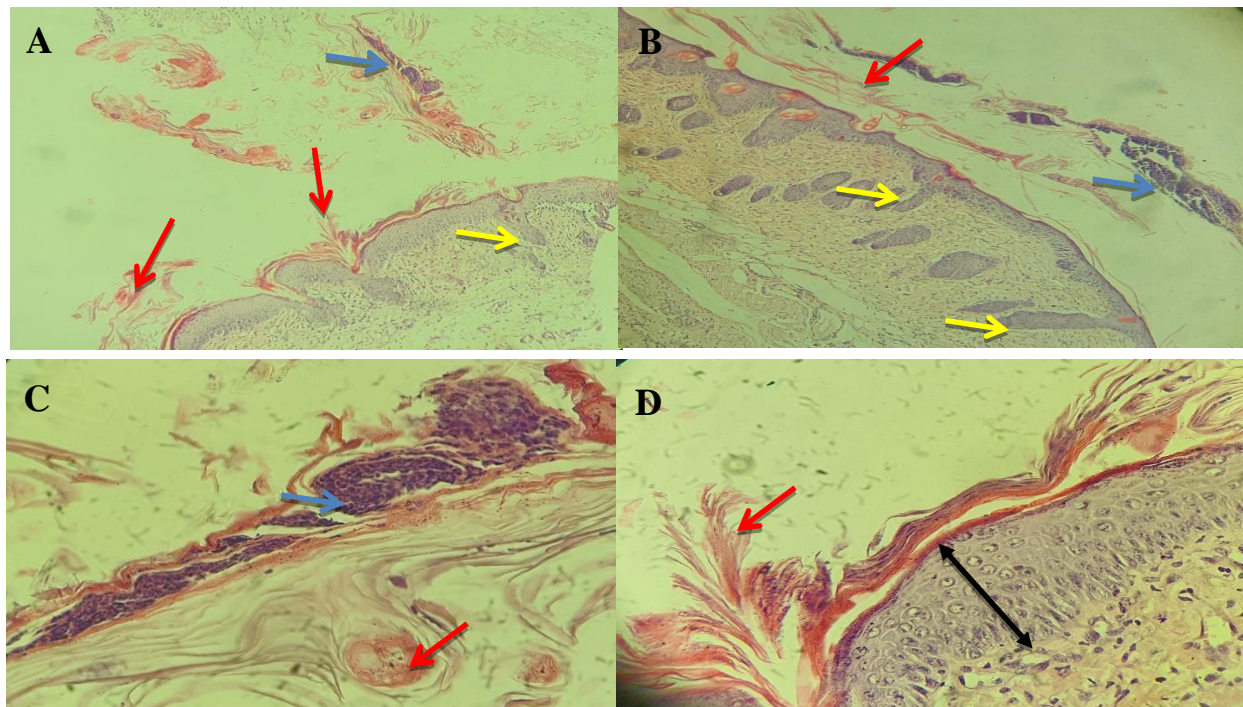
**Table (3) Barker's score of all experimental groups**

Groups	Barker's scores Mean ± S.E
Control Group	0 ± 0
Induction Group	8.58 ± 0.71*
Clobetasol Group	0.58 ± 0.23
Montelukast 0.5% Group	0.58 ± 0.23
Montelukast 1% Group	0.08 ± 0.02

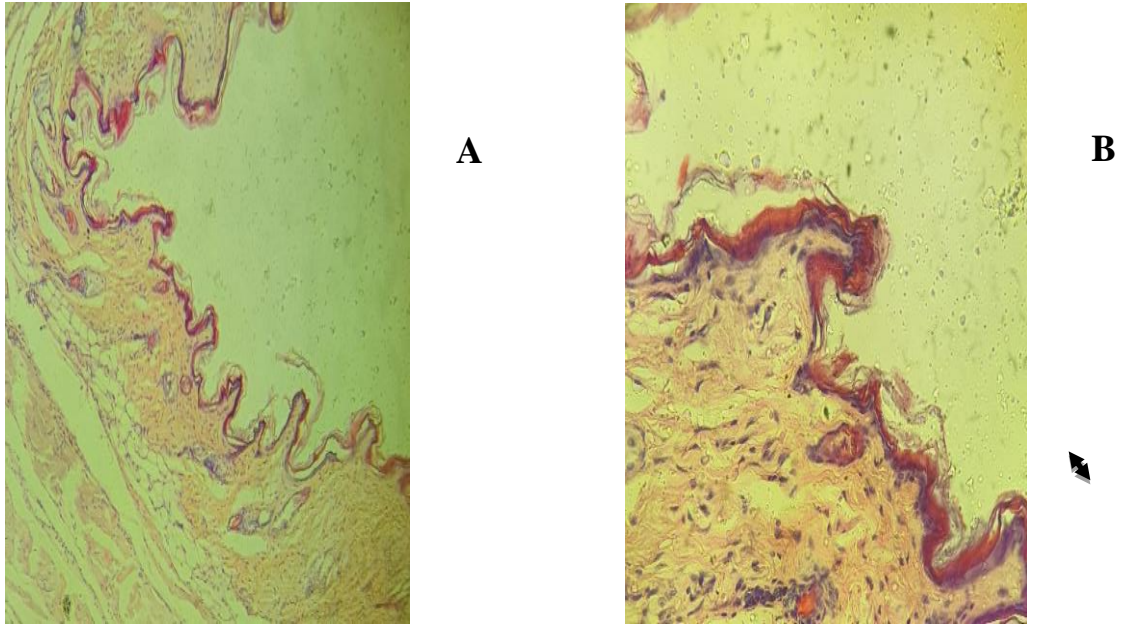
\*: means  $p \leq 0.05$  when induction group compared to all other groups.



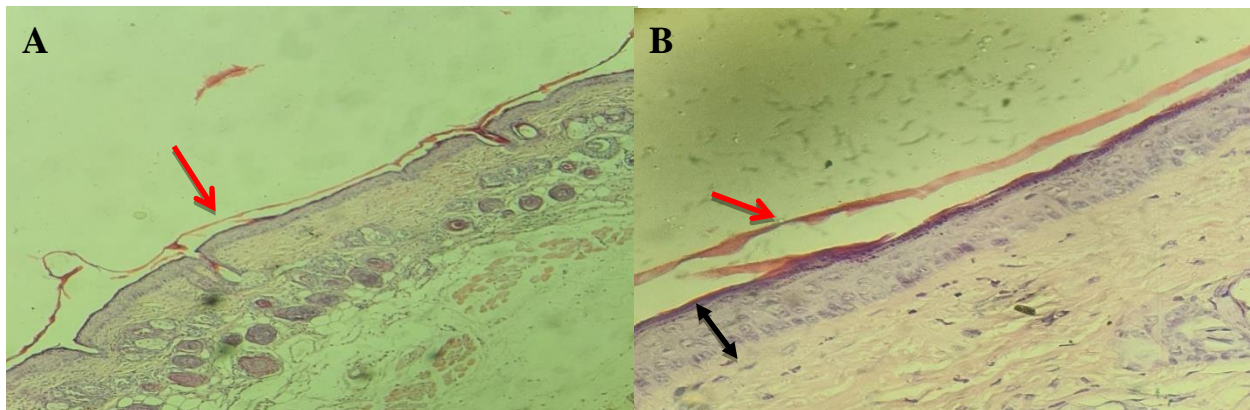
**Figure (4):** Skin section from mice back skin of control group showing normal spread of keratin, normal thickness of epidermis, and presence of granular layer (red arrow: keratin; black: epidermis layer; blue: dermal layer. H&E (A) 10X & (B) 40X).



**Figure (5):** Skin section from mice back skin of induction group showing Munro abscess, hyperkeratosis, abnormal thickness of epidermis, thinning above papillae, presence of rete ridges, and lack of granular layer (red arrow: keratin; black: epidermis layer; blue: Munro abscess; yellow: rete ridges. H&E (A & B) 10X & (C&D) 40X).

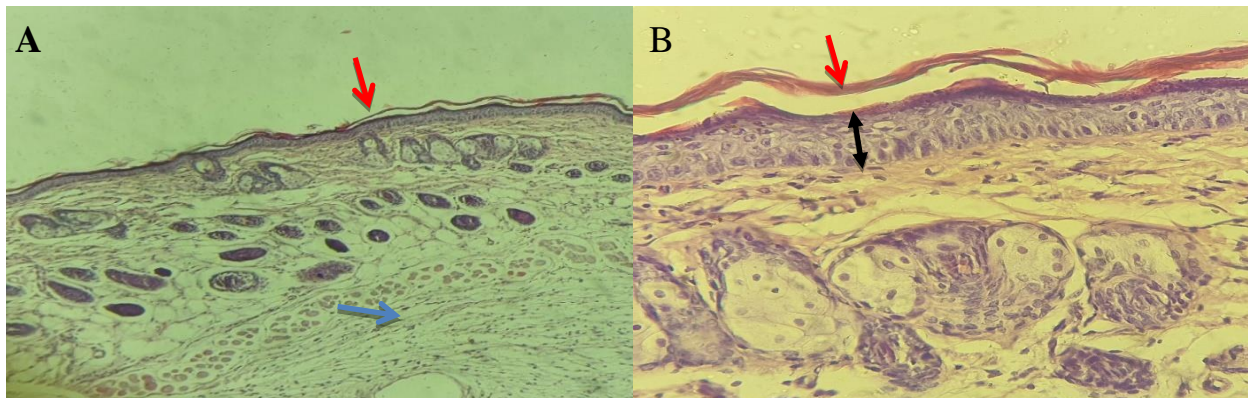


**Figure (6):** Skin section from mice back skin of clobetasol ointment (0.05%) group showing thinning of epidermis layers (black arrow: epidermis layer. H&E (A) 10X & (B) 40X).





**Figure (7):** Skin section from mice back skin of Montelukast gel (0.5%) group showing normal spread of keratin and epidermal thickness (red arrow: keratin; black: epidermal layer. H&E (A) 10X & (B) 40X).



**Figure (8):** Skin section from mice back skin of Montelukast gel (1%) group showing normal spread of keratin and epidermal thickness (red arrow: keratin; black: epidermal layer, blue: dermal layer. H&E (A) 10X & (B) 40X).

## Discussion

Imiquimod-induced psoriasiform skin inflammation in mice is closely similar to those of human being regarding erythema, scaling, and epidermal thickness within 6-days experimental period since it mediated via the IL-23/IL-17 axis psoriasis-like skin inflammation inducing acanthosis, parakeratosis, and inflammatory cells infiltration<sup>1</sup>. Clobetasol significantly reduced psoriatic scoring severity due to its proofed anti-inflammatory and anti-proliferative effects via suppression activation of immune cells and cytokines production. It possessed many antipsoriatic properties including promoted the transcription of anti-inflammatory genes over inflammatory genes, reduced epidermal mitotic rate, shorted survival of lymphocytes, lowered blood flow to inflamed site by vasoconstriction, and shifted of adaptive immune response from Th<sub>1</sub> to Th<sub>2</sub> pathway<sup>1</sup>. Topical application of montelukast significantly improved PASI when being compared with imiquimod induced psoriatic lesion. Several studies referred that montelukast reduced erythema, scaling, and induration of atopic dermatitis<sup>16,17</sup>. It also relieved pruritus, erythema and decreased number and size of weals associated with urticarial skin<sup>1</sup>.

In the present study, IMQ induced mouse psoriatic inflammation via activated Langerhans cells with TLR-7 and mediated activation of the central transcription factor nuclear factor- $\kappa$ B resulted in secretion of cytokines primarily TNF- $\alpha$ , activation of IL-23 producing Langerhans and thereby activation of IL-17 and IL-22 producing Th17 cells. The overexpression of cytokines like TNF- $\alpha$ , IL-17, and IL-23 in skin treated with Imiquimod responsible for desquamation, epidermal hyperproliferation, and infiltration of lymphocyte. These changes seemed to be compatible with other experimental studies<sup>19, 1</sup>. TNF- $\alpha$  is responsible for initiated inflammatory psoriatic mechanism and rise in production of pro-inflammatory cytokines (IL-6, IL-17, and vasoactive peptide) and adhesion molecules (Intercellular adhesion molecules-1 (ICAM-1), P-selectin, and E-selectin). High level of TNF- $\alpha$  was detected in hyperproliferation psoriatic lesion<sup>20</sup>. IL-17 is a pro-inflammatory cytokine that present as undetectable amount in normal skin and its level elevated in psoriatic lesion. It is responsible for expression of other inflammatory cytokines, colony

stimulating factors and chemokines from dendritic cells, neutrophil, macrophage, and epithelial cells<sup>21</sup>. IL-23 is an inflammatory cytokine that induced the expansion and maintenance of psoriatic lesion by activation Th17 cells and then enhanced keratinocyte proliferation<sup>22</sup>. In the present study, montelukast significantly reduced the levels of inflammatory cytokines (TNF- $\alpha$ , IL-17, and IL-23). Montelukast had anti-inflammatory agent by blocking leukotriene receptors acts as critical regulator of immune cell mobilization to sites of inflammation<sup>23, 24</sup>. The prospective roles of LTs in psoriatic inflammation have been investigated. LTB<sub>4</sub>–BLT1 signaling in neutrophils significantly accelerated neutrophil infiltration in the skin by cooperating with CXCR2, a chemokine receptor for CXCL1/2, and promoted the development of psoriatic dermatitis<sup>25</sup>. LTB<sub>4</sub> acted on skin dendritic cells and  $\gamma\delta$  T cells through BLT1 and facilitated their migration and/or cytokine production, which also contributed to the progression of psoriatic dermatitis<sup>26</sup>.

IMQ caused significant histopathological changes characterized by Munro abscess, hyperkeratosis, abnormal thickness of epidermis, thinning above papillae, presence of rete ridges, and lack of granular layer; such histopathological features in compatible with other studies<sup>27, 28, 29</sup>. Clobetasol had a restorative effect on histological feature of imiquimod-induced psoriatic lesion characterized by normal spread of keratin, very thin epidermal layer and presence of granular layer which mediated anti-inflammatory and immunosuppression effects. Clobetasol is considered as a standard topical therapy of psoriasis and frequently used as positive control group for investigation efficacy of other tested agent<sup>30, 31</sup>. Montelukast showed an effective therapeutic effect on IMQ-induced psoriatic lesion via improvement of histopathological features by retaining skin appearance similar to normal skin probably by mediating several activities including blockage of leukotriene receptors which are responsible for initiating and maintenance of inflammatory processes, inhibition of inflammatory mediators like substance P, had secondary anti-inflammatory properties unrelated to classical antagonism of leukotriene receptors targeting many immune cells like eosinophils, monocytes, and corticosteroid insensitive neutrophils proposing, and reducing the secretion of inflammatory cytokines like IL-6, IL-8, Matrix Metalloproteinase (MMP-3 and MMP-13)<sup>32, 33</sup>.

## Conclusion

The results of present study could be concluded that topically applied montelukast gel exhibited a potentially anti-psoriatic and anti-inflammatory activities via reduction of inflammatory cytokines and improvement of histopathological features of skin.

## References

1. **Al-Saedi, H. F. S.; Al-Zubaidy, A. A. K.; Ramadhan, M. A.; and Mohammad H. A. (2018)** "effect of metformin gel against imiquimod induced psoriasis in mice" *Int. J. Res. Pharm. Sci.*, **10**(2): 795-802.
2. **Sarac, G.; Koca, T. T.; and Balgan, T. (2016)** "A brief summary of clinical types of psoriasis" *North. Clin. Istanbul.*, **3**(1):79-82.
3. **Burden, A. D. and Kirby B. (2016)** " Psoriasis and related disorders." *Rook`s Textbook of Dermatology*, 9<sup>th</sup> edition:1-64.
4. **Wu, B. and Wan, Y. (2020)** "Molecular control of pathogenic Th17 cells in autoimmune diseases." *International immunopharmacology*, **80**:106187.

5. **Chuang, S.-Y.; Lin, C.-H.; Sung, T. C.; and Fang J.-Y. (2018).** "Murine models of psoriasis and their usefulness for drug discovery." *Expert opinion on drug discovery*, **13**(6): 551-562.
6. **Vestergaard, C. and Deleuran, M. (2015).** "Chronic spontaneous urticaria: latest developments in aetiology, diagnosis and therapy." *Therapeutic advances in chronic disease*, **6**(6): 304-313.
7. **Pharmacopeia, U. (2013).** National Formulary (USP 36-NF 31) Online. MD: United States Pharmacopeial Convention.
8. **Van der Fits, L.; Mourtis, S.; Voerman, J. S. A.; Kant, M.; Boon, L.; Laman, J. D.; Cornelissen, F.; Mus, A.-M.; florencia, E.; prens, E. P.; and Lubbert, E. (2009).** "Imiquimod-induced psoriasis-like skin inflammation in mice is mediated via the IL-23/IL-17 axis." *J.of Immunol.*, **182**(9): 5836-5845.
9. **Machekposhtia, S. A.; Soltani, M.; Raahemifarc, K.; Bidakid, E. Z.; and Sadeghie, M. (2017).** "PASI area and erythema scoring using YIQ color space." *Dermatol. Res. Skin. Care.* **1**(1): 8-14.
10. **Zhou, T.; Fin, M.; You, R.; Lu, Y.; Huang, L.; Xu, Y.; Feng, S.; Wu, Y.; Shen, H.; and Zhu, L (2020).** "Fabrication of Fe<sub>3</sub>O<sub>4</sub>/Au@ ATP@ Ag Nanorod sandwich structure for sensitive SERS quantitative detection of histamine." *Analytica chimica acta* **1104**: 199-206.
11. **Cummings, M.; king H.; Hurst, J.; Tanner, G.; Khazin, L.; Thompson, P.; Gray, A.; Gahir, N.; Cartidge, C.; Farooq, Z.; Raveendran, K.; Allen, K.; Rotimi, O.; and Orsi, N. M. (2020).** "Decreasing formalin concentration improves quality of DNA extracted from formalin-fixed paraffin-embedded tissue specimens without compromising tissue morphology or immunohistochemical staining." *J. clin. path.* **73**(8): 514-518.
12. **Luo, D.-Q.; Wu, H.-H.; and Zhao, Y.-K. (2016).** "Different imiquimod creams resulting in differential effects for imiquimod-induced psoriatic mouse models." *Experimental Biology and Medicine* **241**(16): 1733-1738.
13. **Indrayan, A. and Malhotra, R. K. (2017).** *Medical biostatistics*, Chapman and Hall/CRC.
14. **Blauvelt, A. and Chiricozzi, A. (2018).** "The immunologic role of IL-17 in psoriasis and psoriatic arthritis pathogenesis." *Clinic. Rev. Allerg. Immunol.*, **55**(3): 379-390.
15. **Segaert, S.; Shear, N. H.; Chiricozzi, A.; Thaci, D.; Carrascosa, J.-M.; Young, H.; and Descamps, V. (2017).** "Optimizing anti-inflammatory and immunomodulatory effects of corticosteroid and vitamin D analogue fixed-dose combination therapy." *Dermat. Ther.*, **7**(3): 265-279.
16. **Yanase, D. J. and K. David-Bajar (2001).** "The leukotriene antagonist montelukast as a therapeutic agent for atopic dermatitis." *J. Amer. Acad. Dermat.*, **44**(1): 89-93.
17. **Möhrenschlager, M.; Darsow, U.; Schnopp, C.; and Ring, J. (2006).** "Atopic eczema: what's new?" *J. Eur. Acad. Dermat. Vener.*, **20**(5): 503-513.
18. **De Silva, N. L., Damayanthi, H.; Rajapakse, A. C.; Rodrigo, C.; and Rajapakse, S. (2014).** "Leukotriene receptor antagonists for chronic urticaria: a systematic review." *All. Asth. Clin. Immun.*, **10**(1): 1-6.
19. **Lin, Y.-K.; Yang, S.-H.; Chen, C.-C.; Kao, H.-C.; and Fang, J.-Y. (2015).** "Using imiquimod-induced psoriasis-like skin as a model to measure the skin penetration of anti-psoriatic drugs." *PLoS One* **10**(9): e0137890.
20. **Harrison, M. J.; Dixon, W. G.; Waston, K. D.; King, Y.; Groves, R.; Hyrich, K. L.; Symmos, D. P. M. (2009).** "Rates of new-onset psoriasis in patients with rheumatoid arthritis receiving anti-tumour

- necrosis factor  $\alpha$  therapy: results from the British Society for Rheumatology Biologics Register." *Annals of the rheumatic diseases*, **68**(2): 209-215.
21. **Raychaudhuri, S. P. (2013)**. "Role of IL-17 in psoriasis and psoriatic arthritis." *Clinic. Rev. Allerg. Immunol.*, **44**(2): 183-193.
  22. **Boutet, M.-A.; Nerviani, A.; Afflitto, G. G.; and Pitzalis C. (2018)**. "Role of the IL-23/IL-17 axis in psoriasis and psoriatic arthritis: the clinical importance of its divergence in skin and joints." *Int. J. Mol. Sci.* **19**(2): 530.
  23. **Liu, M. and Yokomizo, T. (2015)**. "The role of leukotriene in allergic disease." *Allergy International.*, **64**(1): 17 – 26.
  24. **Peters-Colden, M. and Scott, J. P. (2013)**. "Antilukoteriene agents for the treatment of lung disease." *Amer. J. Resp. Crit. Car. Med.*, **188**(5): 538-544.
  25. **Sumida, H.; Yanagida, K.; Kita, Y.; Abe, J.; Matsushima, K.; Nakamura, M.; Ishii, S.; Sato, S.; and Shimizu, T. (2014)**. "Interplay between CXCR2 and BLT1 facilitates neutrophil infiltration and resultant keratinocyte activation in a murine model of imiquimod-induced psoriasis." *J. Immunol.* **192**(9): 4361-4369.
  26. **Honda, T. and Kabashima, K. (2019)**. "Prostanoids and leukotrienes in the pathophysiology of atopic dermatitis and psoriasis." *Int. Immunol.* **31**(9): 589-595.
  27. **Hawkes, J. E.; Gudjonsson, J. E.; and Ward, N. L. (2017)**. "The snowballing literature on imiquimod-induced skin inflammation in mice: a critical appraisal." *J. Invest. Dermat.* **137**(3): 546-549.
  28. **Rather, I. A.; Bajpai, V. K.; Huh, Y. S.; Han, Y.-K.; Bhat, E. A.; Lim, J. Paek, W. P.; and Park Y.-H. (2018)**. "Probiotic *Lactobacillus sakei* proBio-65 extract ameliorates the severity of imiquimod induced psoriasis-like skin inflammation in a mouse model." *Front. Microbiol.* **9**: 1021.
  29. **Liu, C., Liu, H.; Lu, C.; Deng, J.; Yan, Y.; Chen, H.; Wang, Y.; Liang, C.-L.; Wei, J.; Han, L.; and Dia, Z. (2019)**. "Kaempferol attenuates imiquimod-induced psoriatic skin inflammation in a mouse model." *Clin. Experiment. Immunol.* **198**(3): 403-415.
  30. **Sun, J., Zhao, Y.; and Hu, J. (2013)**. "Curcumin inhibits imiquimod-induced psoriasis-like inflammation by inhibiting IL-1 $\beta$  and IL-6 production in mice." *PLoS One* **8**(6): e67078.
  31. **Domala, A.; Bale, S.; and Godugu, C. (2020)**. "Protective effects of nanoceria in imiquimod induced psoriasis by inhibiting the inflammatory responses." *Nanomedicine* **15**(1): 5-22.
  32. **Mahmudpour, M.; Rouzbeh, J.; Jalali, A. R.; Pakfetrat; M.; Zadegan, S. E.; and Sagheb, M. M. (2017)**. "Therapeutic effect of montelukast for treatment of uremic pruritus in hemodialysis patients." *I. J. K. D.* **11**(1): 50.
  33. **Dong, H., Lu, F.; Ma, F.; Xu, L.; Pang, L.; Li, X.; Liu, B.; and Wang, L. (2018)**. "Montelukast inhibits inflammatory response in rheumatoid arthritis fibroblast-like synoviocytes." *Inter. Immunopharm.* **61**: 215-221.