

## Management of Supernumerary tooth in maxillary third molar region

Dr. Vijay ebenezer<sup>(1)</sup>, Dr.S.Ishwarya<sup>(2)</sup>

1 Professor & Hod, Dept of oral and maxillofacial surgery, Sree Balaji dental college and hospital, BHARATH UNIVERSITY, Chennai-600100, Tamil nadu, India

2 Post graduate, Dept of oral and maxillofacial surgery, Sree Balaji dental college and hospital, BHARATH UNIVERSITY, Chennai -600100, Tamil nadu, India

Email: [ishwaryadentist@yahoo.com](mailto:ishwaryadentist@yahoo.com)

---

### ABSTRACT:

Supernumerary teeth are the teeth which are more in addition to the normal number found in either primary or permanent dentition. Paramolar is a supernumerary structure occurring buccally orlingually near the molars and it may be caused by combination of genetic and environmental factors. Inverted teeth have been reported in both maxilla and mandible and mostly they are inverted and impacted third molars and premolars. Reports of this unique entity are rarely found in the literature.

**KEYWORDS:** Paramolar, Maxilla, Extra tooth, Inverted tooth, Supernumerary tooth, Third molar, Fused tooth

### INTRODUCTION:

An impacted tooth is one that is erupted, partially erupted, or unerupted and will not eventually assume a normal arch relationship with the other teeth and tissues. Tooth impaction is a frequent phenomenon but inversion of the impacted tooth is rare. Inverted tooth is the one where the crown is pointing downwards and the root apex pointing toward the alveolar crest. Supernumerary teeth are defined as those that grow in addition to the normal series of deciduous or permanent dentition<sup>2</sup>. They may occur anywhere in the mouth. Teeth which exceed the normal 32 number of permanent teeth in the oral cavity are called supernumerary teeth. These teeth have a striking predilection for maxilla over the mandible and they are more frequently found in males compared to females in a ratio of 2:1.

Supernumerary teeth may occur singly, bilaterally or even in multiples. The prevalence of these teeth has been recorded to be greater in the permanent dentition (1.5-3.5%) as compared to primary dentition (0.2-0.8%). Supernumerary teeth are situated especially in the premaxillary region (90%), with 93% of them in central incisor region, with 25% of those located in the midline. Of the remaining 10%, about 4% and 1.5% are located in the mandibular premolar and maxillary canine regions, respectively<sup>1</sup>. They can be erupted or unerupted and remain in the bone. Unerupted and impacted supernumerary teeth are discovered during routine radiographic examinations. Sometimes supernumerary teeth are found to be associated with some systemic diseases or syndromes like Gardner's syndrome, cleidocranial dysplasia and in patients with cleft lip and palate.

### CLASSIFICATION OF SUPERNUMERARY :

In general, supernumerary teeth may be classified according to their location and form i.e. size and shape.

According to the location, supernumerary teeth are classified into mesiodens, paramolar and distomolar.

- Mesiodens is a typical conical supernumerary tooth, situated between the maxillary central incisors<sup>3</sup>
- Paramolar is a supernumerary molar usually small and rudimentary, situated buccally or palatally to one of the maxillary molars or in the interproximal space buccal to the second and third molars.
- Distomolar is a supernumerary tooth which is located distal to the third molar.

According to form, supernumerary teeth are categorized into conical, supplemental, tuberculate and odontomas.

- Conical supernumeraries are small peg shaped (coniform) tooth with normal roots.
- Supplemental supernumeraries resemble adjacent non affected teeth
- Odontomas are supernumerary teeth having no regular shape.
- Tuberculate is multicusped, and short barrel shaped teeth with apparently normal or invaginated crown but with a rudimentary root .

Based on shape, they are classified as ,

- Supplemental (or eumorphic) referring to supernumerary teeth of normal size and shape.

Rudimentary (or dysmorphic), teeth of abnormal shape and smaller size, including conical, tuberculate and molariform types.

#### **COMPLICATIONS:**

As such, supernumerary teeth do not cause any complication. However, these may lead to delay or failure of eruption of permanent teeth, displacement, crowding, root resorption, dilaceration, loss of vitality of adjacent teeth, subacute pericoronitis, gingival inflammation, periodontal abscesses, dental caries due to plaque retention in inaccessible areas, incomplete space closure during orthodontic treatment, and pathological problems such as dentigerous cyst formation, ameloblastomas, odontomas and fistulae<sup>4</sup>. They may also interfere in alveolar bone grafting and implant placement.

#### **DIAGNOSIS:**

Occasionally, supernumerary teeth are asymptomatic and may be detected as a chance finding during radiographic examination. Detailed history, clinical examination, thorough investigation, early diagnosis and appropriate treatment of supernumerary teeth are mandatory. Unerupted supernumerary may be found by chance during radiographic examination<sup>7</sup>. Sometimes, clinicians may suspect the presence of supernumerary teeth, if there is failure of eruption or ectopic eruption of permanent tooth, persistence of deciduous tooth, wide diastema and obvious presence of additional teeth. An anterior occlusal or periapical radiograph and using paralleling technique and panoramic view (OrthoPantomoGraph) are the most useful radiographic investigations to visualize supernumerary teeth. Recently, computed tomography has also been used to detect the presence of supernumerary teeth<sup>8</sup>. A complete radiographic survey of the entire oral cavity is essential to identify the presence of all impacted supernumerary teeth because the ratio of impacted to erupted supernumerary teeth ranges from 3 to 1. However, radiographs alone are not adequate for the definitive diagnosis. Their interpretation should always be conducted in conjunction with clinical findings.

#### **MANAGEMENT :**

Treatment depends on the type and location of the supernumerary teeth and on its potential effect on adjacent hard and soft tissue structures<sup>5</sup>. Occasionally, supernumerary teeth may lead to complications such as deep caries in the adjacent teeth, which may require restoration or endodontic therapy of the adjacent teeth. Supernumerary teeth can be managed either by removal/endodontic therapy or by maintaining them in the arch and frequent observation. Removal of the supernumerary teeth is recommended where

- there is associated pathology,
- permanent tooth eruption has been delayed due to the presence of supernumerary tooth,
- increased risk of caries due to the presence of supernumerary teeth which makes the area inaccessible to maintain oral hygiene,
- altered eruption or displacement of adjacent tooth is evident,
- there are severely rotated teeth leading to further complication,
- orthodontic treatment needs to be carried out to align the teeth,
- its presence would compromise alveolar bone grafting and implant placement and
- there is compromised esthetic and functional status.

Extraction should be performed carefully to prevent damage to adjacent permanent teeth, which may cause ankylosis and maleruption of these teeth. The clinician should be careful to avoid complications such as damaging nerve and blood vessels during manipulation of the tooth, perforation of maxillary sinus, pterygomaxillary space, orbit and fracture of maxillary tuberosity<sup>6</sup>. Clinicians must also be alert as sometimes supernumerary teeth are fused with the adjacent tooth structure at crown or root level, which may make the extraction difficult. Supernumerary teeth can also be kept under observation without extraction when satisfactory eruption of related teeth has occurred with no associated pathology and not causing any functional and esthetic interference.

#### **A case of inversely fused tooth of impacted maxillary third molar and supernumerary tooth**

##### **CASE REPORT :**

A 51-year-old male patient visited oral and maxillofacial surgery of Sree Balaji Dental college & Hospital complaining of slight pain in the right maxillary molar region. Clinical examination revealed slight percussion pain on maxillary tuberosity, but with no sign of infection such as swelling and redness of the gingival mucosa, fistula formation, and pus discharge in the right maxilla. The right maxillary third molar was not erupted. First, we take a panoramic X-ray for overview, and dental X-ray for detail. The panoramic and dental radiographs showed a radiopaque mass (20x15 mm) located in the third maxillary molar region of the right maxilla. To detect its shape and location, we took computed tomography (CT). Computed tomography scan revealed a tooth-like mass composed of an enamel-like and a dentin-like region, and dental pulp-like cavities near arteria palatina major. Furthermore, the mass consisted of two tooth-like structures that shared a dental pulp cavity. The lesion was partially projecting into the right maxillary sinus. The clinical diagnosis of the lesion was odontoma or fused tooth and slight pericoronitis may cause slight pain. As he had slight pain, removal of the mass through the canine fossa of maxilla was

planned. From the point of view of operation time and procedure, this operation was performed under general anesthesia. The mass was divided into two pieces at removal, because the size of the mass was larger than that of the canine fossa aperture.

#### **DISCUSSION:**

Dental malformation might be classified as gemination, twinning, concrescence, and fusion. A fused tooth is defined as one in which there is union of dentin from two separate tooth germs during development. On the other hand, occurrence of two teeth with cementum union indicates concrescence. In this case, the mass consisted of two tooth-like structures that shared one dental pulp cavity, as revealed by CT scan. This mass was found to result from an inversely fusion of the third molar with a supernumerary tooth because the mass was located at the site of the third maxillary molar region and since the number of erupted teeth was normal. However, it was unclear whether these included a case of inversely fused tooth. Nakanishi reported that the prevalence of supernumerary tooth is almost 1% in all regions of the dentition, and only 0.063% in the upper molar region. This suggests that the frequency of fusion of the maxillary third molar and supernumerary tooth may be even lower. These facts, considered together, indicate the extreme rarity of this case. Sugibayashi proposed that the causes of supernumerary teeth might be heredity, physical forces, and/or trauma in the tooth germ. Some cases of between maxillary third molar and supernumerary tooth

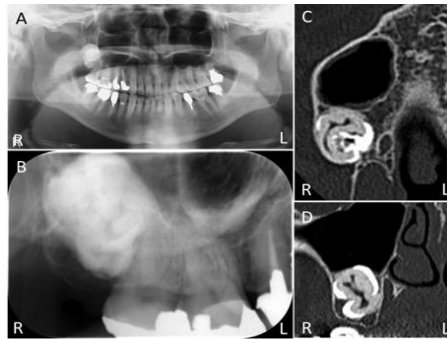


Figure 1: Radiography and computed tomography (A) Panoramic, (B) Dental radiography showing a radiopaque mass is located in the right maxilla, (C) Transverse plane of computed tomography images. The radiopaque mass is located in the right maxillary sinus. Some cavities can be seen in the mass, and (D) Coronal plane of CT images reveals that the radiopaque mass has pulp-like cavity

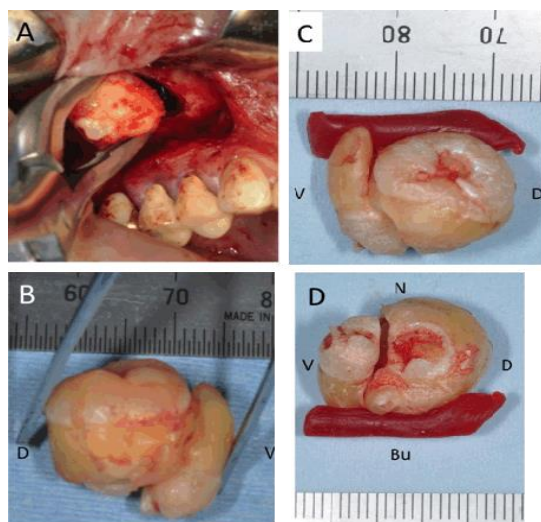


Figure 2: Operation procedure (A) and extracted material (fixed with dental utility wax) (B) Buccal side, (C) Nasal side, (D) Caudal side Bu: buccal side, N: nasal side, V: ventral side, D: dorsal side. The mass was 18x12x10 mm with enamel-like region and dentin-like region.

About the treatment, most of the cases were extracted with local anesthesia. These kinds of cases were found after eruption. In this case, fused teeth were fully impacted, and located near arteria palatina major and pterygoid plexus. As we have to remove more carefully, operation under local anesthesia is intolerable.

#### CONCLUSION :

We reported a rare case of inversely fusion of impacted maxillary third molar and supernumerary tooth. The reason may be hereditary, racial, or environmental factors and so on. To remove the fused teeth, we have to take better procedure of removal and anesthesia. Supernumerary teeth can present in any region of oral cavity. These may erupt or remain impacted and may lead to various complications. Though the occurrence of Paramolar is rare, clinicians should be aware of their presence and associated problems in order to formulate a sound treatment plan after thorough clinical and radiographic investigations, to meet the challenges.

Ethical clearance – Not required since it is a case report

Source of funding – nil

Conflict of interest – nil

#### REFERENCE :

1. Hou GL, Tsai CC. Fusion of maxillary third and supernumerary fourth molars. Aust Dent J 1989 Jun;34(3):219–22.
2. Levitas TC. Germination Fusion Twinning and Concrescence. ASDC J Dent Child 1965;32:93–100.
3. Morris DO. Fusion of mandibular third and supernumerary fourth molars. Dent Update 1992 May;19(4):177–8.
4. Conte M, Lombardi P, Linfant J. A supernumerary tooth fused to the distal surface of a mandibular third molar. J N J Dent Assoc 2002 WinterSpring;73(1–2):8–9.

5. Goho CD Jr. Mandibular third molar and supernumerary molar fusion. *Va Dent J* 1988 OctDec;65(4):26–7.
6. Ozcan G, Sekerci AE, Soylu E, Nazlim S, Amuk M, Avci F. Role of cone-beam computed tomography in the evaluation of a paradental cyst related to the fusion of a wisdom tooth with a paramolar: A rare case report. *Imaging Sci Dent* 2016 Mar;46(1):57–62.
7. Abrams RA, Nelson DL. Fusion of a third molar to a supernumerary tooth with an associated dentigerous cyst. *Aust Dent J* 1979 Jun;24(3):141–2.
8. Uchida K, Kuroiwa H, Uchiyama M, et al. A case of fusion of the supernumerary teeth in the right maxilla and the third molar. *Matsumoto Shigaku* 2010;36:134–8.