

Evaluation Of Anti-Diabetic And Wound Healing Potential Of Ethiopia Plant 'Ruta Graveolens' In Diabetic Induced Rat

C Velmurugan ^{*1}, Vetriselvan Subramaniyan², S Ilanthalir¹, Shivakanya Fuloria³, Mahendran Sekar⁴, Neeraj Kumar Fuloria³, Mohammad Nazmul hasan maziz²

- 1- Department of Pharmacology, PGP college of Pharmaceutical Science and Research Institute, Namakkal, Tamil Nadu-637207.
- 2- Faculty of Medicine, Bioscience and Nursing, MAHSA University, Kuala Lumpur, Malaysia-42610.
- 3- Faculty of Pharmacy, AIMST University, Kedah 08100, Malaysia.
- 4- Faculty of Pharmacy and Health sciences, University Kuala Lumpur Royal College of medicine, Ipoh, Perak, Malaysia-30450.

ABSTRACT

Ruta graveolens L. (Rutaceae), locally known as "tena adame", originally native to the Mediterranean region and is widely distributed in various geographical regions of Ethiopia. It is ornamental and medicinal plant used traditionally. The present study was carried out for the phytochemical analysis and to evaluate the anti-diabetic and diabetic induced wound healing activity of acetone, aqueous and chloroform leaf extract of Ruta graveolens (RG). Preliminary screening of the extracts result shows the presence of various phyto-chemical compounds. Wistar albino rats (200-250gm) were used as experimental animals and were divided into six groups. Group I, as the control group, received simple ointment (Vaseline) and 4mg/kg /sc dexamethasone, Group II tetracycline hydrochloride ointment plus 4mg/kg /sc Dexamethasone (Dexa). Group III, IV, V&VI received Glibenclamide (GLB)5mg/kg, 20% ointment of acetone extract (AE), aqueous extract (AQE) and chloroform extract (CE) along with 4mg/kg/sc dexamethasone respectively. Phyto chemical screening, wound contraction and blood glucose level was monitored on Days 0, 2, 4, 6, 8, and 10. Result showed, the chloroform extract in treated animals showed a significant result in decrease glucose in blood, period of epithelization and wound contraction in diabetic rats. Study concluded that chloroform extract comparatively shows good diabetic and wound healing property.

Key words: Ruta gravelons, Phytochemical, acetone, wound healing, Dexamethasone

INTRODUCTION

Herbal medicines derived from plant extracts are being increasingly utilized to treat a wide variety of diseases, though relatively little knowledge about their mode of action is available (1,2) Rutagraveolens

L. (Rutaceae), locally known as tena adame, is widely distributed in various geographical regions of Ethiopia and some parts of other Afro Asian countries (3) as a cultivated plant such as ornamental plant (4,5) and is an ancient medicinal plant and currently used for treatment of multiple disorders, including eye problems, aching pain, dermatitis and rheumatism (6). In addition, *R. graveolens* has been extensively used in treatment of vitiligo, psoriasis, leucoderma, multiple sclerosis, cutaneous lymphomas, and recently reported to possess anticancer, anti-inflammatory, hepatoprotective and antidiabetic activity (7-10). It has also been used for gastric disorders, stiff neck, dizziness and headache (11).

The chemical composition is large and varied. Phytochemical investigations have demonstrated the presence of more than 100 chemical compounds have been found in all parts of the plant, including fats, oils, flavonoids, furoquinolone, alkaloids, Glycosides, essential oils, Terpenoids, Steroids, Sterols, coumarins, Tannins, Phenols, Saponin, pyranocoumarin, Cardiac glycosides, Carbohydrates, Amino Acids, Protein and others. All parts of the plant contain the active principles, although they are mostly encountered in leaves (12-15).

The protective effects of *R. graveolens* rutin against diabetic induced wound are not reported. Therefore, the present study is conducted to demonstrate the efficacy of acetone, aqueous and chloroform extract of *Rutagravelon* in diabetic induced wound in Wistar rats.

MATERIALS AND METHODS

Collection of plant material

Ruta Graveolens was collected in February/ March 2018 from the shell market 20 km away from Arbaminch. The species Authenticated and identify by Department of Botany.

Preparation of extract by maceration process (16)

Fresh aerial parts of *Ruta graveolens* were dried in shade then crushed first by hand then by mechanical grinder to give finely grounded powder. Then (500 g) powder of the plant materials were macerated with 1:2 ratio of solvents aqueous, acetone and chloroform for 72 hours frequent shaking of every 30 min up to 6 hours on each day. Then extracts were filtered by Whatman No. 1 filter paper, the solvent in each extract after filtration was evaporated by water bath and gave black for chloroform and acetone, reddish brown residue for aqueous. The resulting semisolid mass was vacuum dried and percentage yield was calculated.

Table 1: Data showing the % yield of dried leaf powder of *Ruta graveolens*

Plant	Part used	Method of extraction	Solvent	Colour of extract	Nature of extract	% yield of Extract in gm
<i>R. graveolens</i>	Leaves	Maceration	Chloroform	Black	Semisolid	20
			Acetone	Black	Semisolid	6
			Aqueous	Reddish brown	Semisolid	8

Solubility of *Ruta graveolon*

Table 2: Solubility of various extracts of *R. graveolon* in various solvents

Extracts	Water	DMSO
AERG	Very slightly soluble	Soluble
AqERG	Soluble	Soluble
CERG	Very slightly soluble	Soluble

Phytochemical analysis for bioactive substances (16)

The residue was dissolved by dimethylsulfoxide (DMSO) and was stored at 25°C used for further investigation for phytochemical studies for the presence of various phytoconstituents like alkaloids, flavonoids, saponins, tannin, and glycosides.

Test for Flavonoids:

Lead acetate test- 5ml of crude extract was mixed with 1-3 drop of 5% lead acetate solution, white precipitate appeared indicate the presence of flavonoids

Test for alkaloids:

5ml of 2% HCl was added to 2ml of each plant extract in a test tube placed on water bath for 5 min and warmed. 2 ml of the filtrate were treated with wagner reagent, red precipitate appeared indicate the presence of alkaloid.

Test for tannin:

5ml of extract was treated with 2ml of HCl and placed in water bath for 5 min. The presence of red precipitate confirmed the presence of tannins.

Test for Cardiac Glycosides:

To 2 ml alcoholic filtrate plant materials, 1 ml glacial acetic acid and 1-2 drops of FeCl₃ to add and 1 ml of concentrated H₂SO₄ followed. Appearance of a violet ring below the brown ring confirms positive reaction for cardiac glycosides.

Detection of Phenols:

5 ml of the crude extracts were mixed with 1-3 drops of ferric chloride solution. Creation of bluish black color indicates the presence of phenols.

Detection of saponin:

Foam test: 10 ml of crude extract was shaken with a small amount of water. If foam produced persists for ten minutes it indicates the presence of saponin.

Test for Resins:

One ml of various solvent extract was treated with few drops of acetic anhydride solution followed by one ml of conc. H₂SO₄. Resins give coloration ranging from orange to yellow

Test for steroids:

0.5 g of the various solvent extract fraction of each plant was mixed with 2 ml of acetic anhydride followed by 2 ml of sulphuric acid. The colour changed from violet to blue or green in some samples indicated the presence of steroids.

Test for Carbohydrates

Benedict's test: To 0.5 ml of solvent extract 0.5 ml of Benedict's reagent is added. The mixture is heated on a boiling water bath for 2 minutes. A characteristic green to dark red or rusty brown indicates the presence of sugar.

Test for Proteins

Biuret test: 2 ml of solvent extract is treated with 1 drop of 2% copper sulphate solution. To this 1 ml of ethanol (95%) is added, followed by excess of potassium hydroxide pellets. Pink colour ethanolic layer indicates the presence of protein.

Acute toxicity

The acute toxicity study was carried out with fractions of RG as per OECD 423 Guidelines. Wistar albino mice with weight ranging (25-30g) were taken for the experiment. The animals were made into a group of 3 each, dose of chloroform, acetone and aqueous extracts were given according to the body weight (mg/kg), starting dose of 5 mg /kg was given to the first individual animal, no death was occurred and higher doses were given to next group of animals up to 2000mg/kg. The animals were observed for a further 14 days for any signs for delayed toxicity.

Dexamethasone induced diabetic model (17)

In the experiment a total of 36 overnight fasted rats were used. The 24 rats were rendered diabetic by Dexamethasone (10mg/kg, s.c) once daily. The animals divided into six groups of six rats each. Group I normal control received 1% v/v tween 80, Group II served as Diabetic control, Group III served as standard treated with 5 mg/kg of Glibenclamide, Group IV, V & VI treated orally with 200 mg/kg of acetone, aqueous and chloroform extracts of Ruta gravelon (RG).

Formulation of crude extracts

The concentrations of the Aqueous, Acetone, and Chloroform extracts of leaves of Ruta gravelon (RG) ointment was formulated using simple ointment as the vehicle. For 20 % (w/w) extracts ointment, 1 g of the dry AERG, AQERG, and CERG was incorporated in 5 g of simple ointment using a ceramic mortar and pestle.

Effect of Ruta gravelons extracts in dexamethasone induced delayed wound healing activity in rats

Experimental animals

All the experiments were carried out using Wister rats (150-180 g). The animals were placed at random and allocated to treatment groups in polypropylene cages with sawdust husk as bedding.

Animals were housed at a temperature of $24 \pm 2^{\circ}\text{C}$ and relative humidity of 30–70%. A 12 hrs day: 12 hrs night cycle was followed. All animals were allowed free access to water and fed.

Experimental study design

In the experiment a total of 30 overnight fasted rats were used. The rats were rendered diabetic by Dexamethasone (4 mg/kg, s.c). The animals divided into five groups of six rats each.

- Group I : Received Vaseline + Dexamethasone 4mg/kg/s.c;
Group II : Applied Tetracycline hydrochloride (TC) ointment (3 %) + Dexamethasone 4mg/kg/s.c. (Dexa)
Group III : Received Glibenclamide 5 mg/kg (oral) + Dexamethasone 4mg/kg/s.c.
Group IV : Topically Applied 20 % AERG + Dexamethasone 4mg/kg/s.c.
Group V : Topically Applied 20 % AQERG + Dexamethasone 4mg/kg/s.c.
Group VI : Topically Applied 20 % CERG +Dexamethasone 4mg/kg/s.c;

Dosing schedule

Extracts of RG are applied topically daily from day 0th to 10th post-operative day. Dexamethasone was given subcutaneously on alternative days (from day 0th to 10th postoperative day)

Excision wound model (18, 19)

An excision wound model was used for studying wound healing activity in male albino rats as described by Nagappa et al. (2001), with some modification. Animals were anesthetized prior to and during creation of the wounds with chloroform. Hair was removed by shaving the nape of the back of all the rats. Ethanol (70%) was used as antiseptic for the shaved region before making the wound. A full thickness of the excision wound of uniform 5 cm^2 circular area was created along the markings using toothed forceps, scalpel and pointed scissors. The wound was left undressed to the open environment and no local or systemic anti-microbial agents were used. The rats were distributed in groups randomly and each rat was placed in an individual cage. The wistar albino rats were divided into five groups and the test samples (R.gravelons extracts) were formulated as an ointment in simple ointment base. The formulated ointment was applied on the wound once daily for 10 days starting from the day of wounding.

The wound area of each animal was measured on days 0, 2, 4, 6, 8 and 10 post-surgery. The wound size measurements taken at the time of day zero and at the time of different intervals were used to calculate the percent wound contraction, using equation:

$$[(W_0 - W_t)/W_0] \times 100 = \% \text{ of wound closure}$$

Where W_0 is the original wound area and W_t is the area of wound on day of 2, 4, 6, 8 & 10

STATISTICAL ANALYSIS

One-way analysis of variance (ANOVA) followed by Dunnett's method of multiple comparisons was employed using Graph pad InStat 5.0 software. $p < 0.05$, $p < 0.01$ & $p < 0.001$ was considered to be statistically significant.

RESULTS & DISCUSSION

The preliminary phytochemical analysis of Acetone, Aqueous and Chloroform and extracts of *Ruta graveolens* revealed the presence of Phenols, Cardiac Glycosides, Flavonoids, Saponins, Tannins, Steroids, Protein, Carbohydrate, and Resin. The chloroform extracts showed alkaloid, phenol, cardiac glycoside, flavonoid, saponins, carbohydrate, protein and resin. In case of aqueous extracts showed alkaloid, phenol, Flavonoids, Saponins, Tannins, Steroids, Protein, etc.

Table 3: Preliminary phytochemical screening of different extract of *Ruta graveolens*

Chemicals Present	CERG	AQERG	AERG
Phenols	+	+	+
Alkaloid	+	+	+
Cardiac Glycosides	+	+	+
Flavonoids	+++	+	+
Saponins	+	+	+
Tannins	++	+	-
Steroids	-	-	+
Protein Biuret test	+	+	+
Carbohydrate Benedict reagent	+	+	-
Resin	+	+	-

+ = Present, - = Absent

Acute Oral Toxicity Study

Table 4: Acute oral toxicity study of various extracts of *Ruta Graveolens* in mice.

S.NO	Extracts	LD ₅₀ mg/kg	ED ₅₀ mg/kg
1	CERG	2000	200
2	AERG	2000	200
3	AQERG	2000	200

There was no mortality observed up to 2000mg/kg and study was carried out with 1/10th of LD₅₀ of extracts as 200 mg/kg.

Effect of leaves of *Ruta graveolon* extracts on blood glucose level

The chloroform extracts treated groups revealed significant decrease in blood glucose level from 2nd day to 10th day. Thus, the chloroform extract were found to be more significance in lowering blood glucose level compare to diabetic control. Acetone and aqueous extract was shows $p < 0.05$. There was no significant variation between chloroform and normal control on 10th day. The standard drugs maintained the sugar level almost equal to 0th day and on 10th day.

Table 5: Effect of blood glucose level of *Ruta Graveolens* extracts in rats

Groups	Treatment	Blood glucose level in mg/dl					
		0th day	2nd day	4th day	6th day	8th day	10 th Day
I	1% tween 80	112±5.83	92±3.32	102±1.28	119±3.39	95±4.79	114±2.5 ^a
II	Dexa 4mg/kg. S.c	04±31.83	26±20.32	142±17.28	159±14.39	176±9.79	195±7.5 ^c
III	GLB 5mg/kg	107±23.1	111±17.50	120±12.35	124±11.3	113±9.91	98±5.3 ^a
IV	AERG 200mg/kg	109±6.01	129.5±3.32	140±9.02	158.5±3.88	163.1±13.39	169.6±8.3 ^b
V	AQERG 200mg/kg	121±3.86	145±6.17	111.7±12.50	151.4±5.87	162±4.48	173±3.32 ^b
VI	CERG 200mg/kg	102±10.36	138.5±8.5	125.37±9.01	121.93±9.77	119.5±6.78	100±4.54 ^a

Values are expressed as mean ± SEM of three replicates. Mean bearing same superscripted do not differ significantly. Mean bearing different superscripted differ significantly. The different superscripted 'a' values have significantly differ ($p < 0.01$) from 'c'. 'b' indicates significantly differ ($p < 0.05$) from 'a'. 'b' values have significantly differ ($p < 0.05$) from 'c'.

Excision wound model

The mean wound contraction in the control group was 33 % on 10th day. The measurements of the progress of the wound contraction induced by the simple ointment (control), acetone extract, aqueous extract in simple ointment, the tetracycline hydrochloride ointment are shown in figure. It is observed that the wound contracting ability of the effect of chloroform extract in simple ointment is significantly ($P < 0.05$) greater than that of the aqueous, acetone extract in simple ointment and effect was equal to

standard tetracycline ointment. Chloroform P<0.001 significantly differ from control group. But acetone and aqueous extracts (P<0.05) shows significant effect when compared to control group

Table 6: Effect of topically applied Ruta Gravelon leaves extracts on excision wound model in rats

Groups	Wound contraction (cm ³)					
	0 day	2 nd day	4 th day	6 th day	8 th day	10 th day
1% tween 80 + Dexta 4mg/kg. S.c	5.0±0	4.6±0.7	4.1±7.1	3.8±3.3	3.61±0.9	3.34±1.3 ^a
3% TC+Dexta 4mg/kg. S.c	5.0±0	4.1±0.7	2.6±0.6	2.5±0.4	2.3±0.2	2.0±0.9 ^{**b}
GLB 5mg/kg	5.0±0	4.7±0.2	4.3±0.3	3.4±0.3	2.7±0.1	2.5 ±0.7 ^{**b}
AERG 20%	5.0±0	4.4±0.1	4.2±0.1	2.8±0.9	2.5±0.6	2.0±0.2 ^{**c}
AQERG 20%	5.0±0	4.5±0.3	4.1±0.2	3.1±0.1	2.9±0.8	2.3±0.8 ^{**c}
CERG 20%	5.0±0	4.1±0.5	2.5±0.2	2.1±0.1	1.4±0.8	1.3±0.3 ^{***d}

Values are expressed as mean ± SEM of three replicates. Mean bearing same superscripted do not differ significantly. Mean bearing different superscripted differ significantly. The different superscripted 'a' values have significantly differ (p<0.001) from d'. 'd' indicates significantly differ (p<0.05) from 'b&c'. 'c&b' values have significantly differ (p<0.05) from 'a'.

Table 7: Effect of topically applied Ruta Gravelon leaves extracts on excision wound model in rats

Groups	Percentage of Wound Contraction					
	0 day	2 nd day	4 th day	6 th day	8 th day	10 th day
1% v/v tween 80 + Dexta 4mg/kg. S.c	0	8.38±0.2	18.10±1.1	24.62±1.6	28.42±0.4	33.20±12.4 ^a
3% TC+Dexta 4mg/kg. S.c	0	8.26±0.2	48.38±1.2	50.20±1.8	54.30±0.2	60.32±1.2 ^c
Glibenclamide 5mg/kg	0	6.94±0.4	14.30±0.6	32.41±1.5	46.10±0.6	50.12±1.6 ^b
AERG 20%	0	12.45±0.9	16.80±0.5	44.80±1.4	50.26±0.1	60.14±1.3 ^c
AQERG 20%	0	10.32±1.0	18.21±1.4	38.22±1.2	42.50±0.2	54.18±1.2 ^c
CERG 20%	0	18.72±1.0	50.85±0.9	58.12±1.9	72.45±0.5	74.05±1.2 ^d

Values are expressed as mean ± SEM of three replicates. Mean bearing same superscripted do not differ significantly. Mean bearing different superscripted differ significantly. The different superscripted 'a' values have significantly differ (p<0.001) from d'. 'd' indicates significantly

differ ($p < 0.05$) from 'b&c'. 'c&b' values have significantly differ ($p < 0.05$) from 'a'.

Effect of topically applied Ruta Gravelon leaves extracts on excision wound model in rats

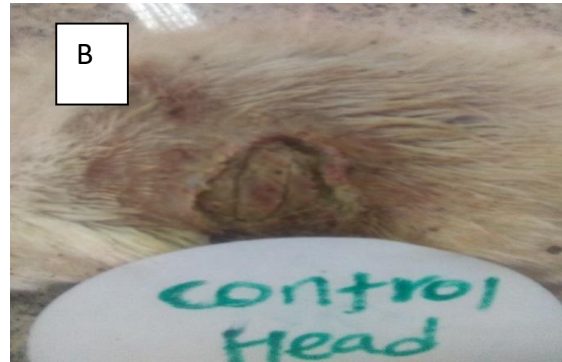
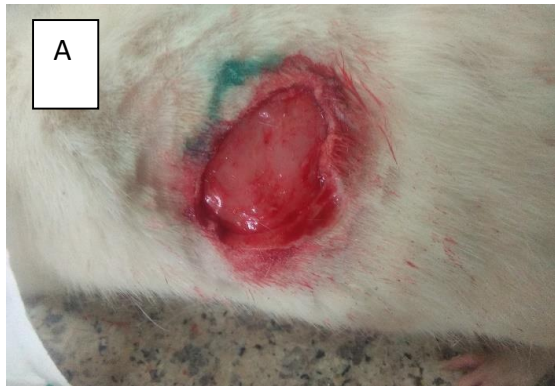
Figure 1: Effect of control group simple ointment base on excision wound model in rats

Figure 2: Excision wound healing effect of 3% w/w ointment tetracycline hydrochloride and 4mg/kg of Dexamethasone received rat on 0th (A) and 10th (B) days.

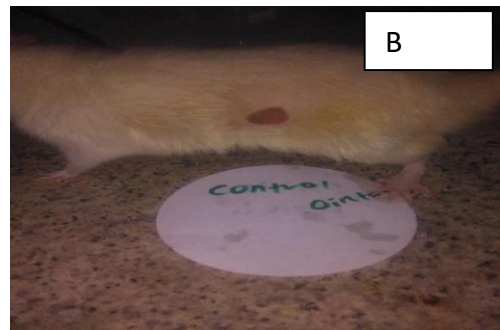
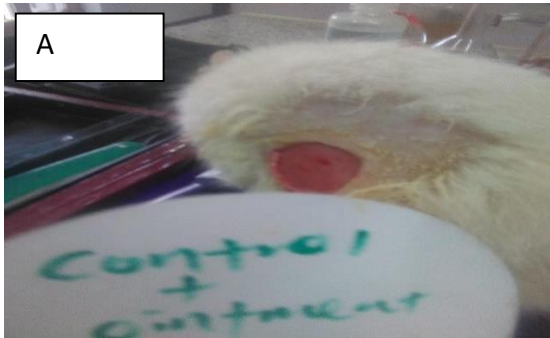

Figure 3: Excision wound healing effect of 20 % Acetone extract and 4mg/kg of Dexamethasone received rat on 0th (A) and 10th (B) days observation

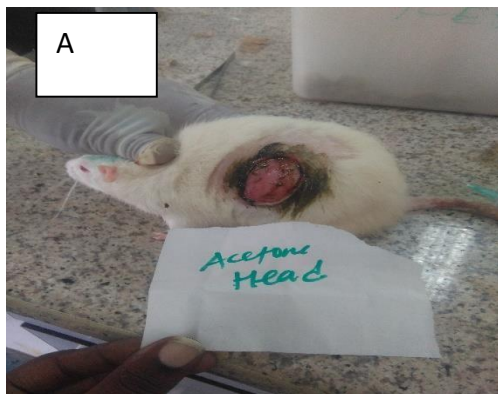

Figure 4: Excision wound healing effect of 20 % Aqueous extract and 4mg/kg of Dexamethasone received rat on 0th (A) and 10th (B) days observation





Figure 6: Excision wound healing effect of 20 %Chloroform extract and 4mg/kg of Dexamethasone received rat on 0th (A) and 10th (B) days.



The slowing/decreasing wound healing rate with diabetes associated with decrease immune function. Diabetes leads to diabetic neuropathy in which loss sensation and they cannot able to find the changes in stages of wound and diabetic people more susceptible to the infection on wound this will spared from locally to systemically cause degeneration of neighboring body structures. Finally the organ lost their normal physiology. Chloroform extracts of *Ruta graveolens* significantly reduced the blood glucose level in and helpful healing of wound in diabetic condition it may due to the active constituents may involve in collagen synthesis which will helpful in epithelial cell proliferation, and other extract of *Ruta graveolens* was helpful in decreasing the rate of blood glucose level when compared to control and tetracycline hydrochloride ointment.

CONCLUSION

On the basis of the results obtained in the present investigation, it is possible to conclude that the ointment of the chloroform extract of *Ruta graveolens* has significant diabetic induced wound healing activity. We think that the basis of this wound healing ability likely lies in *Ruta graveolens* anti-diabetic, anti-inflammatory, antioxidant and antimicrobial functions which are mostly due to its active constituents in the extract such as alkaloids, flavonoid and saponins. Further study need to elaborate

the identification and isolation of possible active compound and elucidate mechanism of active constituents responsible for the anti-diabetic and wound healing property.

REFERENCES

1. Ratheesh M and A Halen. Anti-inflammatory activity of *Ruta graveolens* L. on carrageen induced paw edema in wistar male rats. *Afr. J. Biotechnol.* 2007; 6(10): 1209-1211.
2. Patil SJ and S.B. Patil. Toxicity studies on hepatic, nephric and endocrine organs of citrus medica seeds extract on of female albino mice. *J. Glob. Pharma Technol.* 2011; 3(1): 14-21.
3. El Agraa, SEI, SMA Elbadwi, SEI Adam. Preliminary observations on experimental *Ruta graveolens* toxicosis in Nubian goats. *Trop. Anim. Health Pro.* 2002; 34(42): 271- 281.
4. Salvador AAS, AFP Maria, MAF Francisco, SF Cristina, SO Salvio. Phytophotodermatitis due to *Ruta graveolens* prescribed for fibromyalgia. *Med. Rheumatol.* 2009; 48(11): 1401.
5. Tian-Shung WS, Li-Shian W, Jhi- Joung I, Song Chou C, Hsien-Chang C, Yuh-Pan K, Yao- Haur C, Ya-Ling and T Che-Ming. Cytotoxic and antiplatelet aggregation principles of *Ruta graveolens*. *J. Chinese Chem. Soc.* 2003; 50(1): 171-178.
6. Miguel ES. Rue in traditional Spain: frequency and distribution of its medicinal and symbolic applications. *Econ Bot*, 2003; 57: 231-244.
7. Pathak S, Multani A, Banerji P, Banerji P. *Ruta* 6 selectively induces cell death in brain cancer cells but proliferation in normal peripheral blood lymphocytes: a novel treatment for human brain cancer. *Int J Oncol*, 2003; 23:975-982.
8. Preethi K, Kuttan G, Kuttan R. Anti-tumour activity of *Ruta graveolens* extract. *Asian Pac J Cancer Prev.* 2006; 7: 439-443.
9. Ahmed OM, Moneim AA, Yazid IA, Mahmoud AM. Antihyperglycemic, antihyperlipidemic and antioxidant effects and the probable mechanisms of action of *Ruta graveolens* infusion and rutin in nicotinamide-streptozocin induced diabetic rats. *Diabetol Croat*, 2010; 39: 15-35.
10. Mahmoud AM, Germoush MO, Soliman AS. *Ruta graveolens* mitigates ammonium chloride- induced hyperammonemia by modulating antioxidant status and pro-inflammatory cytokines. *Life Sci J.* 2014; 11: 269-275.
11. Conway GA, Slocumb JC. Plants used as abortifacients and emmenagogues by Spanish New Mexicans. *J Ethnopharmacol.* 1979; 1: 241-261.
12. Rajeshwari S A, Balakrishnan M, Thenmozhi, R Venckatesh. Preliminary phytochemical analysis of *Aegle marmelos*, *Ruta graveolens*, *Opuntia dellini*, *Euphorbia royleana* and *Euphorbia antiquorum*. *Int. J. Pharm. Sci. Res.* 2011; 2(1): 132-136.
13. Khare CP, (2007). *Indian Medicinal Plants: An Illustrated Dictionary.* Springer, New York, USA.
14. Inna KK, Irina, S Bernd. Specific accumulation and revised structures of acridone alkaloid glucosides in the tips of transformed root of *Ruta graveolens*. *Phytochemistry*, 2004; 65(8): 1095-1100.
15. De-Feo V, F De-Simone, F Senatore. Potential allelochemicals from the essential oil of *Ruta graveolens*. *Phytochemistry*, 2002; 61: 573-578.
16. Kokate CK (1986). In: *Practical Pharmacognosy, Preliminary Phytochemical Screening*, first ed., Vallabh Prakashan, New Delhi, 111.

17. Shalam MD, Harish MS & Farhana SA: Prevention of dexamethasone- and fructose-induced insulin resistance in rats by SH-01D, a herbal preparation. *Indian J Pharmacol* 2006; 38:419-422.
18. Werner S, Breddeden M, Hubner G, Greenhalgh D G and Longaker MT. Introduction of keratinocyte growth factor expression is reduced and delayed during wound healing in the genetically diabetic mouse. *J Investig Dermatol.*1994; 103:469
19. Sellamuthu PS, Muniappan BP, Perumal SM, Kandasamy M. Antihyperglycemic effect of mangiferin in streptozotocin induced diabetic rats. *J. Health Sci* 2009; 55:206–14.