

Molecular Study Of COVID-19 And Its Relationship To Pityriasisrosea (PR)

Dr. Ahmed Abdulhussein Kawen

Assistant professor MBChB; FICMS. Department of dermatology / College of Medicine / University of Thi-Qar, Iraq
ahmedpath@yahoo.com

Abstract:

Background: A new type of coronavirus family (SARS-CoV-2), that has been detected in individuals with several clinical symptoms named (COVID-19), was recognized as a pandemic on March 11, 2020. Numerous researches have been conducted on manifestations of skin disease related to COVID-19, i.e. rashes, pityriasisrosea (PR), vascular markings, and lesions as pimple-like.

Aim: This study aims to find out if the Coronavirus can affect (PR) development which also can be considered as a trigger and symptom for other types of infections.

Material and Methods: A case series describing the dermatological finding of COVID-19 in Thi-Qar Governorate, a collective sample taking from inpatients, outpatients, the emergency unit of Al Hussein Teaching Hospital, and inwards of Al-Shefaa' Isolation Hospital. The study has been done over a four-month period (June-September, 2020.)

Results: 19 patients (10 females and 9 males), who have infected with Coronavirus and were suffering from (PR), are included in this study. The highest percentage of females 52.6% and males 47.4%. The distribution of patients according to the incidence of (PR) in typical and anomalous manners had the percentage of typical 77.9% and abnormal 21.1%. The highest percentage was in moderate Covid-19 (84.2%), while it was 15.8% in mild Covid-19. There was no significant statistical difference in mean age distribution according to gender while there were significant statistical differences according to (PR) and COVID-19 class. More studies are needed to evaluate whether or not these lesions are associated with the virus.

Conclusion: The (PR) was one of the dermatological finding of COVID-19, that did not have a clear role in the distribution of the disease according to the background of the patients and also the severity of COVID-19. It can be triggered by COVID-19 and completely cured with the clearance of the disease.

Recommendation: An accurate robust cutaneous documentation related to Covid19 is required to increase the knowledge of disease as well as its epidemiology.

Keywords: (PR), COVID-19, PCR

Introduction:

A new type of coronavirus family (SARS-CoV-2) has been detected in individuals with several clinical symptoms. This virus was discovered in the late 2019 in China (Wuhan) and named (COVID-19). This virus has been spread throughout the whole world rapidly and was recognized as a pandemic on March 11, 2020 [1]. There are many researches about the cutaneous findings of the COVID-19 [2]. Numerous researches have been conducted on the manifestations of skin problems related to COVID-19, i.e. rashes, (PR), vascular markings or lesions as pimple-like [3]. (PR) is a papulosquamous trouble described firstly by (Robert Willan) in 1798, but under another terminology [4]. (PR) is described by a skin eruption with initial popping spots and then followed along division dermatoses lines appearing as minimal, separate, oval to round lesions of skin on collarbone area. Such lesions influence chiefly proximal and trunk sides. Spontaneous remission typically takes place during rash appearance of 6-12 weeks. (PR) is thought to associate with viral infections, particularly human herpes virus (HHV) 7 [5]. There were many names for (PR) as it was later named herpes maculosus and roseola annulet [6]. It surprises typically with huge erythematous scaly plaque evolution which is termed mother patch or herald patch on neck or trunk, then followed multiple secondary tiny erythematous scaly lesions rash predominantly located on the trunk and following split lines on back [7]. Since Corona Virus is closely related to (PR), we can predict the infection in the beginning, as it is considered an early diagnostic sign. However, there is no evidence that the Corona virus is the cause of (PR) due to different types of rashes that appeared on the infected area [8]. It is very common. The incidence filed from 0.39 to 4.8 per 100 dermatology patient [5]. The etiology of (PR) is unknown; lesion histopathological alterations are nonspecific for (PR). They contain focal spongiosis caps, vascular dilation, infiltrates as perivascular lymphocytic and parakeratosis as patchy. These cytological changes are close to viral infections i.e., varicella zoster and herpes simplex [9]. The goal of the current work is to observe if Coronavirus is a risky factor in (PR) development where it might be considered as a trigger for other types of infection, including (PR). It can be considered a symptom of infection with the virus

Material and Methods:

A case series describing the dermatological finding of COVID-19 in Thi-Qar Governorate, collective samples in this study were gathered from inpatients, outpatients, emergency units of Al Hussein Teaching Hospital, and inwards of Al-Shefaa' Isolation Hospital; The study has been done over a four-month period (June-September, 2020.), in which a total number of 19 patients, 10 females and 9 males, is included. All cases were proved to have COVID-19 by positive post nasal or pharyngeal swab for PCR technique. A verbal consent was taken from each patient with a full description of the aim and benefit of

the study. A skin lesion was firstly identified by a dermatologist: skin scraps were taken from the lesion of those who were infected with Covid-19 and diagnosed with histo-pathological changes. Even though they were nonspecific for (PR), they were highly suggestive. Most of the lesions contain focal spongiosis caps, vascular dilation, infiltrates as perivascular lymphocytic and parakeratosis as patchy. Samples were classified by internist into mild, moderate and sever cases of COVID-19 according to WHO criteria, and they were also categorized as typical and atypical according to (PR). Statistical analysis was done by using SPSS version. There were 26 describing cases according to their presentation regarding their mean age, gender, severity of COVID-19 and subtypes of (PR). ANOVA and Fischer Exact Tests had been used for cross-tabling to study the association of the variables of interest, P value <0.05 was of great significance.

Results:

Nineteen patients in total (10 females, 9 males), who were infected with Coronavirus and were suffering from (PR), were included in this study in which the highest percentage of females was 52.6% and males 47.4%.

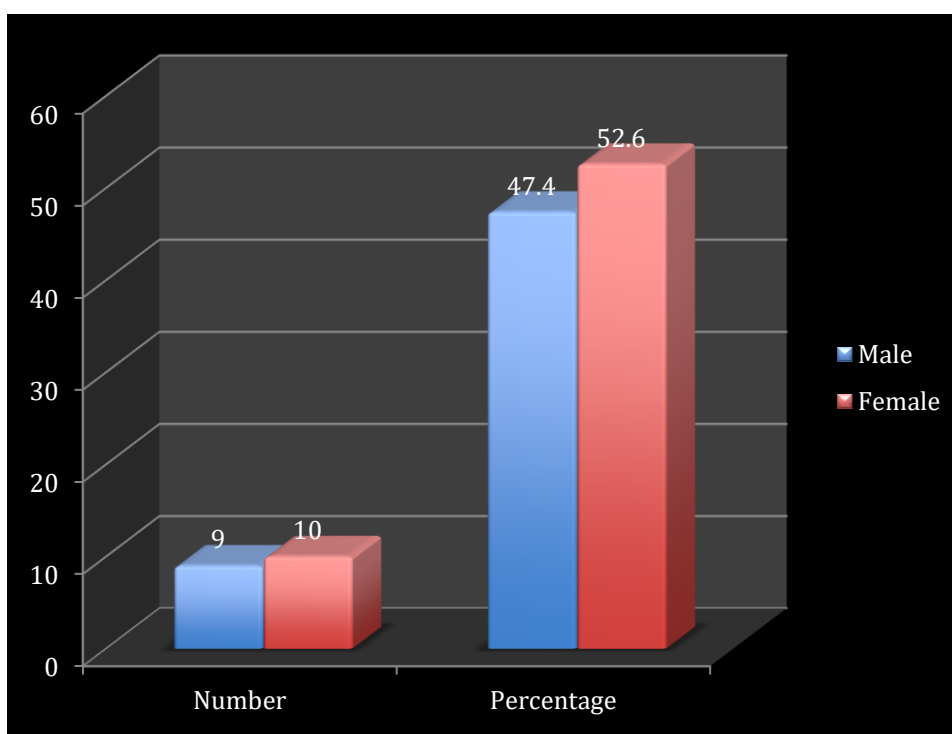


Figure one: Distribution according to gender

Figure two demonstrates the distribution of patients according to the incidence of (PR) in typical and anomalous manner. The highest percentage was 77.9% for typical and 21.1% for abnormal.

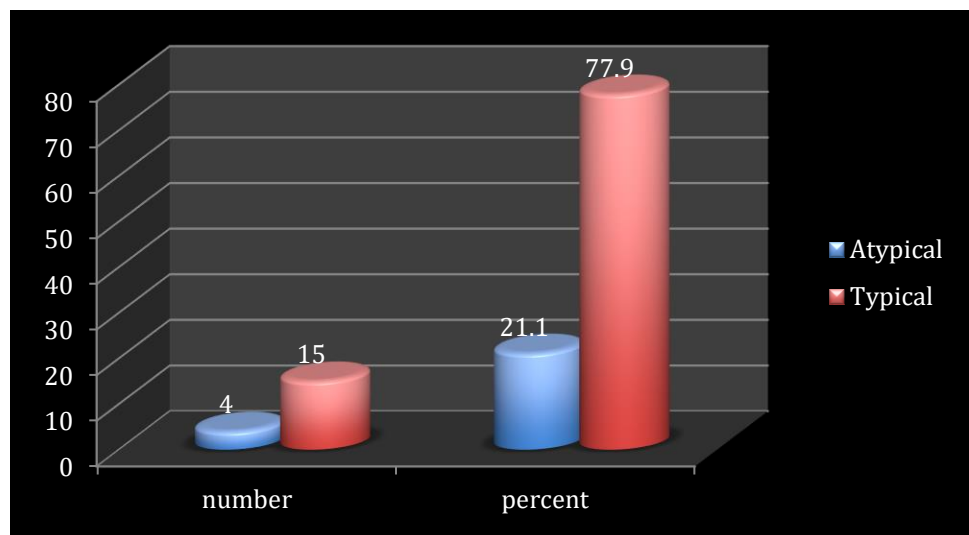


Figure two: Distribution according to (PR) subtypes

The distribution of infected people was observed according to the COVID-19 sub-category. the highest percentage was in moderate COVID-19 (84.2%) while in mild COVID-19 it was (15.8%) .

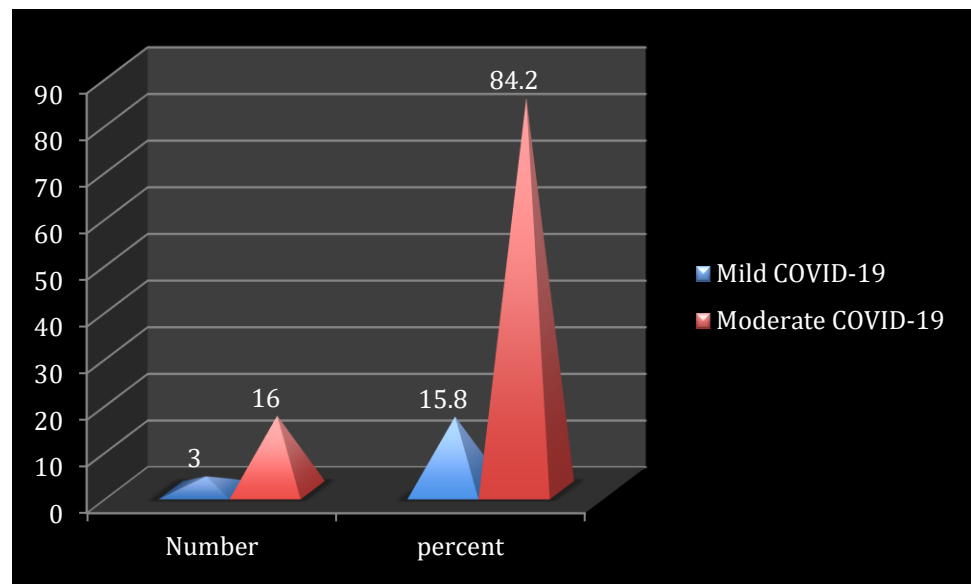


Figure three: Distribution according to COVID-19 sub-category

Table 1 refers to the Mean age distribution according to gender in which there is no significant statistical difference while big statistical differences can be seen in P.Rosea and COVID-19 categories.

Table 1: Mean age distribution according to gender, skin lesion and severity of COVID-19

Variables of interest	Mean	Std. Deviation	ANOVA, p value, Eta
Sex			.547
Male	26.2222	4.54911	.470
Female	28.0000	5.77350	.177
P.Rosea			
Typical	28.1333	5.26263	2.792,0.113
Atypical	23.5000	2.88675	.376
COVID-19 severity			
Mild	27.0000	5.60952	.090, 0.768
Moderate	28.0000	1.73205	0.073
Total	27.1579	5.16681	

Table2: The distribution of patients with (PR) according to their gender and the severity of COVID-19

		Sex	COVID		Total	Fischer Exact	
			Mild	Moderate		P	
Male	P.R	Typical	No.	5	2	7	.735 ^e .583
		%	71.4%	28.6%	100.0%		
	Atypical	No.	2	0	2		
		%	100.0%	0.0%	100.0%		
	Total	No.	7	2	9		
		%	77.8%	22.2%	100.0%		
Female	P.R	Typical	No.	8	0	8	4.444 .200
		%	100.0%	0.0%	100.0%		
	Atypical	No.	1	1	2		
		%	50.0%	50.0%	100.0%		
	Total	No.	9	1	10		

		%	90%	10.0%	100.0%	
Total	P.R	Typical	No.	13	2	15
			%	86.7%	13.3%	100.0%
		Atypical	No.	3	1	4
			%	75.0%	25.0%	100.0%
	Total		No.	16	3	19
			%	84.2%	15.8%	100.0%

There are no significant statistical differences in the gender distribution for the subtypes of COVID-19 according to pit. Rosea subclass.

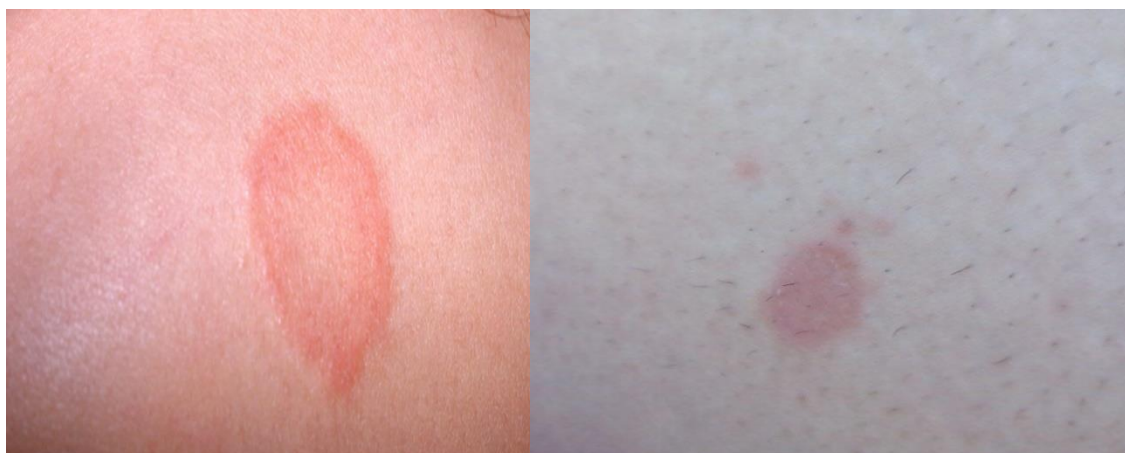

Figure 4: Different presentations (PR)

Discussion:

Coronavirus disease has had several influences on dermatology practiced routinely [10].It is obvious that we would witness development in this field and more accurate data would be collected about the relation between dermatology and COVID-19 in the coming days.Cutaneous symptoms might be classified under 5 chief groups: livedo and necrosis , lesions as urticarial, eruption being maculopapular, pseudo-chilblain, rash as vesicular [2].At the moment, the skin diseases which accompany people with Coronavirus remain as unresolved mystery.In the current research, it was observed that the average PR patients, who have applied to outpatient dermatology clinic through the period of pandemic, augmented more times in the current year compared with last year at the same time.(PR) has been highly linked with people with Herpesvirus 6 and 7reactivation while other etiology such as viral, stress being psychological, vaccination, and drugs were involved as the reaction cause [11].In many sources, it may be one of the factors leading

to herpes viruses activation in which Corona viruses can be the cause of (PR). Or perhaps another cause of stress and psychological pressure caused by the period of the epidemic[12]. In the previous study, it was shown that the rashes and skin diseases, associated with those who were infected with Corona virus, differed dramatically according to the geographical location[13]. In the previous research conducted by Enguix et.al, 2020, when people with (PR) performed a Corona virus test using PCR, a positive result was obtained which is consistent with the current study. The coronavirus disease influences systems of multiple organ to pro-inflammatory chemokines and cytokines uncontrolled release, causing in manifestation clinically excluding symptoms of respiratory system [15]. This is the first study in Thi-Qar, Iraq that shows (PR) throughout the period of pandemic. We believe that such elevation is associated with HHV-6 reactivation. It is possible that (PR) is a symptom of the Coronavirus. Coronavirus disease still remains as an unresolved mystery, however there are numerous publishing articles about the clinical symptoms and side effects. More studies are needed based on antibody Polymerase and PCR which should be implemented to search if specific dermatologic diseases are connected to cases of asymptomatic Covid-19 [16]. There aren't adequate studies so far in order to enable clinicians to recognize definite patterns of skin problems relating to Covid-19. Therefore, it is important to state these cases in order to increase the knowledge regarding such symptoms, particularly because they can be the only infection signs and confused with other viral infection and skin diseases. We also presume the importance of distinguishing between different mechanisms like physiological and temporal patterns ; i.e. to underrated of whether there is a viral relationship of synergistic or symbiotic with other processes such as erythema, infection, herpes zoster and other skin diseases. Moreover, we highlight the importance of screening the precarious skin diseases in patients infected with Covid-19. More studies are needed to evaluate whether or not these lesions are associated with the virus. More accurate cutaneous manifestation of Covid-19 is required to increase presentation of these diseases as well as epidemiological knowledge. In the previous study conducted by Haha, it has been shown that being infected with (PR) have no relationship to people with Coronavirus. It is imperative for all healthcare professionals to be well-versed in such elevated manifestations of COVID-19. Surgeons should be also aware of such lesions, as they appear on feet, hands, and torso so often. Further COVID-19 standardized studies of rash are warranted for additional valid diagnosis and such visible endings utility [17]. (PR) infection increased during the COVID-19 outbreaks. This increase may be related to intense stress during the pandemic period or as a marker in COVID-19 patients. It is possible that altered immunity during the COVID-19 pandemic increased the frequency of (PR) infection. Moreover, we should keep in mind that (PR) infection may be accompanied by COVID-19. One limitation of the current work was the incapability for collecting standardized and

complete sets of data to permit comparisons in-depth among subgroups of rash. In a previous study conducted by Català et al., (2020), it showed that the infection with (PR) was related to the Coronavirus, as the percentage of patients reached 30%. In conclusion, a description of (PR) related to COVID-19 might help doctors approaching patients who have such disease and recognizing cases of little symptoms. Ehsaniet al reported (PR) in a patient with COVID-19. A scaly annular rash over arms and trunk was observed in the twenty-seven-year-old man. The lesions were pruritic and spread over five days[19]. Mawhirt, et al. 2020 confirmed that there is no relationship between COVID-19 and skin infections such as (PR). The reason of the appearance of (PR) spots might be just the activation of a specific virus relating to retrospective work. We did not have information about the individual's quality of life, levels of anxiety, their treatments, and the risk of COVID-19. The current work is trying to understand the reason why patients with minor dermatological diseases visit hospitals while a worldwide fatal pandemic is occurring at the same time[21]. The rash of (PR) may be a direct result of virus-organ interaction or the result of an immune system activation [22]. It is necessary to emphasize such patterns for clinical diagnosis. Furthermore, we suggest that researches should be enriched by conducting extra COVID-19 tests for diagnoses, as well as describing some collected markers and the clinical link between them[23-38]

Conclusion:

The (PR) is one of dermatological finding related to COVID-19 that doesn't have a clear role in its distribution according to the biography of the patient. It has not distributed significantly according to the severity of COVID-19. It might be triggered by COVID-19 and be completely cured with the clearance of disease

Recommendation: More accurate cutaneous documentation of Covid-19 is required to increase presentation of these diseases as well as epidemiological knowledge.

References:

- [1] W. Guan et al., "Clinical Characteristics of Coronavirus Disease 2019 in China," *new engl J. Med.* Orig., vol. 7, no. 12, pp. 1708–1720, 2020.
- [2] C. G. Casas et al., "Classification of the cutaneous manifestations of COVID-19: a rapid prospective nationwide consensus study in Spain with 375 cases," *Br. J. Dermatol.*, vol. 183, no. 6, pp. 71–77, 2020.

- [3] I. Torres-Navarro, C. Abril-Perez, J. Roca-Gines, J. Sanchez-Arreaez, and R. Botella-Estrada, "Erythema multiforme and Kawasaki disease associated with COVID-19 infection in children," *Eur. Acad. Dermatology Venereol.*, vol. 34, no. 6, pp. 539–541, 2020.
- [4] K. Mahajan, V. Relhan, A. K. Relhan, and V. K. Garg, "(PR) : An Update on Etiopathogenesis and Management of Difficult Aspects," *Indian J. Dermatol.*, vol. 61, no. 4, pp. 375–384, 2016.
- [5] A. A. T. Chuh and V. Zawar, "(PR) ," *Harper's Textb. Pediatr. Dermatology*, vol. 34, no. 6, pp. 416–421, 2020.
- [6] V. Zawar, H. Jerajani, and R. Pol, "Current trends in (PR) ," *Expert Rev. Dermatol*, vol. 5, no. 3, pp. 325–333, 2010.
- [7] R. Balestri, G. Rech, and C. R. Girardelli, "(PR) as a cutaneous manifestation of COVID-19 infection," *Eur. Acad. Dermatology Venereol.*, vol. 34, no. 7, pp. 436–437, 2020.
- [8] U. Wollina, A. S. Karada!, and C. Rowland-Payne, "Cutaneous signs in COVID-19 patients : A review," *Dermatol. Ther.*, vol. 6, no. 5, pp. 1–6, 2020.
- [9] G. Stinco, M. Ruscio, D. Proscia, and F. Piccirillo, "Borrelia Infection and (PR) ," *Acta Derm Venereol*, vol. 89, no. 6, pp. 97–98, 2008.
- [10] S. A. Temiz et al., "Evaluation Of DermatologyConsultationsInTheEra Of COVID19," *Orig. Artic.*, vol. 6, no. 7, pp. 1–10, 2020.
- [11] M. YUKSEL, "(PR) Recurrence is Much Higher than Previously Known :A Prospective Study," *Investig. Rep.*, vol. 99, no. 9, pp. 664–667, 2019.
- [12] S. T. S. Hassan, "Shedding Light on the Effect of Natural Anti-Herpessvirus Alkaloids on SARS-CoV-2: A Treatment Option for COVID-19," *Viruses 2020*, vol. 476, no. 12, pp. 12–15, 2020.
- [13] C. S. Gonçalves et al., "Erythematous Papular Rash: A Dermatological Feature of COVID-19 Catarina," *Eur. J. Case Reports Intern. Med.*, vol. 5, no. 5, pp. 56–58, 2020.
- [14] D. M. Enguix, M. del C. S. Nieves, and D. T. M. Romeroc, "(PR) Gibert type rash in an asymptomatic patient that tested positive for COVID-19," vol. 155, no. 6, p. 273, 2020.
- [15] P. Suchonwanit, "Diagnostic and prognostic values of cutaneous manifestations in COVID-19,"

Dermatologic Therapy, no. 5. pp. 10–11, 2020.

- [16] Ö. Kutlu and A. Metin, "Relative changes in the pattern of diseases presenting in dermatology outpatient clinic in the era of the COVID-19 pandemic," *Dermatol. Ther.*, vol. 8, no. 7, pp. 1–5, 2020.
- [17] G. Daneshgaran, D. P. Dubin, and D. J. Gould, "Cutaneous Manifestations of COVID - 19 : An Evidence - Based Review," *Am. J. Clin. Dermatol.*, vol. 21, no. 5, pp. 627–639, 2020.
- [18] A. Català et al., "Maculopapular eruptions associated to COVID-19 : A subanalysis of the COVID-Piel study," *Dermatologic Ther.*, vol. 26, no. 6, pp. 1–10, 2020.
- [19] S. Shaukat, G. Butt, and I. Hussain, "Cutaneous manifestations of COVID-19," *J. Pakistan Assoc. Dermatologists*, vol. 30, no. 1, pp. 181–189, 2020.
- [20] S. L. Mawhirt, D. Frankel, and A. M. Diaz, "Cutaneous Manifestations in Adult Patients with COVID-19 and Dermatologic Conditions Related to the COVID-19 Pandemic in Health Care Workers," *Curr. Allergy Asthma Rep.*, vol. 12, no. 10, pp. 1–13, 2020.
- [21] Ç. Turan, N. Metin, Ö. S. Kotan, UtumZeynep, and Ö. Ümran, "Change of the diagnostic distribution in applicants to dermatology after COVID-19 pandemic : What it whispers to us ?," *Dermatol. Ther.*, vol. 4, no. 6, pp. 1–9, 2020.
- [22] D. Lipsker, "Paraviral eruptions in the era of COVID-19 : Do some skin manifestations point to a natural resistance to SARS-CoV-2 ?," *Clin. Dermatol.*, vol. 6, no. 7, pp. 1–5, 2020.
- [23] Saleh, M. M., Jalil, A. T., Abdulkereem, R. A., & Suleiman, A. A. Evaluation of Immunoglobulins, CD4/CD8 T Lymphocyte Ratio and Interleukin-6 in COVID-19 Patients. *TURKISH JOURNAL of IMMUNOLOGY*, 8(3), 129-134.
- [24] Moghadasi, S., Elveny, M., Rahman, H.S. et al. A paradigm shift in cell-free approach: the emerging role of MSCs-derived exosomes in regenerative medicine. *J Transl Med* **19**, 302 (2021). <https://doi.org/10.1186/s12967-021-02980-6>
- [25] JALIL, A. T., DILFY, S. H., KAREVSKIY, A., & NAJAH, N. (2020). Viral Hepatitis in Dhi-Qar Province: Demographics and Hematological Characteristics of Patients. *International Journal of Pharmaceutical Research*, 12(1).

- [26] Dilfy, S. H., Hanawi, M. J., Al-bideri, A. W., & Jalil, A. T. (2020). Determination of Chemical Composition of Cultivated Mushrooms in Iraq with Spectrophotometrically and High Performance Liquid Chromatographic. *Journal of Green Engineering*, 10, 6200-6216.
- [27] Jalil, A. T., Al-Khafaji, A. H. D., Karevskiy, A., Dilfy, S. H., & Hanan, Z. K. (2021). Polymerase chain reaction technique for molecular detection of HPV16 infections among women with cervical cancer in Dhi-Qar Province. *Materials Today: Proceedings*.
- [28] Marofi, F., F. Abdul-Rasheed, O., Sulaiman Rahman, H., Setia Budi, H., Jalil, A. T., Valerievich Yumashev, A., ... & Jarahian, M. (2021). CAR-NK cell in cancer immunotherapy; A promising frontier. *Cancer Science*.
- [29] Widjaja, G., Jalil, A. T., Rahman, H. S., Abdelbasset, W. K., Bokov, D. O., Suksatan, W., ... & Ahmadi, M. (2021). Humoral Immune mechanisms involved in protective and pathological immunity during COVID-19. *Human Immunology*.
- [30] Jalil, A.T., Kadhum, W.R., Faryad Khan , M.U. et al. Cancer stages and demographical study of HPV16 in gene L2 isolated from cervical cancer in Dhi-Qar province, Iraq. *Appl Nanosci* (2021). <https://doi.org/10.1007/s13204-021-01947-9>
- [31] Sarjito, I., Elveny, M., Jalil, A. T., Davarpanah, A., Alfakeer, M., Bahajjaj, A. A. A., & Ouladsmene, M. (2021). CFD-based simulation to reduce greenhouse gas emissions from industrial plants. *International Journal of Chemical Reactor Engineering*.
- [32] Turki Jalil, A., Hussain Dilfy, S., Oudah Meza, S., Aravindhan, S., M Kadhim, M., & M Aljeboree, A. (2021). CuO/ZrO₂ Nanocomposites: Facile Synthesis, Characterization and Photocatalytic Degradation of Tetracycline Antibiotic. *Journal of Nanostructures*.
- [33] Hanan, Z. K., Saleh, M. B., Mezal, E. H., & Jalil, A. T. (2021). Detection of human genetic variation in VAC14 gene by ARMA-PCR technique and relation with typhoid fever infection in patients with gallbladder diseases in Thi-Qar province/Iraq. *Materials Today: Proceedings*.
- [34] Vakili-Samiani, S., Jalil, A. T., Abdelbasset, W. K., Yumashev, A. V., Karpisheh, V., Jalali, P., ... & Jadidi-Niaragh, F. (2021). Targeting Wee1 kinase as a therapeutic approach in Hematological Malignancies. *DNA Repair*, 103203.

- [35] NGAFWAN, N., RASYID, H., ABOOD, E. S., ABDELBASSET, W. K., AL-SHAWI, S. G., BOKOV, D., & JALIL, A. T. (2021). Study on novel fluorescent carbon nanomaterials in food analysis. Food Science and Technology.
- [36] Marofi, F., Rahman, H. S., Al-Obaidi, Z. M. J., Jalil, A. T., Abdelbasset, W. K., Suksatan, W., ... & Jarahian, M. (2021). Novel CAR T therapy is a ray of hope in the treatment of seriously ill AML patients. Stem Cell Research & Therapy, 12(1), 1-23.
- [37] Jalil, A. T., Shanshool, M. T. ., Dily, S. H. ., Saleh, M. M., & Suleiman, A. A. . (2021). HEMATOLOGICAL AND SEROLOGICAL PARAMETERS FOR DETECTION OF COVID-19. Journal of Microbiology, Biotechnology and Food Sciences, e4229. <https://doi.org/10.15414/jmbfs.4229>
- [38] Abosaooda, M., Majid, W. J., Hussein, E. A., Jalil, A. T., Kadhim, M. M., Abdullah, M. M., ... & Almashhadani, H. A. (2021). Role of vitamin C in the protection of the gum and implants in the human body: theoretical and experimental studies. Int. J. Corros. Scale Inhib, 10(3), 1213-1229.